

Abstracts from the 46th Annual Conference of the European Prosthodontic Association (EPA) 14th - 16th September 2023 Vilnius, Lithuania

Oral Presentations

Poor Oral Health Among Edentulous Patients After Severe SARS-CoV-2 Infection Undergoing Non-Invasive Mechanical Ventilation

.....
Justyna Otulakowska-Skrzynska^{*1}, Elzbieta Paszynska¹, Maria Gawriolek¹, Amadeusz Hernik¹, Magdalena Roszak³, Szczepan Cofta²

(¹Department of Integrated Dentistry, Poznan University of Medical Sciences (PUMS), Poznan 60-812, Poland; paszynska@ump.edu.pl (E.P.); amadeusz.hernik@gmail.com (A.H.); mgawriolek@gmail.com (M.G.); justynao@ump.edu.pl (J.O.-S.); ²Department of Pulmonology, Allergology and Respiratory Oncology, Poznan University of Medical Sciences (PUMS), Szamarzewskiego 82/84, 60-569 Poznan, Poland; scofta@ump.edu.pl (S.C.); winiarskahanna@gmail.com (H.W.); daria.springer.pl@gmail.com (D.S.); ³Department of Computer Science and Statistics, Poznan University of Medical Sciences (PUMS), 60-806 Poznan, Poland; mmr@ump.edu.pl (M.R.))

***Corresponding author: Justyna Otulakowska-Skrzynska, Department of Integrated Dentistry, Poznan University of Medical Sciences (PUMS), Bukowska St. 70, Poznan 60-812, Poland; justynao@ump.edu.pl**

Objectives: The impact of the pandemics on the oral health of the edentulous elderly is still unknown. Understanding the cause-and-effect relationships may allow individualized adjustment of oral care recommendations during Covid-19 disease. The study's objective was to compare oral health during hospital treatment due to adverse Covid-19 among edentulism and dentate patients.

Material and Methods: One-hundred and twenty patients (mean age 74.4±15.4; male n=50/female n=70) were examined in the acute phase of Covid-19 during hospital treatment. The condition of oral mucosa (BRUSHED and Beck scores), blood biochemical parameters (D-dimer, C-reactive protein CRP, lymphocyte, interleukine-6 IL-6) and clinical status (respiratory failure as pneumonia and Covid-19 symptoms severity) were compared between dentate and edentulous patients. All results were considered significant at $p < 0.05$.

Results: All patients presented characteristics of the dental plaque retention (83.4%), xerostomia (74.2%), oral mucosa inflammation (80.8%), angular cheilitis (53.3%), hemorrhage

(21.7%) with a higher incidence of harmful oral conditions among edentulous patients. This group had also higher BRUSHED and Beck scores indicating a need for oral care every 8 hours. Multiple regression selected the following risk predictors for pneumonia as IL-6, CRP, PCR index and Beck score ($p < 0.001$). Patients who received oxygen therapy with face masks had more often angular cheilitis and debris ($p = 0.025$, $p = 0.035$).

Conclusions: COVID-19 hospitalised patients with severe symptoms crossing with poor oral health-related conditions, particularly among edentulous patients. For Covid-19 management, in order to inhibit extra- and intra-oral complications, it is recommended to adjust oral hygiene procedures, including antibacterial, protective, moisturising agents after professional oral health examination.

Keywords: edentulous, prosthetic condition, oral health, Covid-19, hospitalisation

Effect of Different Bite Registration Strategies for Edentulous Arch

Justinas Pletkus¹, Vygandas Rutkūnas², Agnė Gedrimienė³, Liudas Auškalnis⁴, Mykolas Akulauskas⁵

¹Assistant Professor, PhD student, Institute of Odontology, Faculty of Medicine, Vilnius University, Vilnius, Lithuania; ²Professor, PhD, Institute of Odontology, Faculty of Medicine, Vilnius University, Vilnius, Lithuania; ³Assistant Professor, PhD, Institute of Odontology, Faculty of Medicine, Vilnius University, Vilnius, Lithuania; ⁴PhD student, Institute of Odontology, Faculty of Medicine, Vilnius University, Vilnius, Lithuania; ⁵Researcher, Biomedical Engineering Institute, Kaunas University of Technology, Lithuania)

Objectives: The objective of this study is to compare, in vitro, bite registration accuracy between three different methods using IOS.

Materials and Methods: Maxillary edentulous and mandible dentate models were printed using the Asiga Max UV (Asiga, Sydney, Australia) 3D printer. Four Straumann BLT RC 4.1 mm diameter (Straumann, Switzerland) dental implants were placed in the maxilla model. Scanbodies were attached to the implants. Metrological spheres were attached to both models. Reference scans were obtained using a Nikon Altera (Nikon Metrology, Shinagawa, Japan). Digital impressions were taken with Trios 4 (3Shape, Denmark) intraoral scanner ten times for each model. Additionally, three types of digital bite records were taken for each pair of scans (Figures 1-3): The first group of registration was done by acquiring bite scan between buccal aspects of models from one left to right with scanbodies fixed to the upper model (WSB). For the second group, the same protocol for bite registration was applied with the addition of putty silicone

(Variotime Easy putty, Kulzer GmbH, Germany) index between two models (WSB silicone). The third group was done according to pre-preparation scanning protocol (Pre-PREP): digital impression was acquired of a prefabricated maxillary removable denture, then the antagonist. Conventional bite registration was acquired. Finally, the denture was cut out of the maxillary scan and rescanned with scanbodies attached to implants. Distances between corresponding spheres were calculated as a way to represent interarch distances. Trueness and precision were calculated for all the parameters measured, and a comparison was made between different bite registration groups.

Results: There were significant differences among the groups three (pre-prep)-two (WSB silicone) and three (pre-prep)-one (WSB) on trueness. Pre-preparation method was more inaccurate than the other two. (Figure 4)

Conclusions: In this, in vitro, study pre-preparation registration technique was less accurate than using scanbodies with or without silicone index for maxillomandibular relation registration.

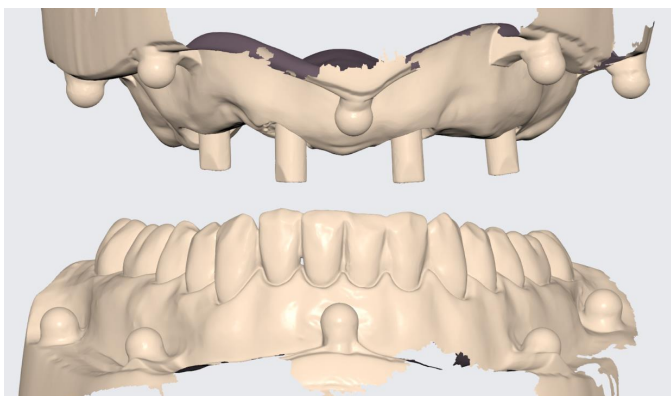


Figure 1. Group one. Bite registration with scanbodies attached.

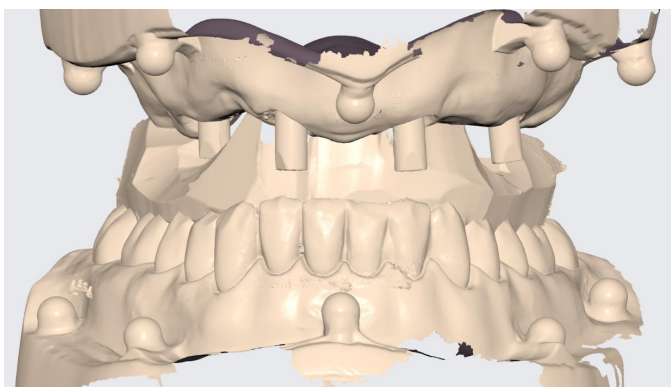


Figure 2. Group two. Bite registration with scanbodies attached plus using silicone index.

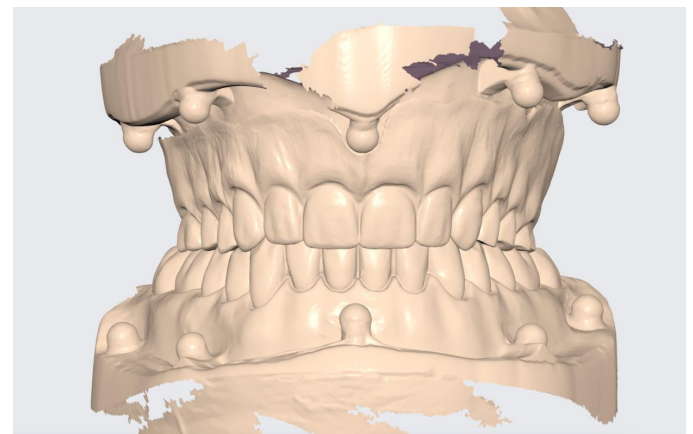


Figure 3. Group three. Bite registration using Pre-preparation technique.

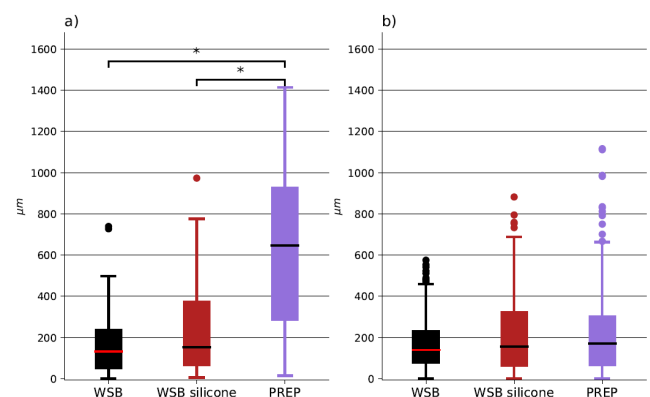


Figure 4. Trueness (a) and precision (b) data. Asterix and lines connecting the data imply a significant difference ($p<0.05$) between them.

Clinical and Patient-Reported Outcome Measures in Patients with Full-Mouth Rehabilitation Applying Minimally Invasive Glass-Ceramic Restorations

Jenni Hjerppe

(Resident Physician, Clinic of Reconstructive Dentistry, Center of Dental Medicine, University of Zurich, Plattenstrasse 11, CH-8032 Zürich, Switzerland)

Objectives: The aim of this study was to evaluate the survival rate, technical and biological complications, and patient-reported outcome measures (PROMs) of full mouth rehabilitation with minimally invasive glass-ceramic restorations after a minimum of 1.5 years of clinical service.

Materials and methods: 20 individuals (12 females, 8 males) had received full mouth tooth-supported with minimally invasive glass-ceramic restorations during the years 2009 – 2017 and participated to the follow-up visit. Full dental and periodontal examination was completed, and all the restorations were evaluated according to United States Public Health Service (USPHS) criteria. Kaplan-Meier was used for analysis of the survival time.

Results: Study participants had 439 minimally invasive restorations made from lithium disilicate reinforced glass-ceramic (79.7%), feldspathic porcelain (17.5%) and leucite reinforced glass-ceramic (2.7%). The restoration design included overlays (35.3%), full-contour restorations (31.2%), veneers (27.8%), tabletops (4.6%) and inlays (1.1%). The mean follow-up time from insertion to the examination visit was 4.5 years (1.5–12.4). Five patients lost altogether 13 restorations during

the follow-up time. The resulting estimated cumulative Kaplan-Meier 5-year survival rates were 96.6% on restoration level and 86.4% on patient level. The most common complications on restoration level were of technical nature and included marginal discoloration (11.4%) and occlusal wear (14.1%). Larger chippings were seen in 1.1% (n=5) of the restorations. Biological complications (on restoration level) were not common (4.3%). Relatively high amounts (50.4%) of bleeding on probing was seen, which was not associated to the amount of plaque (17.4%). According to the PROMs questionnaire, the patients were very satisfied with esthetics (VAS 9.5) and function (VAS 9.3) of the restorations. Women rated their oral health situation significantly better than men (p=0.03).

Conclusions: Minimally invasive full-mouth rehabilitation with glass-ceramic restorations seem to be a predictable treatment option with high survival rates, few complications and high level of patient satisfaction.

Keywords: minimally invasive, glass-ceramics, full mouth rehabilitation, survival, complications, PROMs

Conflicts of interests: The authors declare no conflicts of interest.

Volumetric Analysis of Peri-Implant Tissue Change 5 Years After Single Implant Placement in the Aesthetic Zone. Validating an Innovative 3D Method

Maria Ligoutsikou, Dr. Med. Dent., Philippe Mojon, Dr. Med. Dent.,¹ Hyeonjong Lee, Dr. Med. Dent., Ph.d.,² Nishant Yadev, Dr. Med. Dent.,³ Colin Campbell, Dr. Med. Dent.,³ Irena Sailer, Prof. Dr. Med. Dent.¹

(¹Division of Fixed Prosthodontics and Biomaterials, University Clinics for Dental Medicine, University of Geneva, Switzerland; ²Life Sciences Institute, School of Dentistry, Pusan National University, Yangsan, South Korea; ³The Campbell Clinic, Nottingham, UK)

Background: The evaluation of volumetric stability of peri-implant tissue is becoming more and more important in implant therapy because it is invaluable for assessing the long-term success of interventions. In the literature, many different methods have been proposed for evaluating tissue changes over time following different implant and tissue regeneration procedures. Technological progress offers new 3-dimensional methods for visualising and evaluating volumetric changes based on optical scans.

Aim: The aim of this study was to validate an innovative 3D volumetric method proposed by Lee *et al.*, 2020, for evaluating tissue changes, by comparing the results of this method in which the scanned peri-implant surfaces were transformed and analysed as 3D objects, with the results reported by an existing method based on the calculation of the mean distance between measured surfaces. The null hypothesis was that the two methods provide equivalent results. Additionally, the present study evaluated peri-implant tissue changes 5 years after single implant placement in the aesthetic zone.

Materials and Methods: Both methods were applied to 11 oral casts taken from 11 patients at crown placement at the implant

site (6 upper central implant sites, 5 upper lateral sites) and at follow-up examinations 5 years later. The methods are based on digital workflows in which the master and 5-year follow-up dental casts are scanned and the resulting STL (Standard Tessellation Language) files superimposed for three regions of interest (mesial papilla, central area, distal papilla). The volumetric changes reported by the 3D method of Lee *et al.* and mean distance method were calculated and compared using the Spearman Rho correlation coefficient (significance level $p < 0.01$) and the Wilcoxon signed-rank test (significance level $p < 0.05$). The correlation between the two sets of measurements was very high (Spearman Rho correlation coefficient = 0.885). The new volumetric method indicated a mean volume loss of 2.82mm^3 (SD: 5.06), while the method based on the measurement of mean distance showed a mean volume loss of 2.92mm^3 (SD: 4.43, Wilcoxon signed-rank test result: $p = 0.77$).

Results: No statistically significant difference was found. The two methods gave equivalent results, and the null hypothesis was not rejected.

Conclusion: The new volumetric method was validated and can be considered a valuable and trustworthy tool.

The Effect of General Bone Mineral Density and Age on Dental Implant Placement

Emilija Emija Esenvalde¹, Baiba Springe², Evija Nikitina², Anda Slaidina²

(¹Faculty of Dentistry, Riga Stradins University, Riga, Latvia; ²Department of Prosthodontics, Riga Stradins University, Riga, Latvia)

Keywords: Osteoporosis, Dental Implants, Bone Density, Edentulous, Residual Ridge Resorption

Objective: To investigate the potential impact of age and general bone mineral density (BMD) on the feasibility of dental implant placement in postmenopausal women with edentulous jaws.

Materials and methods: The study enrolled a total of 128 postmenopausal females with edentulous jaws, aged 52 to 91 years (mean age 70.39 ± 8.85) who sought dental implant treatment. DXA (Lunar DXA DPX-NT) was used to measure BMD in the lumbar spine and hips and the lowest T-score from both readings was considered. Cone beam computed tomography (CBCT) was conducted using the i-CAT system (Kavo eXam Vision) and analysed with OnDemand3D software. Multiple cross-sectional images were obtained from CBCT: maxilla (central incisors, canines, first premolars, first molars) and mandible (lateral incisors, first premolars, first molars). Bone height and width were determined on these images to determine the ability to place dental implants. To detect

differences between groups One-way ANOVA and Pearson's chi-squared test were used.

Results: Based on the DXA results, the patients were divided into 3 groups: normal BMD ($n=42$, mean age 69.45 ± 9.13), osteopenia ($n=56$, mean age 70.09 ± 8.96), and osteoporosis ($n=30$, mean age 72.27 ± 8.27) ($p=0.527$). No statistically significant differences were observed between the different BMD groups regarding the possibility of implant placement and general bone mineral density and across all areas of both jaws ($p > 0.05$). Women with osteoporosis were able to place fewer implants on average than women with normal BMD, but the difference between groups was not statistically significant ($p > 0.05$). Also, female age was not statistically significantly associated with the possibility of dental implant placement, except for the maxillary left central incisor region ($p = 0.007$).

Conclusions: The general BMD and age does not affect implant placement feasibility in postmenopausal women with edentulous jaws.

Trueness of Occlusion in Dental Models: An *In Vitro* Assessment of Digital and Analog Workflows

Liudas Auškalnis^{a*}, Mykolas Akulauskas^b, Aistė Gintautė^c, Cecilie Osnes^d, Andrew Keeling^e, Vygandas Rutkūnas^f

^(a)PhD student, Institute of Odontology, Faculty of Medicine, Vilnius University, Vilnius, Lithuania; ^(b)PhD student, Biomedical Engineering Institute, Kaunas University of Technology, Kaunas, Lithuania; ^(c)Dr. med. Dent., Clinic for Reconstructive Dentistry, The University Center for Dental Medicine Basel, Basel, Switzerland; ^(d)Research Assistant, School of Dentistry, University of Leeds, Leeds, England; ^(e)Clinical Associate Professor, School of Dentistry, University of Leeds, Leeds, England; ^(f)Professor, DDS, PhD, DipProsth, Institute of Odontology, Faculty of Medicine, Vilnius University, Vilnius, Lithuania; *liudas.auskalnis@gmail.com, +37065788114)

Objectives: This study aims to evaluate the trueness of occlusion, focusing on error propagation from intraoral scanning (IOS) to additive manufacturing (AM, or 3D printing).

Materials and methods: Custom reference models were additively manufactured, articulated, and scanned using a Coordinate Measurement Machine (CMM, n=1). Positive/negative occlusal contacts were recorded. Digital impressions were collected from the reference models using a Trios 4 (3Shape) IOS with “Adjust for contacts” feature enabled (IOS_Ad, n=10) and duplicated without this feature (IOS, n=10). IOS_Ad scans were processed to create test models using MAX UV385 (Asiga) and NextDent 5100 (3DSystems) AM devices. Conventional workflow was replicated with VPS impressions and Type IV stone. AM and stone models were articulated and digitized with E4 (3Shape) in three occasions: with/without AM positioning pins and after manual occlusal correction (Co). Inter-arch distances and 3D contact area were measured in digital models and compared. Statistical tests used were Shapiro-Wilk, Levene’s, Welch’s t-test, and 2-way ANOVA ($\alpha=.05$).

Results: IOS_Ad group had higher 3D contact trueness than IOS, Stone, Stone_Co ($p<0.05$). “Adjust for contacts” feature increased the 3D contact trueness ($p=0.00$, $\Delta=34.51\text{mm}^2$). Effect of manual occlusion correction of stone casts was insignificant ($p>0.05$). Digital impressions had higher occlusal trueness than AM models after removal of the pins ($p<0.05$). Introduction of errors was mostly higher in AM rather than IOS ($p<0.05$). 3D contact area analysis showed similar deviations of AM and stone models ($p>0.05$).

Conclusions: The study partially approved the null hypothesis, indicating that AM and stone models have a similar trueness of occlusion.

The authors declare that they have no known competing financial interests or personal relationships that could have appeared to influence the study.

Keywords: Intraoral scanner; Additive manufacturing; Trueness; Dental Occlusion

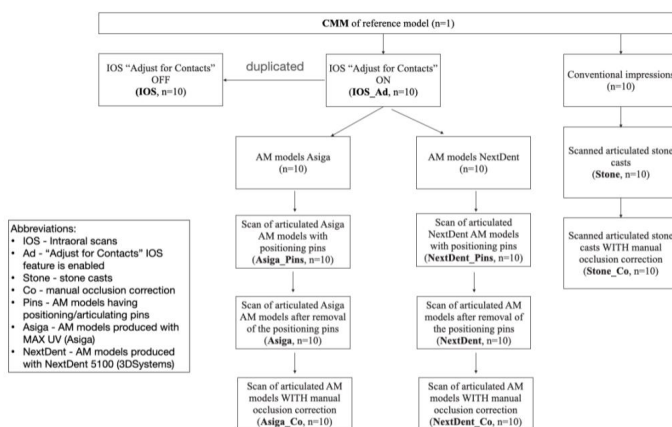


Figure 1. Study scheme.

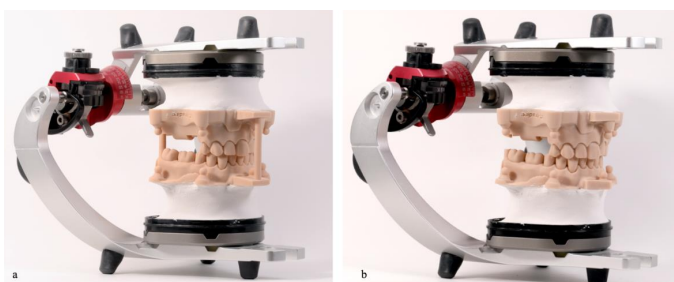


Figure 2. Articulated AM models with positioning pins.

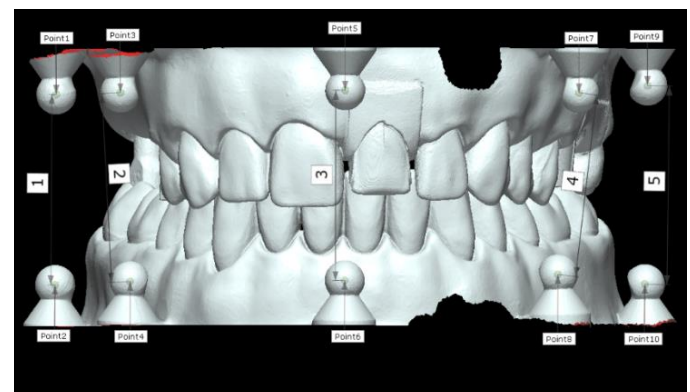


Figure 3. Numeration of the inter-arch distances.




Figure 4. 3D contact area analysis (mm).

Systematic Review on The Correlation Between Presence of Effusion and Pain in TMD Patients

Filippo Sornig^a, Matteo Val^b, Nicolò Giuseppe Sorrenti^a, Luca Guarda Nardini^b, Marco Ferrari^a, Daniele Manfredini^a

(^aUniversità degli Studi di Siena; ^bOspedale Ca' Foncello Treviso)

Objective: The aim of this systematic review is to present a thorough review of the literature regarding the correlation between the presence of effusion on the magnetic resonance (MRI) imaging and the clinical presence of pain, in a homogeneous group of patients with a temporo-mandibular disorder (TMD).

Materials and Methods: From January to February 2023 a systematic review of literature was performed on the main platforms for scientific research (PubMed, Scopus). This analysis follows a PICO model in order to select those articles which assessed the relationship between temporomandibular joint effusions in the MRI and clinical pain in TMD patients. The review follow the PRISMA guideline in the selection of the articles.

Results: The MeSH terms used for the research were “tmj AND mri”. For this search a total of 2714 articles were initially retrieved. Only 13 of these articles answered the research question.

In 7 articles a relationship between effusion and pain was found; 4 found a relationship between pain and disk displacement (DD); 7 articles found a relationship between effusion and disk displacement (DD) 1 study though stated that there was no correlation between effusion and disk displacement (DD).

Conclusions: The literature clearly suggests a correlation between the presence of effusions and clinical pain in TMD patient. Furthermore correlations were found between effusion and disk displacement (DD) and pain and disk displacement (DD).

Keywords: Temporomandibular Disorders, Effusion, Disk Displacement

Bond Strength Evaluation of Different Types of Resin Based Luting Cements Before and After Dynamic-Aging

Sadullah Uctasli¹, Irem Buyukates^{1,2}, Ezgi Oztol¹

(¹Ankara University, Faculty of Dentistry, Ankara, Turkey; ²Ankara University, Graduate School of Health Sciences, Ankara, Turkey)

The aim of the present study was to evaluate shear bond strength of two different types of resin based luting cements to CAD/CAM resin composite block before and after dynamic-aging procedures.

Forty CAD/CAM resin composite blocks (Cerasmart 270, GC) with 2-mm thickness and cylindrical specimens (3,6 mm diameter, 5 mm height) were prepared using light-cure resin composite. CAD/CAM specimens divided into 2 subgroups depending on aging procedure (n=20/group). Then the specimens subdivided into 2 groups (n=10/group) based on the resin luting cement types either dual-cure composite resin luting cement (RelyX Universal, 3M-ESPE) or dual-cure self adhesive resin cement (G-Cem Link Force, GC). Surface treatment protocols are applied to the CAD/CAM blocks and composite resin blocks. After applying universal adhesive agent (Scotchbond-Universal-Plus, 3M-ESPE), in order to simulate clinically relevant luting cement thickness, selected cements were applied to between the inner surface of CAD/CAM specimens and resin composite cylindrical specimens with finger pressure. Polymerization of dual-cure luting cements were achieved using high-power LED-LCU (D-Light

Pro, Gc) through the outer surface of CAD/CAM specimens for 40-seconds light irradiation time. After polymerization, the specimens were stored for 24-hour in water at 37°C. Twenty specimens were thermocycled by 5°C-55°C for 10000 cycle. Other twenty specimens were connected to the universal test machine for to evaluate bond strength of test specimens using 1 mm/min crosshead speed until bond strength failure. Dynamic-aged specimens were subjected to the same procedure.

Considering before and after dynamic-aging, two-way ANOVA showed that, there were no statistically significant difference between tested dual-cure resin composite luting cement (p<0,05). However, there were statistically significant difference between tested dual-cure self adhesive resin cement (p>0,05).

Dynamic-aging procedure did and did not have deleterious effect on dual-cured resin composite luting cement and self adhesive resin cement, respectively. For adhesive cementation technique, composite resin luting cement is more appropriate choice.

Keywords: CAD/CAM; composite resin luting cement; dynamic-aging; shear bond strength; short fiber-reinforced composite

CAD-CAM Ceramic Inlay Restorations: Evaluating Fracture Strength with Different Instrumental Cavity Preparation Methods

Assist. Prof. Ayben Şentürk, PhD, DDS¹, Doctoral Student Onur Alp Halaçlı, DDS², Professor Berk Bellaz PhD, DDS³, Professor Mehmet Ali Kılıçarslan, PhD, DDS¹

(¹Ankara University, Faculty of Dentistry, Department of Prosthodontics, Ankara, Turkey; ²Ankara University, Graduate School of Health Sciences, Department of Prosthodontics, Ankara, Turkey; ³Üsküdar University, Faculty of Dentistry, Department of Prosthodontics, İstanbul, Turkey)

Objectives: The fracture strength of ceramic inlay restorations were evaluated after the use of different instrumental preparation methods.

Materials and Methods: 48 extracted human molar teeth were divided into four groups, and inlay cavity preparations were performed using different instruments for each group. The groups are as follows: Group 1: Expert inlay diamond bur set was used for preparation, followed by finishing with an ultrasonic instrument (Intensiv+Sonicflex (IS)), Group 2: Only the expert inlay diamond bur set was used (Intensiv (I)), Group 3: Standard fissure diamond burs were used for preparation, followed by correction with an ultrasonic instrument (Standard+Sonicflex (SS)), Group 4: Only standard diamond burs were used for preparations (Standard (S)). The digital impressions of the inlay cavities were obtained, and the design of inlay restorations was performed using CAD program. Inlay restorations were produced from feldspathic blocks and cemented with resin cement. Afterward, the inlays were subjected to a single-load failure test using a universal testing machine. All data were analyzed statistically.

Results: The highest fracture strength mean value was observed in the IS group, with a value of $1712.17N \pm 546.990$. This was followed by the I group ($1370.99N \pm 605.877$), the SS group ($1207.76N \pm 558.551$), and the S group ($941.73N \pm 372.361$). The lowest fracture strength was observed in the S group. The highest fracture strength was observed in the IS group. The IS group showed a statistically significant difference compared to the S group ($p < 0.05$).

Conclusion: The group utilizing both the intensive diamond bur set and ultrasonic instruments (IS group) demonstrated the highest fracture strength compared to other groups. On the other hand, the group that used only standard diamond burs (S group) exhibited the lowest fracture strength. These results highlight the superior performance of the expert inlay preparation instruments in terms of fracture strength, emphasizing the importance of utilizing advanced instruments for optimal outcomes in inlay restorations.

Keywords: Ceramic inlay restorations, CAD-CAM, fracture strength, inlay preparation, ultrasonic instruments

Wear of Lithium Disilicate Canine Restorations Over 3 Years of Clinical Service

Dr. med. dent. Gintare Burian¹, Dr. med. dent. Laura Pannenbäcker², Prof. Dr. med. dent. Jan-Frederik Güth³, Prof. Dr. med. dent. Daniel Edelhoff², PD Dr. med. dent. Christine Keul²

(¹Private Practice, Swiss Biohealth Clinic, Brückenstrasse 15, 8280 Kreuzlingen, Switzerland; ²Department of Prosthetic Dentistry, LMU University Hospital, Ludwig-Maximilians-University Munich, Goethestrasse 70, 80336 Munich, Germany; ³Department of Prosthodontics, Goethe University, Center for Dentistry and Oral Medicine (Carolinum), Theodor-Stern-Kai 7, 60596 Frankfurt am Main, Germany)

Objective: The aim of this study was to evaluate the mean height and maximal height loss of canine restorations in patients after complete prosthetic rehabilitation due to severe tooth wear with lithium disilicate ceramic over 3 years.

Materials and Methods: 40 canine restorations were analyzed in 10 patients as part of a clinical study with complex rehabilitations made of monolithic lithium disilicate ceramic (IPS e.max Press, Ivoclar, Schaan, Liechtenstein). Data was collected at annual recall appointments with polyether impressions and digitalization of the gypsum cast using a laboratory scanner. The obtained datasets ($n=104$) were exported to a surface analysis software (GOM Inspect Professional, Braunschweig, Germany) and were individually overlaid over the baseline dataset. The superimposition error of $10\mu m$ was determined as exclusion criteria for further data analysis ($n=16$). The mean and maximal height loss of occlusal-contact areas were quantified. Kruskal-Wallis test was used to determine significant differences

between groups regarding time, as the data showed significant deviations from the Gaussian distribution (Shapiro-Wilk test).

Results: Mean/Maximum wear rates resulted as following: for the first year $33.2 \pm 21.5/97.7 \pm 63.5 \mu m/year$, for the second year $22.7 \pm 19.5/57.9 \pm 37.0 \mu m/year$, for the third year $18.1 \pm 11.5/56.9 \pm 40.7 \mu m/year$. Both groups showed significant differences regarding time, with decreasing values over time.

Conclusions: This data gives first insights into clinical wear of canine restorations made of monolithic lithium disilicate ceramic. This study showed comparatively low restorations wear rates, with significant differences between groups with rising time in situ. Highest mean and maximum wear rates could be observed for the first year of clinical service. Generally, wear of canine restorations should be taken into account when choosing the material for prosthetic rehabilitation, as the canine guidance ensures adequate function in dynamic occlusion and reduces shear forces on posterior teeth and restorations.

Evaluation Of Quality Of Life And Satisfaction In Patients With Implant-Supported Fixed Partial Dentures

Isil Kecik Buyukhatipoglu, Assistant professor*, Melek Ozdemir, Research assistant*

(*Gaziantep University. Faculty of Dentistry. Department of Prosthetic Dentistry. Şahinbey/Gaziantep/TURKEY)

Objectives: This study evaluated the satisfaction of fixed implant-supported prosthesis by using the oral health impact profile-14 (OHIP-14) and VAS scale.

Materials and methods: A total of 55 patients treated with the implant supported fixed partial denture were matched in pairs based on gender, age, subject's medical parameters, type of incident, zone of replacement and prosthetic design. The healthy 185 implants were included in the study for according to the dental implant health scale developed and accepted by the International Congress of Oral Implantologists Consensus (ICOI). The patient-reported effect was prospectively obtained by measuring oral health impact (OHIP-14) with a follow-up period ranging from 5 to 8 years.

Results: The majority of the dental implants were inserted anterior region (18.12%) and posterior region (81.88%). The anterior zone implants were 18.25%. The prosthetic treatments were served as: 55.35% implant supported single crown and

44.65% implant supported fixed partial denture. The cement-retained restorations were 76.25% and screw-retained restorations were 23.75%.

Mean and standard deviation, median minimum and maximum frequency and rates were put into use for descriptive statistics of data. Distribution of variables was checked using One-Sample test. SPSS 22.0 programme was put into use for the analyses.

Results: The results of this study indicated that patient satisfaction with fixed implant supported prosthesis was high in all patients. It was inferred from the Ohip 14 and VAS scores analyses that fixed implant-supported prosthesis make a positive contribution to the quality of life for oral health. Improvement of the quality of life for oral health concordantly made a positive impact on the general state of health.

Conclusions: The fixed implant-supported prosthesis make a positive contribution to the quality of life for oral health.

Note: The authors have no conflicts of interest to declare.

Oral Health-Related Quality Of Life In Edentulous Patients Treated With Implant-Supported Prostheses

Isil Kecik Buyukhatipoglu, Assistant professor*, Derya Dogan Evlice, Research assistant*, Fatih Sari, Associate professor*, Derya Gursel Surmelioglu, Associate professor**

(*Gaziantep University. Faculty of Dentistry. Department of Prosthetic Dentistry. ** Gaziantep University. Faculty of Dentistry. Department of Restorative Dentistry. Şahinbey/Gaziantep/TURKEY)

Objectives: Oral health-related quality of life (OHRQoL) is affected by different variables. Tooth loss can have negative functional, aesthetic, and psychological consequences. Dental implant treatment approach have gained increasing popularity over the years in daily practice because of dental implant's high survival rates over time and they have become the preferred treatment option rehabilitation of edentulous patients. It is important to understand edentulous patients' perceptions about the impacts of treatment options on their oral health-related quality of life (OHRQoL). This clinical study aimed to evaluate the maxillary or/and mandibular edentulous patient satisfaction of 2-6 implant supported fixed/removable prosthetic denture designs opposing with different prosthetic designs.

Materials and methods: A total of 36 edentulous participants received two-six implants were treated with removable or fixed prosthesis with a mean follow-up time of at least 5-8 years in the mandible or/and maxilla were selected for this study. Each group divided equally into 3 groups according to the dental prosthetic designs. Group 1: Mandibular two implants retained overdenture with locator connections and opposing maxillary

total prosthesis treated group (n=13); group 2: Maxillary and mandibular 4-6 implant supported fixed full-arc prosthesis treated group (n=13); group 3: Mandibular 4 implants supported fixed full-arc and opposing maxillary total prosthesis treated group (n=12). Minimum 5 years from completing the prosthetic treatment, the patients recalled to the clinic and were requested to fill the OHIP 14 questionnaire and VAS scale to assess their overall quality of life and level of satisfaction, both esthetically and functionally. Measurements were performed at baseline, and at 5-8 years following implant loading. Comparison of data between groups was performed using the Kruskal Wallis tests. The level of statistical significance was considered at $p < 0.05$.

Results: The results of this study indicated that patient satisfaction with both fixed and removable implant supported prosthesis served successful results in all patients. There were no significant differences among all groups.

Conclusion: This clinical study reveals that patients with removable or fixed implant-supported prosthesis in edentulous jaws were satisfied with their oral health-related quality of life (OHRQoL).

Note: The authors have no conflicts of interest to declare.

Effects of Occlusal and Axial Holes on The Implant Support on Crown Adaptation and Retention

Fatma Beyza Koyuncu, Aykut Gönder, Mehmet Ali Kılıçarslan

(University of Ankara, Faculty of Dentistry, Ankara, Turkey; Republic of Türkiye Social Security Institution (SGK), Ankara, Turkey)

Objectives: Cement retention is commonly used for implant-supported prostheses despite cement-related issues. The aim is to compare the effects of hole structure on titanium abutments on retention and marginal adaptation of cement-retained implant-supported prostheses when using three different materials. For this purpose, open and closed holes on abutments were used to evaluate the retention and marginal fit of cemented Co-Cr crowns on titanium abutments.

Materials and methods: In the study, abutments with a diameter of 6 mm and Co-Cr crowns were used. The abutments were divided into two groups. In the first group, the abutments had a 10 mm teflon cap on the screw, with both the occlusal and axial holes open. In the second group, only the occlusal opening was covered with temporary cement (cavit) on the 10 mm teflon cap.

Different adhesive agents were used for both groups: 1) Zinc phosphate cement (İnci Dental, Turkey), 2) Temporary cement (İnci Dental, Turkey), 3) Flowable composite (Dentsply Sirona, Germany). Excess cement was standardized with 50N pressure

and removed using a scalpel. The samples were evaluated for marginal adaptation using an optical microscope (Leica) at 1.25x magnification. Tensile tests were performed using a universal testing machine (Lloyd Instruments) at a speed of 1 mm/s. The results were statistically analyzed.

Results: Temporary cement (241.546 N-219.505 N) and compomer (16.062 N- 6.928 N) showed a decrease in retention for both open and closed application of the cement escape hole, while an increase was observed in zinc phosphate cement (282.750 N- 358.915 N). Highest retention was observed in zinc phosphate cement, while the lowest retention was observed in the compomer group.

Conclusions: Closed application of zinc phosphate cement is preferred for long-term permanent cementation, while temporary cements are suitable for interim use. Compomers are suitable for very short-term provisional applications.

Keywords: Dental Implantation; Dental Cement; Prosthesis Retention; Dental Marginal Adaptation

Fracture Resistance of Zirconia Overlays with Different Preparation Designs with and without Endodontic Access

Carlos A. Jurado¹, Kelvin I. Afrashtehfar^{2,3}, Manuel Robles⁴, Terry J. Lindquist¹, Abdulaziz Alhotan⁵.

(¹The University of Iowa College of Dentistry and Dental Clinics, Iowa City, Iowa, USA; ²Ajman University College of Dentistry, Ajman City, United Arab Emirates; ³University of Bern School of Dental Medicine, Bern, Switzerland; ⁴Universidad Vizcaya de las Americas School of Dentistry, Hermosillo, Sonora, Mexico; ⁵King Saud University College of Applied Medical Sciences)

Objectives: To evaluate the fracture resistance of zirconia overlays or occlusal veneers with various preparation designs, considering the presence or absence of endodontic access.

Materials and Methods: Ninety translucent zirconia (5Y-PSZ) overlay restorations (n=15/group) were fabricated in different preparation designs with and without endodontic access and were categorized into six groups: group 1 (M4), with chamfer margin 4 mm above the gingival level; group 2 (M4End), with chamfer margin 4 mm above the gingival level and endodontic access, group 3 (M2), with chamfer margin 2 mm mm above the gingival level; group 4 (M2End), with chamfer margin 2 mm above the gingival level and endodontic access; group 5 (nM), overlay with no chamfer margin; and group 6 (nMEnd), overlay with no margin and endodontic access. Restorations were bonded to mandibular first molar resin dies, and the groups with endodontic access were sealed with flowable resin composite. All restorations underwent 100,000 cycles of thermal cycling between 5°C and 55°C, followed by loading

until fracture. Maximum load and fracture resistance were recorded. ANOVA with Tukey post-hoc tests were used for statistical comparison ($\alpha < 0.05$).

Results: The fracture resistance among the overlays of different designs with and without endodontic access varied ($p < 0.001$). Overlays with margin located 2 mm above the gingival margin exhibited the highest fracture resistance, both without group 3 (M2) and with group 4 (M2End) endodontic access. This was followed by overlays with margin 4 mm above the gingiva without group 1 (M4), group 5 (nM), and group 6 (nMEnd). Group 2 (M4End) the overlays with finish line at 4 mm and endodontic access displayed the lowest fracture resistance values.

Conclusions: Zirconia overlay restorations with endodontic access have lower fracture resistance than those without endodontic access. Overlay with margins closer to the gingival level display higher fracture resistance compared to those with high chamfer and no chamfer margin.

Table 1. Fracture load and fracture resistance at maximum load of zirconia overlay with different preparation designs with and without endodontic access.

Group Resistance at load (±SD), MPa	Type of Restoration	Fracture Load (±SD), N	Fracture maximum
Group 1 (M4)	Overlay restoration with finish line at 4 mm from gingival margin	567.07 (58.48) ^A	22.70 (2.27) ^A
Group 2 (M4End)	Overlay restoration with 4 mm finish line and endodontic access	458.05 (65.36) ^B	19.85 (1.53) ^B
Group 3 (M2)	Overlay with finish line located 2 mm coronally to gingival margin	959.27 (109.87) ^C	28.43 (2.80) ^C
Group 4 (M2End)	Overlay with margin located 2 mm above the gingiva and with endodontic access	842.94 (135.97) ^D	25.10 (2.68) ^D
Group 5 (nM)	Occlusal veneer (no margin overlay)	543.01 (41.69) ^{AB}	22.18 (1.37) ^{AB}
Group 6 (nMEnd)	Occlusal veneer with endodontic access	502.10 (40.09) ^{AB}	20.48 (1.61) ^{AB}

Note: Different superscript uppercase letters indicate significant difference ($p < 0.05$) within groups in each column. Fifteen specimens per group were tested.

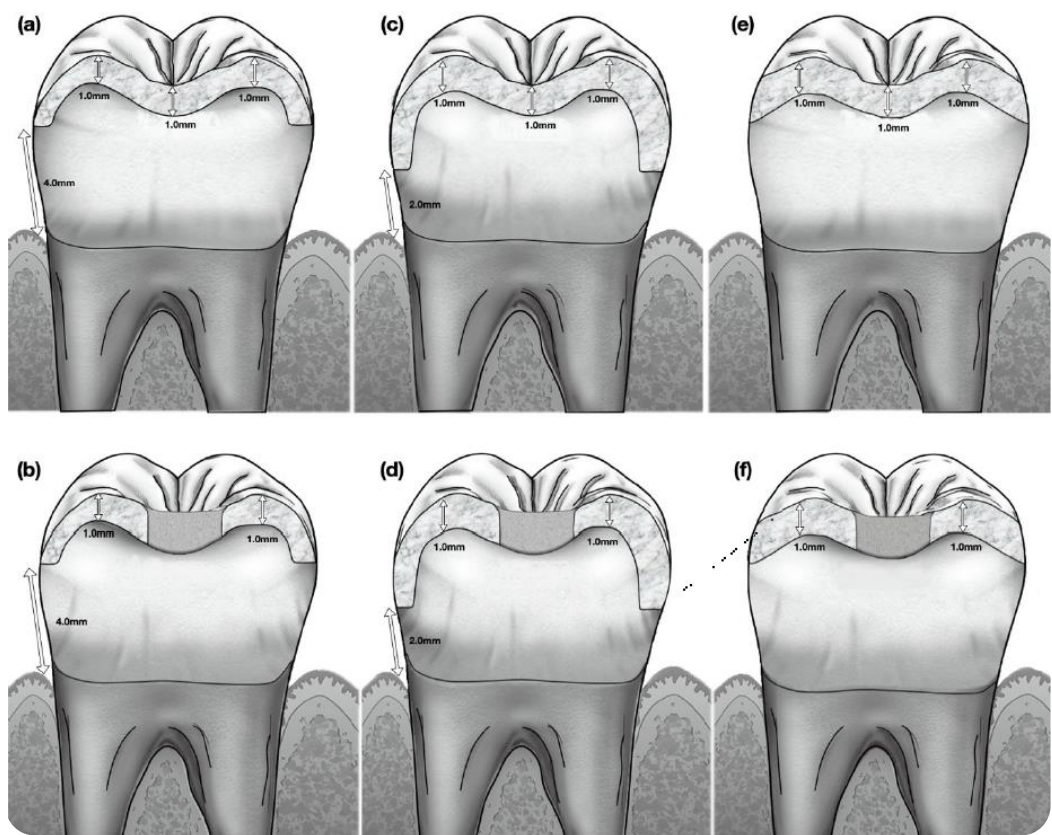


Figure 1: Cross-sectional illustration of different types of overlay restorations: (a) with margin located 4 mm coronal to the gingival level without endodontic access (Group 1); (b) with margin located 4 mm coronal to the gingival level with endodontic access (Group 2); (c) with margin located 2 mm coronal to the gingival level (Group 3); (d) with margin located 2 mm coronal to the gingival level and with endodontic access (Group 4); (e) without margin (Group 5); and (f) without margin and with endodontic access (Group 6).




Figure 2: Representative SEM images of group 1 and 2. (A) Overlay restoration at x16 and x40 magnification. (B) Overlay restoration with endodontic access at x16 and x40 magnification.




Figure 3: Representative SEM images of group 3 and 4. (A) Overlay restoration with margin located 2 mm coronally to the gingival level at x16 and x40 magnification. (B) Overlay restoration with margin located 2 mm coronally to the gingival level and with endodontic access at x16 and x40 magnification.




Figure 4: Representative SEM images of group 3 and 4. (A) Overlay restoration with no margin at x16 and x40 magnification. (B) Overlay restoration with no margin and with endodontic access at x16 and x40 magnification.

Impact of Length Variation and Manufacturing Orientation of Hollow Alumina Cylinders Manufactured By Stereolithography

Nihal Raiah¹, Corentin Denis^{1,2,3}, Marion Dehurtevent^{1,2,3}

(¹INSERM U1008, Lille University, Lille, France; ²Dental school, Lille University, Lille, France; ³Lille University Hospital, Lille, France)

Objective: Ceramic dental prosthesis manufactured by stereolithography (SLA) are less adapted to the tooth preparation than those manufactured by subtractive technique. The objective of this study was to evaluate the influence of the variation of the length and the shaping orientation of a hollow cylinder on the deformations due to the manufacturing process of SLA.

Materials and Methods: four cylinders of 3 different lengths were manufactured by SLA. The smaller cylinder was manufactured in 2 orientations. The samples were scanned by microtomography before and after heat treatment and the root mean square (RMS) was calculated using the control software.

Results: the RMS in the lower surface increased compared to the upper surface. The RMS in the lower surface of the horizontally shaped small cylinders was lower than those vertically shaped. For the upper surface, the RMS of the small cylinders has decreased compared to the medium and large ones. These results could be explained by the proximity of the walls of the cylinder in the intrados as well as the deformations following the removal of the pillars in the extrados.

Conclusions: the variation in length and the shaping orientation influenced the deformations of the simplified models of dental prostheses.

Prosthetic and Sociodemographic Modulators of the Oral Health-Related Quality of Life of Implant Overdenture Wearers

Angelica Lo Sardo, D.D.S., MSc.^{a, b} Arelis Preciado-Urbe, D.D.S., MSc., Ph.D.^a Jaime Del Río-Highsmith, M.D., Ph.D.^a Juan Manuel Aragoneses-Lamas, M.D., D.D.S., Ph.D.^b Raquel Castillo-Oyagüe, D.D.S., Ph.D.^a

^aFaculty of Dentistry, Complutense University of Madrid (U.C.M.), Madrid, Spain; ^bFaculty of Dentistry, Alfonso X El Sabio University (U.A.X.), Madrid, Spain

Objectives: To identify possible factors that may modulate the oral health-related quality of life (OHRQoL) in patients with maxillary implant-overdentures (IOMx).

Materials and Methods: 70 patients wearing IOMx were recruited by a consecutive sampling procedure for this cross-sectional study. Participants were classified into 2 balanced groups according to their partnership status (n= 35 each): Group-1 (patients with partner), Group-2 (patients without partner); and concerning their gender (n= 35 each): Group-A (women), Group-B (men). QoLIP-10, QoLFAST-10, and QoLDAS-9 questionnaires were responded, and patients were clinically examined. Sociodemographic, and prosthesis-related data were gathered. Descriptive statistics were calculated. Potential QoL modulators were assessed using non-parametric probes (Chi-square, Kruskal-Wallis, and Mann-Whitney U tests; $\alpha = 0.05$).

Results: The QoLDAS-9 scale discriminated the study groups ($p < 0.05$). The partnership status significantly affected the item 7 of the QoLDAS-9 index (Socio-dental dimension), the Group-2 being more satisfied with the size of the prosthetic teeth compared to Group-1 ($p = 0.005$).

The gender modulates the QoLDAS-9 total score, conferring to Group-A better self-perception with the IOMx ($p = 0.000$), concretely about its Psycho-facial ($p = 0.000$) and Interactive ($p = 0.016$) domains. Group-A referred better wellbeing with the IOMx when speaking (item 9, Performance subscale) with the QoLIP-10 ($p < 0.05$).

The partnership status affected the QoLFAST-10 Social dimension ($p < 0.02$) and total score ($p < 0.05$), the volunteers without partner being more satisfied.

The retention system did not impact the QoL perception, while the bar worsen the appearance of the oral mucosa ($p = 0.05$). The OHRQoL increased as the retention, stability, and aesthetics of the prosthesis improved ($p < 0.05$).

Conclusions: Overall, IOMx wearers have a satisfactory OHRQoL. The IOMx retention system does not influence the OHRQoL. Women and patients without partner are more satisfied with the treatment. A better OHRQoL is perceived when the retention, stability, and aesthetics of the restoration are suitable.

Effect of Surface Cleaning on Zirconia and Zirconia-Reinforced Lithium Silicate Ceramic-Resin Bonding Strength

Özge Kırarslan Karagöz¹, Bengisu Yıldırım¹, Aysıla Tekeli Şimşek¹, Övül Kümbüloğlu², Mehmet Ali Güngör¹

(¹Uşak University Faculty of Dentistry, Uşak, Turkey; ²Ege University Faculty of Dentistry, İzmir, Turkey)

Objectives: It is claimed that a reliable bond is created by effectively cleaning the contaminated surfaces of restorations with proper surface cleaners. This study aimed to evaluate the effect of different surface cleaning methods on the bonding of resin cement to zirconia and zirconia-reinforced lithium silicate ceramic.

Materials and methods: 54 slices obtained from zirconia-reinforced lithium silicate (ZLS) (Vita Suprinity) and zirconia (ZIR) (IPS e.max ZirCAD) blocks. The final thickness of the specimens set to 1 mm \pm 0.02 mm. The specimens divided into nine groups both for ZLS and ZIR: non-contamination, saliva - air/water spray, saliva - Ivoclean, saliva - Katana Cleaner, light body - air/water spray, light body - Ivoclean, light body - Katana Cleaner and light body - alcohol. X-ray photoelectron spectroscopy (XPS) analysis performed to determine chemical change to each group; SEM analysis performed for microscopic surface changes. The resin bond strength values were obtained by performing the micro-shear bond strength (mSBS) test. The specimens examined with a stereomicroscope to investigate the failure types.

Results: Contamination with saliva and light body silicone decreased the bond strength significantly ($p < 0.05$). The

mSBS value of ZLS-non contamination group was the highest (27.69 ± 7.1) and the mSBS obtained after decontamination of the saliva with the Katana Cleaner (15.32 ± 7.5) was statistically higher for ZLS specimens ($p < 0.001$). For ZIR specimens highest mSBS value was obtained with Katana Cleaner (18.95 ± 6.9 , $p = 0.803$). The highest mSBS values for ZLS and ZIR specimens found after decontamination of the light body silicone with alcohol (23.26 ± 3.1 , $p = 0.220$; 19.77 ± 8.6 , $p = 0.729$). According to XPS analysis, Ivoclean removed element C better than other cleaners from the surface, similarly alcohol removed element Si better than other cleaners.

Conclusion: Katana Cleaner could be used as a surface cleaner after contamination with saliva, and alcohol found to be more effective after contamination with light body silicone.

Keywords: Cleaner; Contamination; Saliva; Zirconia; Zirconia-Reinforced Lithium Silicate

Funding agency and grant number: Uşak University Scientific Research Projects Foundation, Grant/Award Number: (2020/DHU001)

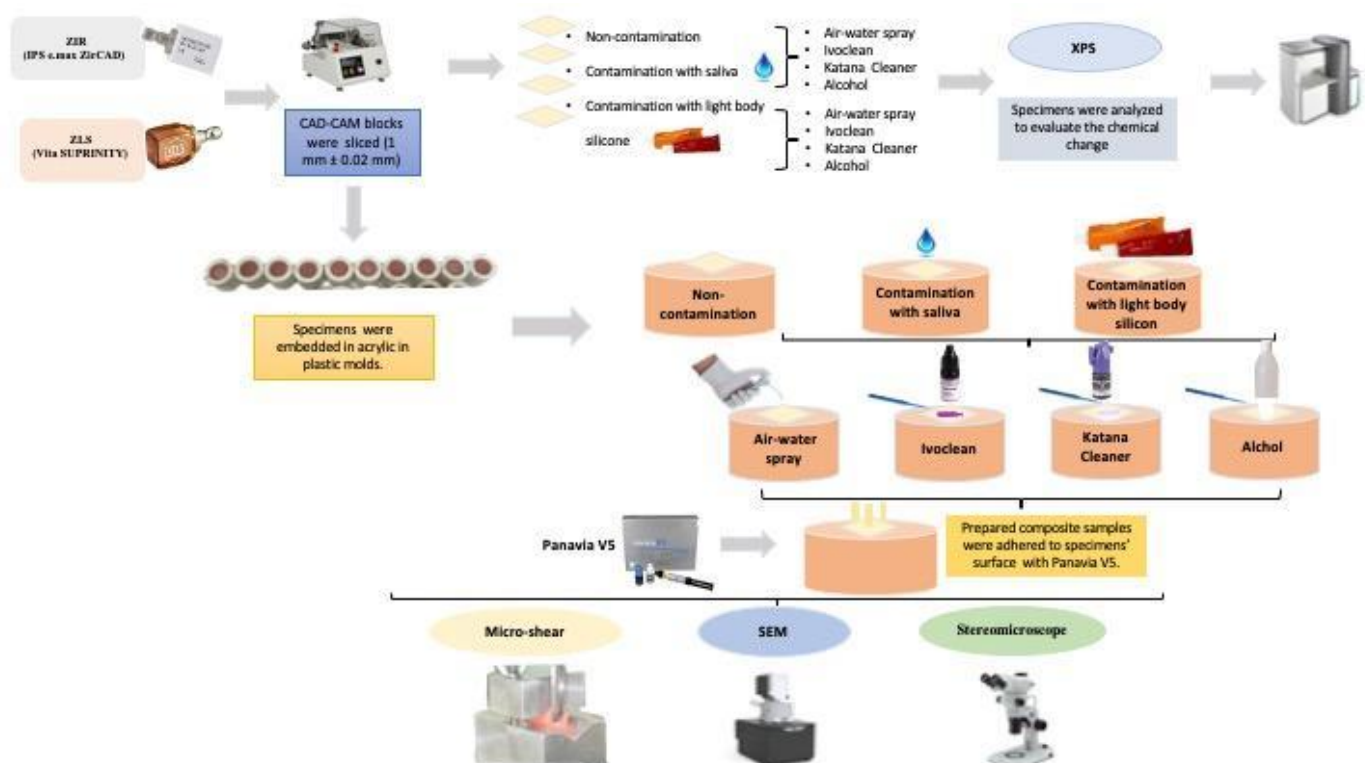
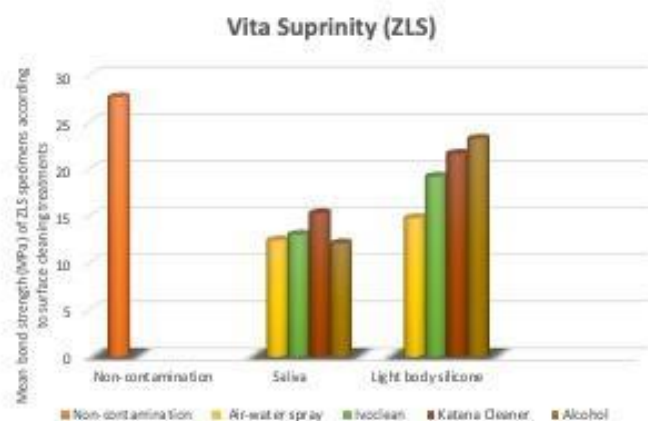
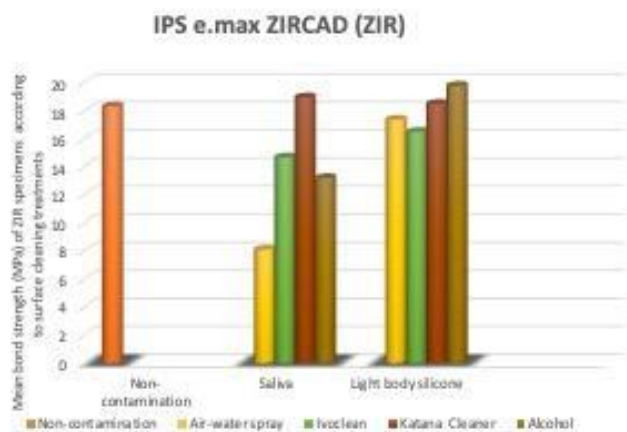
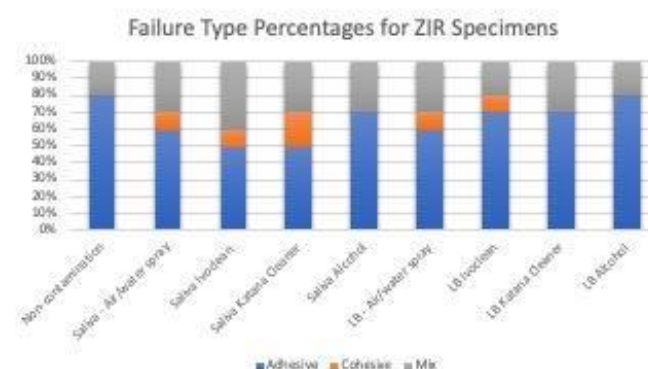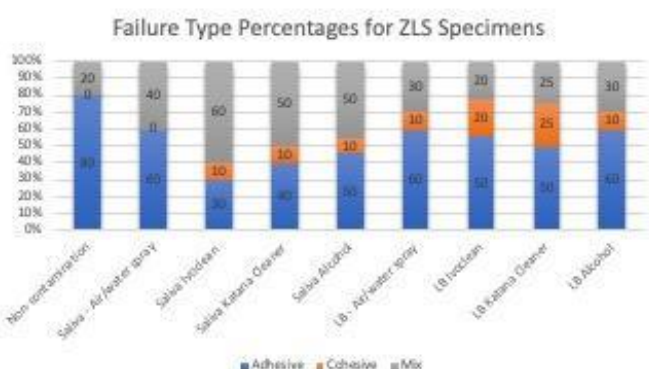


Figure: Workflow of the study.



Graph 1: MPa values of the groups.



Graph 2: Percentage of failure types according to groups.

Evaluation of Different Attachment Types in Mandibular Overdenture Prostheses with 3D Finite Element Stress Analysis Method

Tekeli Simsek Aysila, Celikkol Ongun, Yildirim Bengisu, Gungor Mehmet Ali

(Uşak University, Faculty of Dentistry, Uşak, Turkey)

Abstract: The manner in which stresses are transferred to the bone surrounding implant-supported or implant-retained overdentures (IOs) is one of the most significant factors in determining their efficacy. The objective of this study is to evaluate the stress on the implant and prosthetic components according to the retention system: locator, ball attachment, bar attachment, and telescopic attachment system.

Material and Method: Using SpaceClaim, 3D finite element models were created to simulate clinical situations. These models included IOs with five distinct attachment systems: locator attachment system, locator R-Tx attachment system, ball attachment system (dimensions and material properties according to Zest Anchors, USA), bar attachment system and the telescopic attachment system (Dimensions and material properties of primary and secondary copings were in accordance with Dentsply, Ankylos Syncone/5°, USA).

Each overdenture's central fossa in the molar region was subjected to a 35N compressive force that was applied in both

the vertical and oblique directions. A non-linear static contact analysis was performed to determine the distribution of stress among the various IOs components. Following this, the models were analyzed using the finite element software ANSYS, and the results were displayed using Von Mises stress patterns.

Results: Both oblique and vertical loading substantially increased the maximal von Mises stresses on the implants when they were affixed using the telescopic attachment system. Under vertical loading, the maximal von Mises stresses on the abutment were greater for the ball attachment system, whereas they were greater for the telescopic attachment system under oblique loading.

Conclusions: As clinical tip, bar attachment, locator attachment and locator R-Tx attachment can be considered as a suitable alternative to telescopic attachment system and ball attachment for IOs.

This study was funded by Uşak University Scientific Research Projects Coordination Unit. (Project Number: 2023/SB001)

Using an Implant Carrier as a Temporary Implant Abutment on Immediately Loaded Implants in Extraction Sockets

Arnolds Bite

(Riga Stradins University Institute of Stomatology)

Objectives: Immediate implant placement and provisionalization in extraction sockets can be beneficial for preserving soft and hard tissues around the implant. However, there is a lack of research evaluating the clinical outcomes of using Ankylos implant carriers as temporary abutments for immediately loaded implants.

The study aimed to investigate the clinical and esthetic outcomes of immediately placed and loaded Ankylos implants in extraction sockets, using implant carriers as temporary abutments.

Materials and Methods: Nine patients (four women, five men) aged 41-66 were included. Assessment included radiographic, clinical, and photographic analysis. Radiographic assessment involved periapical radiographs taken at different stages. Clinical assessments included plaque index, bleeding index, gingival index, and others. Photographic assessments involved photographs with a Nikon Z6 camera. Data analysis was performed using GraphPad Prism V.9.1 for macOS.

Results: After 3 months, mid-facial peri-implant mucosal level showed a mean soft tissue loss of 1.18 ± 0.42 mm. Marginal bone level displayed a mean value loss of 0.53 ± 0.33 mm. Pink Esthetic Score scores averaged 7.9 ± 1.45 . No major complications such as implant loss or inflammation were encountered. All implants remained stable and were loaded for 3-4 months before permanent crown restoration.

Conclusion: The use of Ankylos implant carriers as temporary abutments for immediately loaded implants in extraction sockets can be an effective option, with minimal soft and hard tissue loss. The PES scores are comparable to other studies.

Clinical Implications: This study suggests that immediate implant placement with Ankylos implant carriers as temporary abutments may be a viable option for preserving tissues and achieving satisfactory esthetic outcomes. Dental professionals should consider this as an alternative treatment option. Further research with larger sample sizes is needed for a more comprehensive understanding.

Titanium Surface Roughness After Brushing With Activated Charcoal Toothpaste

Bedia Gokten

(Izmir Katip Celebi University)

Objectives: Grade 5 (Ti6Al4V) titanium alloy is widely used in dental abutment types. However, there are not enough studies about activated charcoal toothpaste effects on titanium surfaces although its increasing popularity. The aim of this study was to evaluate the effect of activated charcoal toothpaste usage on the surface roughness of Ti6Al4V.

Materials and Methods: Square shaped specimens (10×10×3mm) were prepared from medical Ti6Al4V alloy using guillotine cutting and the surfaces of them were finished with mirror-polished. Initial Ra values of the all specimens were measured by a contact profilometer. Then, specimens were divided into three groups (N=24, n=8): Unbrushed control group (Ti-C), brushed group with activated charcoal toothpaste (Ti-AC), brushed group with only distilled water (Ti-DW). Brushing simulation was performed using tooth brushing simulator (SD Mechatronic) with forward-backward motion in a linear distance of 5 mm, at speed of 25 mm/s, under 200g pressure for 10000 cycles to simulate 1-year of usage. The final roughness values of the specimens were measured after

brushed. Data were statistically evaluated by paired t-test to evaluate before and after roughness changes in brushed groups and one-way ANOVA and post-hoc Tukey test to comparison all groups ($\alpha=.05$).

Results: Changes in surface roughness were statistically significant in both Ti-AC and Ti-DW group when compared before and after roughness values by paired t-test ($p=.011$ and $p=.004$, respectively). However, when compared independent groups, group Ti-AC and Group Ti-DW were found to be similar ($p=.350$), and when compared with group Ti-C, there was no statistical difference ($p>.164$).

Conclusion: Brushing the titanium surface with activated charcoal toothpaste does not produce more significant roughness changes than the effects of brushing itself. Therefore, it can be said that its short-term use will not cause negative effects. However, further studies are needed to recommend its long-term use.

Keywords: Activated charcoal; toothbrushing; titanium

Effect of Activated Charcoal Toothpaste on the Surface Roughness of Feldspathic Ceramic

Aysegul Ceren Senkaya

(Izmir Katip Celebi University)

Objectives: Activated charcoal based toothpaste has gained popularity. Although there are studies showing that this toothpaste has an abrasive effect on enamel, there is not enough information about its effects on feldspathic ceramic. The aim of this study was to determine the effect of activated charcoal toothpaste usage on the surface roughness of feldspathic ceramics.

Materials and Methods: Specimens were prepared from feldspathic ceramic blocks (Vitablocs Mark II) by cutting in a thickness of 2 mm. Surfaces of the specimens were manually polished by the same operator and initial Ra values were measured by a contact profilometer. Then, specimens were divided into three groups (N=24, n=8): Unbrushed control group (C), brushed group with activated charcoal toothpaste (AC), brushed group with only distilled water (DW). Tooth brushing simulation was applied using tooth brushing simulator (SD Mechatronic) with forward-backward motion in a linear distance of 5 mm, at speed of 25 mm/s, under 200g pressure for 10000 cycles to simulate 1 year of usage. The final roughness values of the specimens were measured after

brushed. Data were statistically evaluated by paired t-test to evaluate before and after roughness changes in brushed groups and one-way ANOVA and post-hoc Tukey test to comparison all groups ($\alpha=.05$).

Results: Increasing in surface roughness were statistically significant in both AC and DW group when compared before and after roughness values ($p<.001$ and $p=0.003$, respectively). There were significantly differences between unbrushed control and brushed groups. The highest roughness values were observed in group AC. Group DW was exhibited higher roughness than control group ($p=.016$) but lower roughness than AC group ($p<.001$).

Conclusion: Brushing with activated charcoal toothpaste resulted in significant changes in feldspathic ceramic surface roughness. Therefore, activated charcoal toothpastes should not be preferred in patients who had feldspathic ceramic-based restorations.

Keywords: Activated charcoal; toothbrushing; dental porcelain

The Influence of Experience on Oral Health-Related Quality of Life in Complete Denture Wearers

Merve Ünal

(Usak University)

Objectives: Complete edentulism impacts patients' quality of life. Denture experience is crucial for analyzing the impact of denture usage. The main purpose of this study was to analyze the effects of denture experience, and demographics on oral health-related quality of life.

Materials and Methods: In this study, 352 patients were included who were treated with maxillary and mandibular complete dentures by a single clinician within four years and wore the dentures for a minimum of one year. Participants were evaluated in terms of age, gender, systemic diseases, denture experience, clinician advice, and wearing dentures at night. Answers to the Geriatric Oral Health Assessment Index and Oral Health Impact Profile questionnaires were collected, and a statistical analysis was performed.

Results: Both scales were found to be reliable, and a high degree of correlation was detected ($p = 0.00$). According

to Oral Health Impact Profile-14, the experience related to psychological discomfort ($p = 0.036$), social disability ($p = 0.01$), and handicaps ($p = 0.00$) while the Geriatric Oral Health Assessment Index found that the denture experience affects the behavioral impacts ($p = 0.00$). It was determined that factors of age, denture experience, clinician advice, and wearing dentures at night influenced oral health-related quality of life.

Conclusions: The findings of this study indicated that denture experience considerably improved patients' oral health-related quality of life. Also, Oral Health Impact Profile-14 and Geriatric Oral Health Assessment Index showed high levels of validity and reliability for edentulous patients.

Keywords: Complete Dentures; Oral Health; Patient Satisfaction; Quality of Life.

Microleakage of Enamel and Dentin Margins of Cervical Restorations After Dynamic Aging

Merve Uctasli¹, Irem Buyukates^{2,3}, Asli Elif Koroglu^{2,3}

(¹Gazi University, Faculty of Dentistry, Ankara, Turkey; ²Ankara University, Faculty of Dentistry, Ankara, Turkey; ³Ankara University, Graduate School of Health Sciences, Ankara, Turkey)

The aim of the present study was to compare microleakage of enamel and dentin margins of cervical restorations after restoring different types of composite-resin restorative materials.

Cervical cavities were prepared in both buccal and lingual surfaces of fifteen extracted sound human molar teeth using with cylindrical-shaped diamond burs under a continuous water flow. Cavity margins of enamel and dentin were located in 2mm above and below the cementum-enamel junction (CEJ), respectively. After cavity preparation two-step universal adhesive (G2-BOND Universal, GC) were applied to enamel by selective enamel etch mode and to dentin by self etch mode. Adhesive agent polymerized for 10-seconds by using high-power light emitting diode light curing unit (LED-LCU) (D-Light Pro, GC). Depending on the restoration of cavities (n=10/group) Group1: restored with short-fibre reinforced flowable composite indicated for dentin replacement in direct restorations (everX Flow, GC); Group2: restored with flowable composite (G-aenial Universal Flo, GC); Group3: 2/3 of cavity and 1/3 cavity restored with short-fibre reinforced and flowable composite. Polymerization of

restorative materials were achieved using high-power LED-LCU for 40-seconds light irradiation time. After finishing and polishing procedures restored test specimens were stored for 24-hour in water at 37°C and then thermocycled by 5°C-55°C for 10000 cycle (Thermocycler, The-1100, SD-Mechatronik, Germany). Microleakage measurements were achieved conventional dye penetration method for assessing microleakage in enamel and dentin margins surrounding the restorations.

One-way ANOVA showed that the mean microleakage of all tested groups showed significant differences ($p<0.05$) within both enamel and dentin margins. Group3, restoration with short-fibre reinforced and flowable composite revealed no and least leakage at enamel and dentin margin, respectively.

Within the limitations of this *in vitro* study, it can be concluded that, in clinical situation, if the cavity margin is placed below CEJ, it is advisable to use short-fibre reinforced flowable composite as a base material.

Keywords: dye penetration, dynamic-aging, flowable composite resin, microleakage, short-fibre reinforced composite

Evaluation of Bite Force After Implant-Supported Fixed Prosthesis Treatment: A Pilot Study

Şevval Öksüz, Esra Nur Avukat, Canan Akay, Emre Mumcu

(Eskişehir Osmangazi University Faculty of Dentistry, Department of Prosthodontics)

Objective: Partial tooth loss may be restored with tooth-supported fixed prostheses or implant-supported fixed prostheses. Evaluation of bite force is crucial in assessing oral function and the effectiveness of dental treatments. The aim of the study was to evaluate the maximum bite force (MBF) and oral health-related quality of life (OHRQoL) in patients with implant-supported fixed prostheses. In addition, it was aimed to determine the effect of gender, age, and Body Mass Index (BMI) on the MBF.

Material and methods: Ethical approval was obtained prior to the commencement of the study. Bite force values of three different dental conditions were evaluated: the fixed implant-supported prosthesis group (patients who had one or more posterior restored dental implants) and the control groups (dentate patients and patients using complete dentures). A total of 54 patients, with 18 individuals in each group, were included in this study. MBF was measured with a bite force meter. The measurements were repeated 3 times (with 2-minute intervals between times) for each side, and the highest value of the MBF was recorded for each side. OHRQoL was evaluated using the OHIP-14.

Results: The results revealed that patients with implant-supported fixed dentures exhibited higher bite force values (82 N) compared to those with complete dentures (57 N). However, these values were lower than the bite force values observed in dentate patients (176 N). Additionally, the study found that patients with fixed implant-supported prostheses experienced an improvement in OHRQoL.

Conclusion: The findings from this pilot study suggest that implant-supported fixed dental prostheses contribute to an increase in MBF and have a positive impact on OHRQoL. These results highlight the effectiveness of implant-supported fixed prosthesis treatment in patients with partial tooth loss.

Keywords: dental implants, implant-supported fixed prostheses, maximum bite force, quality of life

Correspondence: Şevval OKSUZ, Eskişehir Osmangazi University, Faculty of Dentistry, Department of Prosthodontics, Eskişehir, Türkiye, sevvaldurmus07@gmail.com.

Accuracy of Full-Arch Implant Prosthesis, Utilizing a Reverse Scan Body in a Complete Digital Workflow

Panagiotis Ntovas,¹ Konstantinos Chochlidakis,² Armand Bedrossian,³ Panos Papaspyridakos¹

(¹Tufts University School of Dental Medicine, Boston, Massachusetts, USA; ²Eastman Institute for Oral Health, University of Rochester, Rochester, New York, USA; ³University of Washington, Seattle, Washington, USA)

Objectives: To evaluate the accuracy of a complete digital workflow utilizing a novel reverse prosthetic scan body, implementing different scan patterns.

Materials and methods: A mandibular cast with 4 multi-unit abutment implant analogs (Screw-Retained Abutments) with adequate antero-posterior spread simulated a common clinical patient situation. This cast served as the master cast and an interim screw-retained prosthesis was fabricated on it. Novel reverse scan bodies were connected to the interim prosthesis and extra-oral scanning was performed with an intraoral scanner and 3 different scan patterns: starting from the occlusal surface of the interim prosthesis (O – group 1), starting from the intaglio (I – group 2), and helix pattern (H – group 3). The produced STL files from the 3 groups were then imported to a computer-assisted design (CAD) software (exocad) and after the digital design, the STL file was exported to a computer-assisted machining (CAM) milling machine generating in total 15 milled prosthesis prototypes per group. Two clinicians assessed the

accuracy of fit of each digitally fabricated prosthesis prototype on the master cast, utilizing a screw-resistance test and a subsequent radiographic evaluation. The Fisher's exact test was used to test the difference between the 3 groups.

Results: Out of the 3 different groups, O group scan pattern led to 100% accuracy of fit, while the prototypes generated from I and H groups led to 80% and 53% accuracy of fit.

The results were statistically significant ($P=0.008$).

Conclusions: Occlusal scan pattern leads to accurately fitting milled prosthesis prototypes after the extra-oral scanning of the interim prosthesis with reverse scan bodies, without intraoral implant data acquisition. Scan pattern has a significant effect in the accuracy of the fit of the full-arch implant supported milled prosthesis prototypes.

Keywords: Digital workflow, Scan Body, Full-arch prosthesis, implant-supported restoration, provisional prosthesis

Clinical Evaluation of the Agreement Between Virtual and Clinical Occlusal Registrations: A Comparative Clinical Study

Ameer Biadsee, Ameen Biadsee, Ayman Khalifa, Tarek Mtanis, Zeev Ormianer

(Tel Aviv University, Tel Aviv, Israel)

Objective: The purpose of this clinical study was to provide an evaluation of the agreement between the virtual occlusal scheme designed by a computer-aided design and computer-aided manufacturing (CAD-CAM) software program, and the occlusal scheme obtained clinically on the definitive prosthesis assessed with articulating paper.

Materials and methods: The virtual occlusal scheme design of 20 single monolithic crowns and their adjacent teeth were obtained using an intraoral scanning system (IOS) in 17 participants. These registrations were compared with conventional occlusal records obtained by articulating paper applied in 2 stages: first with 200- μ m blue film and the second with 12- μ m metallic red articulation tape. The analysis included both the quantity and the quality of the contacts of the conventional occlusal records referred to as the standard method. For accuracy analysis, virtual record sensitivity was calculated per crown as the percentage of true positive virtual contacts of the actual contacts identified by articulating paper.

Results: The virtual record sensitivity was 98.5 (95% confidence interval 96 to 100) for the crowns and 95 (95% confidence interval 85 to 100) for the adjacent teeth. The virtual record specificity was 88.6 (95% confidence interval 82.4 to 94.8) for the crowns and 82.6 (95% confidence interval 77.5 to 87.6) for the adjacent teeth. The agreement between the clinical and virtual contact intensities on the crowns was 83 (95% confidence interval 73 to 93) and 67.3 (95% confidence interval 56 to 78.7) for the adjacent teeth. The positive predictive value was 72.83 (95% confidence interval 60 to 86). The negative predictive value was 100% (95% confidence interval 100 to 100).

Conclusions: The intraoral scanning system provided clinically sufficient sensitivity and specificity for identifying occlusal surface contacts of monolithic crowns. A slight decrease was detected in the system's sensitivity and specificity identifying contacts on adjacent teeth.

Keywords: CAD-CAM, Virtual design, Interocclusal record

Evaluation of Trueness of 3D-Printed Custom Open Trays for Single Implant Impressions

Nursena Öztemel, Münir Demirel, Almira Ada Diken Türksayar

(Biruni University, İstanbul, Turkey)

Objectives: The aim of this study was to compare the accuracy of open custom trays produced with 3D printers and conventional methods.

Materials and Methods: A fabricated model, featuring an implant of the left lower molar tooth, was used in this study. An impression coping from the same manufacturer was attached to the implant and scanned by using high-accuracy industrial scanner (Atos Core 80) to obtain a reference scan. For first group, eight conventional custom open trays were fabricated using a light-cured base plate (Arasta Lc) with a 2 mm layer of wax (Great Dental Wax) applied to the model. For second group, eight custom open trays were produced through a 3D printer (Primeprint, Dentsply Sirona) through a dental design program (InLab SW, Dentsply Sirona). A total of 16 impressions were taken from the models in which impression copings were placed by using additional silicone impression material (Elite HD+, Zhermack SpA). Afterwards, the analogues were placed in the impression and plaster models were obtained. All of

the models were scanned with a laboratory scanner (InEos X5, Dentsply Sirona). The digitally obtained STL (D-STL) data and conventionally obtained STL (C-STL) data were evaluated as two separate groups. Trueness values were obtained by measuring the deviation of each group from the reference model. Independent t test was used to compare results between two tested groups. ($\alpha=.05$)

Results: Compared to the reference model, the D-STL group (43.25 ± 8.18) demonstrated a statistically significant closer proximity to the reference model than the C-STL group (67.75 ± 8.54). ($p<.001$)

Conclusion: Within the limitations of this study, the findings suggest that 3D-printed custom open trays have promising accuracy for single implant impressions. Further research is warranted to validate these results and explore the potential benefits of utilizing this technology in clinical practice.

Keywords: 3D printing, dental impression, implant dentistry, accuracy, impression tray

Effect of Mechanical Polishing on Surface Roughness of Chairside Lithium Disilicate Based Glass Ceramics

Jonathan Can Atalay, Pinar Turkoglu

(Istanbul Aydin University, İstanbul, Turkey)

Objectives: To investigate the surface roughness of nano-lithium disilicate glass-ceramics, immediately after milling and following different chairside finishing procedures.

Materials and methods: One hundred and twenty flat samples ($1.2\text{mm} \times 1\text{mm}$) were produced from three different novel lithium disilicate based CAD/CAM materials (IPS e.max CAD, Amber Mill, Amber Mill Direct) and divided into three groups ($n=10/\text{group}$) and treated as follows: Group 1, no polishing; Group 2, polishing with Ivoclar OptraFine; and Group 3; polishing with Ivoclar Optrafine using Amber Mill Glow polishing paste, Group 4; Glazing. Polishing was performed using a Kavo adjustable slow speed electric contra-angle handpiece. The influence of different finishing procedures was examined by comparing surface roughness (R_a , R_{max}) data for three groups using a benchtop stylus profilometer. Statistical analysis was performed with a one-way analysis of variance (ANOVA) and Tukey's HSD post-hoc tests ($\alpha=.05$).

Results: The smallest surface roughness values were found for Amber Mill Direct group samples. Polishing with and without paste significantly reduced the surface roughness compared with the non-polished control groups ($1.15 \mu\text{m}$). Group 4 exhibited the smoothest surface with $0.09 \mu\text{m}$, followed by group 3 with $0.14 \mu\text{m}$, and group 2 with 0.19 . Using novel polishing paste significantly helped to increase the surface smoothness similar to glazing procedure.

Conclusions: Polishing after milling or occlusal adjustment is essential in order to obtain the optimal clinical performance. Chairside polishing following grinding and adjustment with discs and polishing paste leads to comparably smooth surfaces as labside glazing procedure.

Keywords: Polishing, Surface Roughness, Lithium disilicate, CAD/CAM, Ceramic.

Comparative Performance Analysis of two Deep-Learning Training Approaches using a Panoramic Radiograph Multiclass Dataset

Bonfanti-Gris M.¹, Alonso-Calvo R.², Paraíso-Medina S.², Pradies G.

(¹Faculty of Dentistry, Complutense University of Madrid, Plaza de Ramón y Cajal S/N. 28040, Madrid, Spain; ²Faculty of Software Engineering, Polytechnic University of Madrid, Campus Montegancedo, 28660. Boadilla del Monte, Madrid, Spain)

Objectives: To compare the diagnostic performance of a Deep-Learning Convolutional Neural Network (DL-CNN) in terms of object detection and segmentation following two different training approaches.

Material and Methods: A total of 300 orthopantomographies (OPGs) were randomly selected for this study. To establish ground truth, images were manually annotated by a single previously trained and calibrated operator using an Artificial Intelligence training tool (COCO Annotator v.11.0.1). Annotating classes included: maxilla, mandible, maxillary sinus, inferior alveolar nerve, tooth, both plastic and metallic restorations, crowns and pontics, root canal treatments and implants. The full dataset was divided into training and validation subsets and were used to train the same neural network for object detection (YOLOv5 Small) and segmentation (YOACT ++) following two different approaches: a) including all annotated classes at once (AC) and b) separating tooth classes (TO) from the rest (RC). Validation-phase performance analysis for object detection was calculated using Mean Average Precision (mAP)

at two confidence levels intervals (0-0.5 and 0.5-0.95), F1 Curve and Confusion Matrix. For object segmentation, instead, only mAP at both before-mentioned intervals was calculated for task performance evaluation.

Results: Object Detection mAPs (0-0.5 and 0.5-0.95) for both first and second training strategies were as follows: AC mAP (0-0.5)=0.36, AC mAP (0.5-0.95)=0.22; TO mAP (0-0.5)=0.99, TO mAP (0.5-0.95)=0.67; RC mAP (0-0.5)=0.65, RC mAP (0.5-0.95)=0.39. Object Segmentation mAPs for both first and second training strategies were as follows: AC mAP (0-0.5)=0.34, AC mAP (0.5-0.95)=0.19; TO mAP (0-0.5)=0.38, TO mAP (0.5-0.95)=0.16; RC mAP (0-0.5)=0.30, RC mAP (0.5-0.95)=0.16.

Conclusions: Second training strategy described in this study should be considered for achieving better results in object detection tasks. For object segmentation, albeit more training data is needed in order to increase software's precision, first training approach seems to be the best choice in case of developing a DL-CNN for diagnostic purposes.

Flexural Strength Assessment of Two 3D Printing Resins for Permanent Restorations: An *In Vitro* Study

Riccardo Favero

(University of Padua)

Objectives: The aim of the present study is to evaluate the flexural strength of two 3d printed dental resins which have indication for permanent restorations after receiving stress from a simulated oral condition.

Materials and methods: Forty specimens of dimensions (2522 mm) were printed. Twenty samples were printed by using VarseoSmile Crown plus (V) and other twenty were printed by using Crowntec (C). All samples were left into distilled water at 371°C for thirty days in a temperature-controlled room. Then the three-point bending test was carried out using an universal test machine. The maximum loading, flexural strength at maximum loading and modulus (E-modulus) were recorded.

Results: Maximum loading at fracture (mean DS N) of each group was 22,95391 3,26307 for VarseoSmile Crown plus, 18,11244 2,27390 for Crowntec. Flexural strength at max

(mean DS MPa) of VarseoSmile Crown plus was 97,51101 15,19526, Crowntec 94,17018 11,76822. Modulus (mean DS MPa) was 3.716,80214 165.62493 for VarseoSmile Crown plus and 4.020,18442 348.51056. One-way ANOVA with Tamhane *post hoc* test showed that the difference of flexural strength of two test groups was not statistically significant ($P > .01$).

Conclusions: Mechanical Properties of two 3d printing resins are similar and the differences are not statistically significant. Comparing flexural strength of the resins, although Crowntec recorded lower flexural strength values, the modulus values are higher, meaning that the material is more plastic.

Keywords: flexural strength, 3d printing, resins, permanent restorations

The Evaluation of Different Oral Scanners by Measuring the Post Cavity

Tarik İlhan DDS; Assist. Prof. Bora Akat , PhD, DDS; Professor Mehmet Ali Kılıçarslan, PhD, DDS

(Ankara University, Faculty of Dentistry, Department of Prosthodontics, Ankara, Turkey)

Objective: The scanning depth of different intra oral scanners were evaluated in measuring different post cavity depths.

Material and method: 5 typodont maxillar first premolar teeth were prepared to following post cavity depths, 2 mm, 4 mm and 6 mm. For each depth, 2 different intra oral scanner were performed per 15 times. The groups are as follows: Group 1: 2 mm depth scanned by omnicam (OM2), Group 2: 2 mm depth scanned by trishape trios 4 (TR2), Group3: 4 mm depth scanned by ommicam (OM4), Group 4 : 4mm depth scanned by trishape trios 4 (TR4), Group 5: 6mm depth scanned by ommican (OM6) , Group 6 : 6mm depth scanned by trishape trios4 (TR6). Afterwards, captions of scanned areas were measured by using Microsoft paint programme. All data were analyzed statistically.

Result: Depth of post cavity ere compared between groups for each depth. The values of TR2 group were significantly higher than values of OM2.The values of TR4 group were significantly higher than values of OM4.The values of TR6 group were significantly higher than values of OM6. ($p < 0.05$)

Conclusion: In the study, it is demonstrated that different intra oral scanners were performed different measurement. On the other hand, acrylic resin teeth can show various scanning properties. Further studies are needed by studying extracted teeth and scanned by more oral scanners.

Keywords: post cavity, post core, oral scanners, scanning depth, digital dentistry,

POSTERS ABSTRACTS

Comparison of Fracture Patterns and Resistance of Endodontically Treated Molars, Restored With Lithium Disilicate or Composite Overlays and Endocrowns

Sintija Miļuna-Meldere¹, Baiba Sprīģe¹, Evaggelia Papia²

(¹Department of Prosthetic Dentistry, Rīga Stradiņš University, Riga, Latvia; ²Department of Materials science and Technology, Faculty of Odontology, Malmö University, Malmö, Sweden)

Objectives: Besides the conventional crown, which demands invasive tooth preparation, overlay and endocrown allows a less invasive approach to cover weakened tooth cusps, avoiding catastrophic tooth fracture. The aim of this study was to evaluate the fracture resistance and fracture patterns of endodontically treated molar teeth, restored with ceramic and composite overlays and endocrowns.

Materials and methods: In this prospective rare case of allergy to alginate impression material active cross-sectional in vitro study 40 extracted human molars were included (An Ethics approval Nr. 22-2/94/2021). Teeth were divided into 4 groups: composite core build up with pressed lithium disilicate overlay (n=10); composite core build up with milled composite overlay (n=10); pressed lithium disilicate endocrown without composite build up (n=10); milled composite endocrown without composite build up (n=10). According to a certain treatment protocol for each group the following treatment was performed: root canal treatment, composite core build up (if necessary), tooth

preparation, cementation of restorations. Then the specimens underwent thermocycling (10000 cycles, 5°-55° C) for 7 days, mechanical cyclic loading (0-50 N, 1.6 Hz, 600000 cycles in 100 slope) for 7 days, and again thermocycling as described before. After preloading, the specimens were subjected to a fracture strength test (5 mm steel ball, 10° inclination, load rate 0.5 mm/min).

Results: All the specimens fractured after mechanical loading (fracture of restoration, n=14 ; fracture of tooth, n=26). Teeth restored with both material overlays did not have fractures escalating from restoration to enamel, dentin and cement simultaneously. Catastrophic tooth fractures were seen in teeth restored with both material endocrowns.

Conclusions: Teeth restored with endocrowns presented catastrophic fracture patterns therefore could not be restorable. Teeth restored with overlays and especially lithium disilicate overlays are the best choice for restoring endodontically treated molars.

Effect of Two Different Cement Residue Removal Techniques on Marginal Discolouration *In Vitro*

Mara Gaile¹, Evaggelia Papia², Vita Zalite³, Janis Locs³, Una Soboleva¹

(¹Riga Stradins University, Latvia; ²Malmö University, Sweden; ³Riga Technical University, Latvia)

Objective: Margin discolouration is a common problem for veneers in the long term therefore it is essential to understand the optimal cementation protocol to minimise it. The objective of this study was to compare the intensity of discolouration for adhesively cemented veneers when using two cement removal techniques.

Materials and Methods: Twenty premolars were prepared similarly: 0.5 mm deep, rounded corners, chamfer finish line, borders in enamel. Ceramic (IPS e.max CAD) veneers were made using a scanner Ceramill Map 600 and mill Ceramill Motion 2. The cement gap was 0.02 mm. PANAVIA V5 (Kuraray, Noritake) cement was used. Teeth were divided into two groups. For the first group (n = 10) cement excess was removed with a probe after 3 – 5 seconds of polymerisation continuing to complete polymerisation. For the second group (n = 10) excess was removed with a brush, then completely polymerised. Teeth were stored in alginate gel. Micro-CT was used to detect cementation defects, then teeth were coloured and examined under a stereomicroscope. Discolouration depth was scored

0 (no discolouration) to 5 (discolouration along the entire margin). The difference in the distribution of discolouration between groups was assessed using Fischer exact test.

Results: After colouring 55% of the specimens in the probe group exhibited extensive discolouration. In the brush group 90% exhibited slight discolouration (p = 0.008). Defect quantity analysis did not show statistically significant connection between the number of defects and the depth of discolouration.

Discussion and Conclusions: There have been studies on the effect of different bonding techniques on microleakage however different cement removal techniques have not been investigated. In this study cement removal with a brush showed less discolouration than removal with a probe. Future studies should analyse the types of defects more deeply to find the cause determining the difference in discolouration intensities.

Keywords: porcelain veneers, adhesive cementation, discolouration

Effect of Treatment With Fixed Implant-Supported Prostheses in Patients With a Shortened Dental Arch

Takumi Yokoi, Yuriko Kusumoto, Yuka Abe, Minoru Sanda, Sawako Yokoyama, Kazuyoshi Baba

(Department of Prosthodontics, Showa University School of Dentistry, Tokyo, Japan)

Purpose: The purpose of this study was to investigate the impact of treatment with fixed implant-supported prostheses on oral health-related quality of life (OHRQoL), masticatory performance, and bite force in patients with a shortened dental arch.

Materials and methods: Forty patients who had unilaterally lost either the second molar or both the first and second molars on one of their jaws and were seeking treatment with fixed implant-supported prostheses were included in this study. The patients were divided into three groups based on the number of missing teeth and implant-supported prostheses (Figure 1, Groups 1–3). The Japanese version of the Oral Health Impact Profile (OHIP-J) was used to assess the impairment of OHRQoL, whose dimension scores were calculated for oral function, orofacial pain, orofacial appearance, and psychosocial impact. Masticatory performance was determined by the gummy jelly method, and bite force was measured using pressure-sensitive films. Evaluations were performed before the implant surgery (T1) and one month after the delivery of the final prostheses (T2), and changes in T1 to T2 were calculated. The Kruskal-Wallis test was used for between-group comparisons, while the

Mann-Whitney U test was used for within-group comparisons. The significance level was set at 0.05.

Results: No significant differences were found in between-group comparisons. Within-group comparisons showed statistically significant improvements after treatment in several OHIP-J items for Groups 1 and 3: oral function (p = 0.007); orofacial appearance (p = 0.006); and orofacial pain (p = 0.046) in Group 1, and oral function (p = 0.039) in Group 3.

Conclusions: Within the framework of this study, treatment with fixed implant-supported prostheses for patients with a shortened dental arch may lead to better patient-reported outcomes; however, the impact of the number of missing teeth and implant-supported prostheses may be minimal in cases with one or two missing teeth.

Keywords: Dental Implants, Patient Reported Outcome Measures, Mastication

This study was supported by the KAKENHI Grant-in-Aid for Scientific Research B (21K09986 and 21K10010) from the Japan Society for the Promotion of Science.

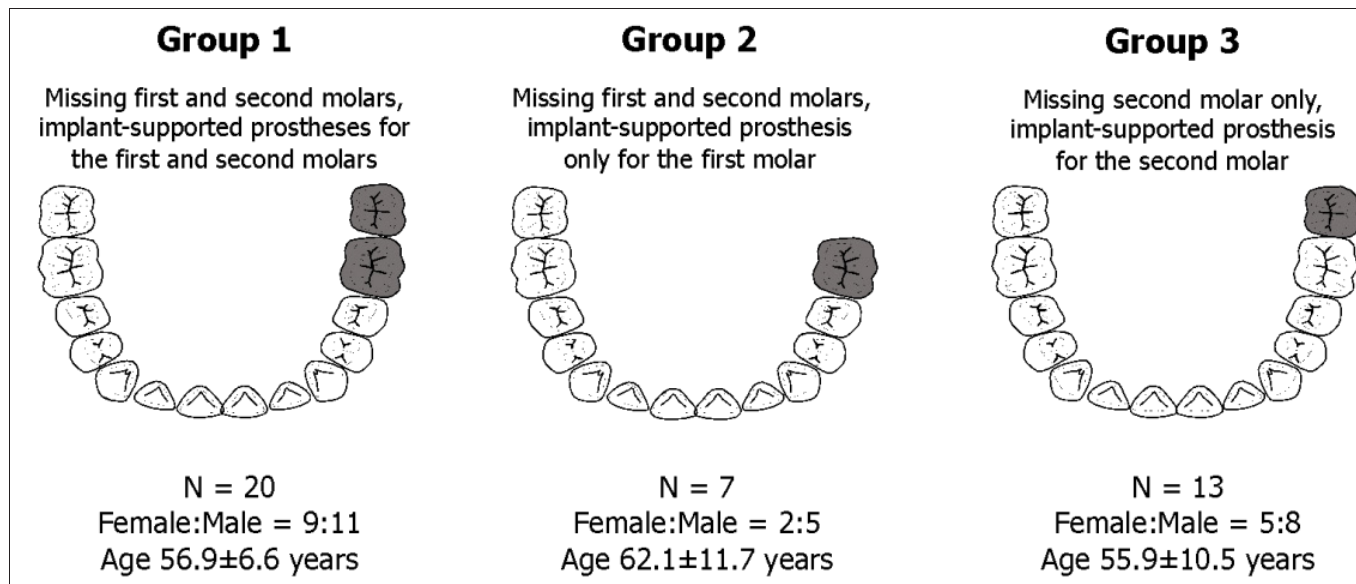


Figure 1: Grouping by the number of missing teeth and implant-supported prostheses.

The Influence of Cement on the Outcome of Zirconia-Based Crowns — A Systematic Review and Meta-Analysis

Minh Le, PhD-student, DDS¹, Evaggelia Papia, PhD, DT¹, Per-Erik Isberg, Senior Lecturer², Christel Larsson, PhD, DDS^{1,3}

(¹Faculty of Odontology, Malmö University, Malmö, Sweden; ²School of Economics and Management, Lund University, Lund, Sweden; ³Riga Stradins University, Riga, Latvia)

Objectives: This study aimed to evaluate the clinical outcome of tooth-supported posterior zirconia-based single crowns (SCs) cemented with different cement systems.

Material and methods: An electronic search was conducted in four databases (PubMed, Web of Science, Scopus, and Google Scholar). In addition, the reference lists of the included studies were manually assessed. Clinical studies reporting on tooth-supported zirconia-based restorations with a mean follow-up time of at least three years were included. All selected articles were prospective clinical trials. A meta-analysis was conducted on data obtained by using random effect models to calculate survival of SCs using different types of cement systems. The risk of bias of all included studies was assessed. All statistical analyses were conducted using the software R (R Core Team 2021).

Results: The electronic search yielded 2,445 studies. After assessment and limiting data analysis to only posterior SCs, the

number of included studies was 16. A total of 1,203 posterior zirconia SCs were evaluated. The mean follow-up time ranged from three to five years. The meta-analysis indicated no statistically significant differences in survival between adhesively cemented SCs (98.7%) and those cemented with glass-ionomer (99.0%) or resin-modified glass-ionomer (98.7%) after three years. The most common clinical complications were fracture of the veneering ceramic, loss of retention, and endodontic problems.

Conclusions: Clinical outcomes of posterior zirconia SCs exhibited an excellent short-term survival rate, regardless of whether the cement is a resin cement, glass-ionomer cement, or resin-modified glass-ionomer cement.

Keywords: ceramics, crowns, meta-analysis, survival, zirconia

Trueness and Precision of 2 Different Intraoral Scanners in Implant Fixed Prosthodontics: A Comprative *In Vitro* Study

Ebrahim Ahmad Alhassan, Casucci Alessio, Nosrati Nadia, Verniani Giulia, Ferrari Marco

(Unit of Prosthodontics, University of Siena, Siena, Italy)

Objectives: To test differences in term of trueness and precision among two different Intraoral Scanners (IOSs) used in implant fixed prosthodontics.

Materials: A reference stone model was prepared, representing a partially edentulous maxilla on area #23 and from #14 to #16, with three implant analogues and polyether-ether-ketone (PEEK) scanbody screwed on to represent the situation of a single crown on implant (#23) and a implant-supported partial prosthesis (#14, #16). The model was digitized with an laboratory scanner (Aadva lab scanner, GC, Tokyo, Japan) used as a reference, and with two intraoral scanners (Trios 3; 3Shape A/S; I700, Medit). Ten scans were taken using the two different IOS. All datasets were loaded into reverse-engineering software (Geomagic Control X 2018), where intraoral scans were superimposed on the reference model, to evaluate trueness in the full arch, in the single scanbody area (#23) and in the two scanbody area

(#14 and #16). Therefore, all the scans of the same group were superimposed onto the cast that recorded the best result of trueness whose trueness corresponded to the actual reference value for precision. Non-parametric Kolmogorov-Smirnov test was performed (SPSS software Version 26, IBM). Kruskal-Wallis non-parametric test with independent samples and Bonferroni correction was applied to non-normally distributed samples. Statistically significative was set at 0.05.

Results: No statistically significative differences where found between Medit i700 and TRIOS 3.

Conclusions: With in the limits of the present study the accuracy of the two scanner evaluated did not report statistical significative differences neither for single than bridge prosthodontics. More experimental evaluations are recommended in order to validate clinically IOs in implanting prosthodontics.

	TRUENESS FULL ARCH (μm)	PRECISION FULL ARCH (μm)	TRUENESS 2 SCANBODIES (μm)	PRECISION 2 SCANBODIES (μm)	TRUENESS 1 SCANBODY (μm)	PRECISION 1 SCANBODY (μm)
TRIOS	29.8±4.05	55±7.19	55.2±3.47	28.2±12.26	44.1±44.1	17.7±5.39
MEDIT i700	40.9±7.18	60.2±7.08	52.3±4.34	50.9±19.85	40.4±15.97	16.8±6.38

Bond Strength of Resin Cement to Monolithic Zirconia Decontaminated With Different Cleaning Methods

Ioannis Papathanasiou, Dimitrios Kolovos, Kyriaki Hadjichambi, Phophi Kamposiora, George Papavasiliou, Spiridon Silvestros

(National and Kapodistrian University of Athens, Athens, Greece)

Objectives: To investigate the effect of different cleaning methods on the bond strength of resin cement to saliva-contaminated zirconia.

Materials and methods: Thirty disk-shaped zirconia specimens (Zenostar MO, Ivoclar Vivadent AG, Liechtenstein) were prepared and immersed in human saliva for 60 seconds. The specimens were randomly assigned into three groups (n= 10/group) corresponding to different cleaning methods; water-spray rinsing (control group CG), ultrasonic cleaner for 3 min (UL) and Ivoclean (IV) cleaning solution (Ivoclar Vivadent AG). Silanes were applied (Monobond Plus, Ivoclar Vivadent AG) and dried with oil-free air. Cylindrical molds were placed over the treated surfaces, filled with dual-cured resin cement (Speedcem Plus, Ivoclar Vivadent AG) and light-cured for 30s. All specimens were subjected to water thermocycling (5000 cycles, 5-55°C, 30s dwell time, ISO TR 11450) and finally debonded under shear loading, applied at the zirconia-

composite interface with the notched-edge blade method using a universal testing machine (Tensometer 10, Monsanto, Swindon, UK) at 1.0mm/min crosshead speed. The results of the shear bond strength (SBS) were expressed in MPa (N/mm²) by dividing the force at break by the nominal bonding surface area of the specimens. SBS results were statistically analyzed by one-way ANOVA and Tukey *post hoc* tests (α=0.05).

Results: SBS after decontamination with Ivoclean (20.72±20.21 Mpa) was significantly higher than UL (16.02±4.83 MPa) and CG groups (14.84±7.71 MPa). No significant differences were found between UL and CG.

Conclusions: Ivoclean can be an effective cleaning method to improve the bond strength of resin to contaminated zirconia.

Keywords: bond strength; contamination; zirconia bonding; zirconia cleaning; saliva

Analysis of Occlusal Contacts Recorded with Intraoral Scanner in Patients with Juvenile Idiopathic Arthritis

Zinaida Zhehulovych, Leonid Etnis, Renata Symonenko, Nina Proshchenko

(Bogomolets National Medical University, Kyiv, Ukraine)

Objectives: to analyze occlusal contacts in young patients with juvenile idiopathic arthritis in comparison with young adults without arthritis.

Materials and methods: 21 young patients with diagnosis of juvenile idiopathic arthritis (according to ILAR criteria) aged from 18 to 34 years (mean age 23.14 ± 4.01) who included 12 females and 9 males (research group) and 20 young adults without arthritis aged from 18 to 35 years (mean age 24.05 ± 4.77) who included 10 females and 10 males (comparison group) were examined at Dental Medical Center of Bogomolets National Medical University. Intraoral scans of the jaws and bite records were obtained with Medit i500 intraoral scanner. Presence of premature contacts was checked in maximal intercuspal position as well as during protrusion and laterotrusion. Bite class according to Angle's classification was also estimated.

Results: Within the research group 5 patients (23.8%) had premature contacts in maximal intercuspal position, 6

patients (28.6%) – during protrusion and 7 patients (33.3%) – during laterotrusion; 10 patients (47.6%) had I class bite, 7 patients (33.3%) – II class bite, 4 patients (19.1%) – III class bite; Within the comparison group 3 patients (15%) had premature contacts in maximal intercuspal position, 3 patients (15%) – during protrusion and 4 patients (20%) – during laterotrusion; 12 patients (60%) had I class bite, 6 patients (30%) – II class bite, 2 patients (10%) – III class bite.

Conclusions: higher level of premature contacts as well as malocclusion prevalence were revealed in young patients with juvenile idiopathic arthritis in comparison with young adults without arthritis. That's why such patients may need proper occlusal correction to prevent further temporomandibular disorders development.

Keywords: dental occlusion, bite registration, canine guidance, malocclusion, juvenile arthritis.

The authors declare the absence of any conflict of interest.

An In Vitro 3-Dimensional Comparative Analysis of Four Intra-Oral Scanning Devices in Vertical Preparation For Fixed Dental Prosthesis

Ricci Nicolò Maria, Verniani Giulia, Habib Ralph, Casucci Alessio, Ferrari Marco

(Unit of Prosthodontics, University of Siena, Siena, Italy)

Objectives: To test differences in term of trueness and precision among the different Intraoral scanners (IOSs) in scanning a vertical preparation on natural teeth.

Materials: A reference maxillary typodont (RT) was fabricated by performing a vertical preparation with knife edge finish line for full crown on #16 and #21. The RT was scanned with a laboratory scanner (Aadva lab scanner, GC, Tokyo, Japan) to obtain a digital reference typodont (dRT) in .stl format file. A group of 40 digital casts (dIOC) were obtained by scanning the RT 10 times with four different IOSs (Trios 3; 3Shape A/ S), (I700, Medit), (Vivascan; Ivoclar), (Aadva IOS200, GC). All the obtained dIOC were imported into an inspection software program (Geomagic Control X; 3D SYSTEMS) to be superimposed to the dRT, to calculate trueness. Therefore, in order to calculate precision all the scans of the same scanner group were superimposed onto the cast that recorded the best result of trueness. Results were collected as root mean square value (RMS) on #16 and #21 abutment surfaces. The obtained data were evaluated with Kolmogorov-Smirnov for

normal distribution. A nonparametric analysis Kruskal-Wallis test was performed to compare the RMS values obtained in the different iOS groups for trueness and precision. Statistically significant was set at 0.05.

Results: Table 1: The mean values and standard deviations of each scanner regarding the trueness and precision on the prepared abutments. Letters reported the statistical significant differences in between the groups $P < 0.05$

IOS	Trueness M	Trueness I	Precision M	Precision I
Trios 3	$60,2 \pm 4,9^a$	$68,7 \pm 4,0^b$	$31,7 \pm 13,1^b$	$18,0 \pm 2,7^a$
I700	$58,0 \pm 8,9^a$	$83,3 \pm 5,1^c$	$15,8 \pm 2,7^a$	$29,8 \pm 3,7^b$
Vivascan	$69,6 \pm 6,9^a$	$56,0 \pm 12,1^a$	$41,4 \pm 20,2^c$	$49,9 \pm 19,6^c$
Aadva 200	$55,4 \pm 5,6^a$	$59,2 \pm 2,7^a$	$10,7 \pm 2,1^a$	$16,9 \pm 13,8^a$

Conclusions: With in the limits of the present study, it can be concluded that in vertical prepared teeth the trueness obtained using different scanners differ with statistical significance only in the incisor abutment, Aadva scanner resulted as the most precise in both M and I abutments.

The Influence of the Mucosa Thickness and Implant Number on the Peri-Implant Bone Strain

Ines Kovačić¹, Nikola Petričević¹, Josip Kranjčić^{2,3}, Asja Čelebić¹

¹Department of Removable Prosthodontics, School of Dental Medicine, University of Zagreb, Croatia; ²Department of Fixed Prosthodontics, School of Dental Medicine, University of Zagreb, Croatia; ³Clinical Department of Prosthodontics, Clinical Hospital Dubrava, Zagreb, Croatia)

Purpose: Mini dental implants (MDI) supported dentures have become popular therapeutic option for very resorbed edentulous mandibles. Increased strain in the peri-implant bone can lead to microfractures and bone resorption. The aim of this study was to investigate the strain of the peri-implant bone around Straumann® Mini Implants from Roxolid® alloy in relation to their number and mucosa thickness.

Materials and methods: Eight mandible models were 3D printed based on a CBCT scan. One, two, three or four MDIs made of Roxolid® alloy (Ti85Zr15) were inserted into the designated sites in the interforaminal space of each model and artificial mucosa from polyvinyl siloxane in 2 mm and 4 mm thickness was created. Strain gauges were placed to the vestibular and the oral peri-implant region to each MDI. Overdentures were manufactured for each model and loaded with forces of 50, 100 and 150 N bilaterally, unilaterally in

the right molar region and frontally. Peri-implant strain was recorded for each force using strain gauges and computer analysis in the appropriate software program.

Results: There was a significant difference depending on the load location, the increase in force, and different mucosa thickness ($p < 0.001$). In general, as the force applied to the overdenture increased, so did the strain in the peri-implant bone. The average vestibular, oral and average strains around the MDIs showed a tendency to decrease with increasing the number of MDIs and mucosa thickness (4 mm) ($p < 0.01$).

Conclusion: Thicker mucosa ensures a greater transfer of force to the mucosa and lower peri-implant strain while four MDIs represent the optimal number of implants to support an overdenture in terms of peri-implant bone strain.

Keywords: mini dental implants, Roxolid®, overdenture, peri-implant strain

Accuracy of Two Intra-Oral Optical Scanners in Scanning Horizontal Preparations on Abutments

D'Arienzo Luigi, Casucci Alessio, Ferrero Eleonora, Verniani Giulia, Ferrari Marco

(Unit of Prosthodontics, University of Siena, Siena, Italy)

Objectives: to test differences in term of trueness and precision among two different IOSs in scanning a chamfer and a shoulder preparation on natural teeth.

Materials: A reference maxillary typodont with exchangeable teeth was prepared first with teeth #16 and #21 prepared with chamfer finish line and then with teeth #16 and #21 prepared with a shoulder finish line. Both models were scanned with a laboratory scanner (Adva lab scanner, GC, Tokyo, Japan) to obtain two digital reference typodont in .stl format. Forty digital IOS casts were obtained by scanning the models 10 times by each of the two different IOSs (Trios 3; 3Shape A/S and I700, Medit). All the STL files were imported into an inspection software program (Geomagic Control X; 3D SYSTEMS) to be superimposed with the reference model acquired with the

laboratory scanner to calculate trueness. Therefore, all the scans of the same group were superimposed onto the cast that recorded the best result of trueness whose trueness corresponded to the actual reference value for precision. The accuracy was evaluated with root mean square value (RMS) in the #16 and #21 areas. Kolmogorov-Smirnov was applied to test normal distribution. The nonparametric Kruskal-Wallis test was performed to compare the trueness and precision. Statistically significant was set at 0.05.

Results: No statistically significant difference was found between Medit i700 and TRIOS 3 shape regarding trueness or precision for both #16 and #21 prepared teeth.

Conclusions: The two evaluated scanner reported similar accuracy performance in case of horizontal preparations.

Age-Related Associations of Gene Polymorphisms in Individuals With Periodontitis

Albertas Kriaučiūnas^{1*}, Gediminas Žekonis¹, Greta Gedvilaitė², Kristė Kaikarytė² and Rasa Liutkevičienė²

¹Department of Prosthodontics, Lithuanian University of Health Sciences, Sukilėlių Str. 51, LT-50106 Kaunas, Lithuania; ²Institute of Neuroscience, Lithuanian University of Health Sciences, Eivenių Str. 2, LT-50009 Kaunas, Lithuania. Contact Details: E-mail: albertas.kriauciunas@lsmuni.lt; Phone number: +370-689-68605)

Introduction: Periodontitis is a complex inflammatory disease associated with a dysbiotic biofilm and marked by progressive destruction of the periodontium. Understanding genetical mechanisms and gene polymorphisms with its functions in oral diseases such as periodontitis could be beneficial in preventing tooth loss and for future generations and therapeutic strategies. Recent advances in geroscience have shown that various biomarker signatures of biological aging are longitudinally associated with declined physical function, morbidity, and mortality due to major age-related diseases, including periodontitis.

The aim: Our study's objective was to investigate the associations between single-gene nucleotide polymorphisms (rs3818292, rs3758391, and rs7895833) in periodontitis patients according by age.

Methods: This study included 151 patients with generalised periodontitis and 381 individuals serving as controls. Blood was extracted for DNA using DNA administration kits. The

genotyping was conducted using rPCR. Using IBM SPSS Statistics, results were calculated.

Results: The analysis revealed that the polymorphism rs3818292 AA genotype was less common in the periodontitis group than in the control group (78.1% vs. 89.4%, $p = 0.001$), whereas the AG genotype was more common in patients over 60 years of age than in the control group (20.5% vs. 10.6%, $p = 0.003$). The periodontitis group had a higher frequency of the G allele than the control group (11.6% vs. 5.2%, $p = 0.001$). The genotype AA of polymorphism rs7895833 was less common in the periodontitis group than in the control group (64.2% versus 76.1%, $p = 0.006$), whereas the genotype AG was more common in the periodontitis group than in the control group (33.8% versus 22.1%, $p = 0.001$). In the periodontitis group, the G allele was more prevalent than in the control group ($p = 0.008$).

Conclusion: The genotypes and allele distributions of rs3818292 and rs7895833 differed significantly between the group of patients with periodontitis and the control group of patients older than 60 years.

A Digital Impression Technique to Transfer an Accurate Emergence Profile For Immediately Loaded Implant-Supported Restorations

Özge Nur Özbey, Fehmi Gönüldaş, Doğan Derya Öztaş

(Ankara University Faculty of Dentistry, Ankara, Turkey)

Introduction: Immediate loading protocols have some advantages such as protection of peri-implant tissues and meeting aesthetic expectations. Provisional restorations have the benefit of imitating the form of natural teeth. But reflecting the emergence profile to the final restoration can be difficult. Various methods have been described to transfer the emergence profile. As digital dentistry evolves, the use of digital workflows in implant-supported prosthesis impressions is increasing.

Case description: A young patient applied to our faculty due to crown destruction in her right upper first premolar tooth. After the examination, it was decided to extract the tooth. Immediate implant placement and immediate loading were planned. An acrylic provisional crown was loaded within 24 hours. After the completion of osseointegration and having an aesthetic emergence profile, the impression stage for final restoration was started. To transfer the emergence profile in the most accurate way and to avoid the collapse of gingiva, 3-stage

digital impression was preferred. In this method, the provisional crown was first scanned with an intraoral scanner followed by a second scan after removal of the crown. Finally, a third scan was made with a standard scan body and imported into the software. These three scans were combined in a CAD software for the final restoration. The restoration was designed as a screw-retained zirconia crown, preserving the emergence profile.

Discussion: Cylindrical structure of the impression posts is not sufficient for transferring the emergence profile to the impression, so it has been stated that modifications should be made in the impression posts. Although the peri-implant soft tissue can be captured by digital scanning, it begins to change right after the removal of restoration. In order to prevent this situation, the 3-stage digital impression method is thought to be a fast and successful approach for accurately transferring the emergence profile.

Keywords: Digital impression, emergence profile, immediate loading

Flexural Strength Analysis of Different Complete Denture Resin-Based Materials

Alessio Casucci

(University of Siena)

Objectives: To compare flexural strength of different complete denture resin-based materials obtained by analogic, 3d printed and milled protocols. To evaluate the effect of the post curing process on the Flexural strength in tinted resins.

Materials: One hundred sixty rectangular specimens (64 mm x 10 mm x 3,3 mm) were fabricated according to ISO-20795-1:2013 and divided in different groups according to the resin based material used. The printed resin materials were post cured with two protocols 20' and 40', thus two subgroups (n=10)

All the specimens were finished, polished, and tested in a three-point bending test apparatus until failure at

24 hours from the rehalization. Flexural strength data were statistically analyzed. ANOVA on Ranks was applied, followed by Bonferroni test for *post hoc* comparisons (P= 0.05).

Results: Flexural strength values (MPa) were measured (mean±standard deviation) And reported in Table 1.

Conclusions: Within the limitations of this study, both CAD-CAM milled Ivotion and AADVA discs showed higher flexural strength than analogic resins and can therefore be a suitable alternative for denture base. Flexural strength of

Table 1

Resin	Mean (MPa)	SD
ACRYPOL R	89,15	14,31
ACRYSELF P	86,07	7,093
ACRYSELF	74,83	7,84
ACRYPOL HI	85,58	8,60
ACRYPOL LL	92,39	17,18
ACRYPOL FAST	98,86	10,66
IVOTION	91,88	4,43
AADVA DISC	107,87	7,56
NEXTDENT LABO LIGHT 20"	60,11	5,72
NEXTDENT BB 40"	83,32	8,38
SPRINTRAY LABO LIGHT 20"	54,07	3,55
SPRINTRAY BB 40"	85,44	5,3
TEMP PRINT LABO LIGHT 20"	75,58	9,36
TEMP PRINT BB 40"	96,87	6,27
TEMP PRINT MOD PINK BB 40"	102,96	9,37
TEMP PRINT BB 20"	90,87	7,44

3D-printed acrylic resins showed differences according to the polymerization method used. The optimal polymerization technique was 40' polymerization using the BB-cure machine.

Customized Healing Abutment Delivery Immediately After Implant Placement: A Technique Presentation

Sarafianou Aspasia¹, Dimokritos Papalexopoulos², Theodora-Kalliopi Samartzi³, Maria Sykara⁴, Nikitas Sykaras¹

(¹Assistant Professor in Prosthodontics, National and Kapodistrian University of Athens, Athens, Greece; ²Post Graduate Student in Prosthodontics, National and Kapodistrian University of Athens, Athens, Greece; ³DDS, Athens, Greece; ⁴Post Graduate Student in Periodontology, National and Kapodistrian University of Athens, Athens, Greece)

Introduction: Having overcome the matter of implants longterm preservation in the oral cavity attention has shifted to the perfection of certain aspects connected to implant therapy. Periimplant emergence profile is one of them and according to literature proper contours support esthetic outcomes and provide favorable biological response to implant-supported restorations. The aim of this presentation is to describe step-by-step the technique applied to shape the periimplant emergence profile of an anterior implant.

Case description: A 57-year-old male patient presented to the Postgraduate Clinic of Prosthodontics in National and Kapodistrian University of Athens, Greece seeking dental rehabilitation. Clinical and radiographic examination revealed loss of tooth No. #11 and a tooth supported cantilever prosthesis supported by tooth No. #12. Due to periodontal, endodontic and restorative reasons, the tooth was characterized with poor prognosis and rehabilitation with a dental implant was proposed.

Before tooth extraction an impression was made for the fabrication of an interim Rochette bridge. Extraction took place along with GBR procedures. Six months later and after thorough examination of the CBCT an implant in the position No. #12 would be placed. Previously, the cast that was used for the fabrication of the interim prosthesis was modified so that the area replicating soft tissues of the right lateral incisor would be corresponding to that of the left lateral incisor regarding dimensions and shape.

An acrylic resin shell was prepared and the healing abutment was delivered via activation of a PEEK abutment intraorally, immediately after implant placement. Recall appointments assured the uneventful healing of periimplant tissues.

Discussion: Achievement of excellent results regarding white aesthetics of implant restorations has shifted attention towards pink aesthetics. Shaping a customized periimplant emergence profile not only enhances aesthetics of soft tissues but also yields favorable biological response to implant-supported restorations.

The Impact of Alcoholic Solutions on Polyacrylate Materials

Agnieszka Grażyńska-Graczyk¹, Szymon Rzątownski¹, Beata Czarnecka², Elżbieta Paszyńska¹

⁽¹⁾Department of Integrated Dentistry, Department of Practical Clinical Dentistry, Poznan University of Medical Sciences; ⁽²⁾Department of Biomaterials and Experimental Dentistry, Department of Conservative Dentistry, Endodontics and Biomaterials, Poznan University of Medical Sciences)

Introduction: PMMA (polymethylmethacrylate) is still widely used in denture fabrication. In daily denture hygiene, patients often use means that are not recommended by dentists, including those containing alcohol due to its disinfecting qualities. This study aimed to quantitatively describe the effect of denture disinfection in alcohol solutions on the physical parameters of the material.

Purpose: To evaluate the effect of alcoholic solutions with different percentages of ethanol on the

Material and Methods: 15 samples of fast-polymerizing (Duracryl Plus) and 15 samples of slow-polymerizing (Vertex Rapid Simplified) polyacrylate were made. The samples were then immersed in Listerine (21.6% ethanol), spirit (98% ethanol) and water, ISO grade 2, for 12, 24 hours, 1, 2, 4 weeks. After each removal from the solutions, the samples were weighed and their microhardness was examined under a microscope.

Results: After being placed in the solutions of the compounds, the weight of the test samples increased and the microhardness decreased. Faster solution saturation, and thus a faster increase in mass and decrease in microhardness, compared to initial values occurred for fast-polymeric polyacrylic in 98% ethanol. It changed mass by 40% after 24 hours and this value did not change in subsequent measurements.

For slow-polymerized polyacrylic, the weight change after 4 weeks was 43.7%. The percentage weight gain for 21.6% ethanol was less. In both alcohol solutions, the microhardness gradually decreased to values that could not be measured at the end. After drying, the samples permanently changed their dimensions.

Conclusions: Ethanol, which is an organic solvent, is a better solvent for polymers than water. Improper hygienic procedures involving too long exposure of the polymer in water and alcoholic solutions are associated with increased absorption of the solvent, which can affect the degradation of the internal structure of the material and reduce wear resistance.

Knowledge of Students Towards CAD-CAM Technology in Prosthodontics

Josip Kranjcic^{1,2}, Josip Vuksic^{1,2}, Ines Kovacic¹, Petra Rajcic³, Mia Maltar³, Lucija Milos³

⁽¹⁾University of Zagreb, School of Dental Medicine, Zagreb, Croatia; ⁽²⁾University Hospital Dubrava, Zagreb, Croatia; ⁽³⁾Private Dental Clinic, Zagreb, Croatia)

Objectives: Computer aided design (CAD) – computer aided manufacturing (CAM) is irreplaceable and very important technology in dental medicine. Therefore, the aim of this study was to investigate the knowledge and awareness toward CAD-CAM technology and its use in prosthodontics among students of dental medicine.

Materials and methods: The study was conducted among students at School of Dental Medicine, University of Zagreb. 216 students were included in this study. Participants were divided according level of their education: 77 preclinical students and 139 clinical students. Participant were also divided according to the gender. The study was approved by the Ethics Committee of the School of dental medicine University of Zagreb. All participants filled out the questionnaire specially designed for purpose of this study. The results were statistically analysed with a significance level of $p < 0.05$.

Results: All participants (216, 100%) included in this study have heard about CAD-CAM technology. Most of participants

(204, 94.4%) did not attend any additional CAD-CAM course, they attended only regular lectures at the School of Dental Medicine ($p < 0.05$). Also, most of preclinical (72, 33.3%) and most of clinical (133, 61.6%) students believe that they are not sufficiently informed about CAD-CAM technology ($p < 0.05$). Most of preclinical (48, 22.3%) and most of clinical (70, 32.4%) students answered that they didn't see any CAD-CAM restoration ($p < 0.05$). Most of preclinical (73, 33.8%) and most of clinical (127, 58.8%) students stated that it is necessary to learn more about CAD-CAM technology at regular lectures ($p < 0.05$).

Conclusions: According to the results obtained in this study, it could be concluded that students are not sufficiently informed about CAD-CAM technology in dental medicine regardless of their level of education (preclinical/clinical students). The results indicate the need for organisation of additional education toward CAD-CAM technology.

Keywords: CAD-CAM, knowledge, dental medicine

There is no potential conflict of interest.

Patient-Specific Titanium Implant Solution For Total Atrophic Upper Jaw. A Case Report

Rihards Lācis¹, Ingus Arnolds Apse², Aleksejs Dons², Ģirts Šalms²

(¹Department of Prosthodontics, Faculty of Dentistry, Riga Stradins University, Latvia; ²Department of Oral and Maxillofacial Surgery, Faculty of Dentistry, Riga Stradins University, Latvia)

Introduction: Conventional implant procedures are often not possible in cases of significant atrophy, leaving patients with few treatment options. In this case report, we present a treatment method using a patient-specific titanium implant to address total atrophic upper jaw in a single operation. Every phase from first visit till 9 months postoperative was documented.

Case Description: A 48 year-old male presented to a prosthodontist with a failing total metal-plastic bridge. After dental revision, most of the maxillary teeth were extracted (excluding D13, D23) and removable partial denture was fabricated. As the patient was insisting on fixed prosthesis and due to extensive maxillary atrophy, simple implant based restoration was not possible. Primary D13, D23 extractions as well as soft tissue augmentation in the posterior region with Epiflex (decellularized human skin tissue) was carried out. Dual scan protocol was used together with an intraoral

scanner using teeth in wax dentures with radio-opaque composite landmarks. Proper occlusion was achieved and using the dental arch as a reference implant pillar position was planned. Surgery was done under general anaesthesia (nasotracheal intubation). Implant was fixed with 29 bicortical screws. Surgery was 4 hours long. Immediate total prosthesis was fixed on the implant with ~15Ncm. Follow-up included the following sequence (1 day, 1, 2 weeks, 1,3,6 and 9 months after surgery) and except unrelated viral infection it was uneventful. The patient-specific titanium implant was successfully placed and integrated into the atrophic jaw.

Discussion: This case report demonstrates the potential of patient-specific titanium implants as a treatment option for patients with significant alveolar bone atrophy. Further research is needed to fully understand the effectiveness and long-term outcomes of this procedure.

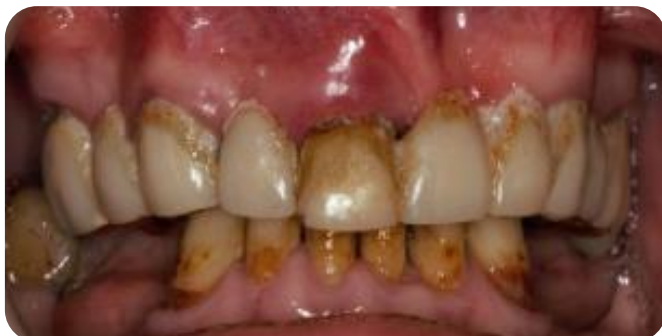

Figure 1: Initial situation.

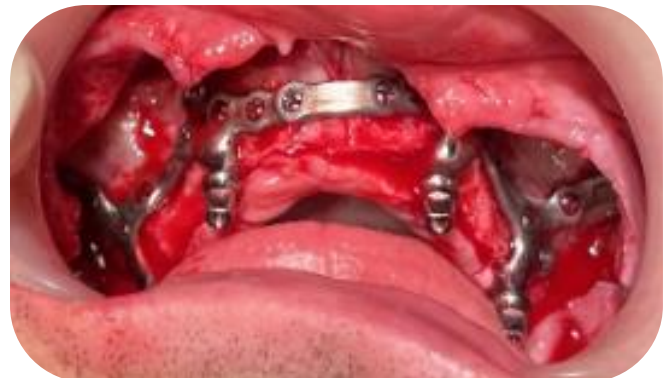

Figure 2: Surgery phase with implant placement.

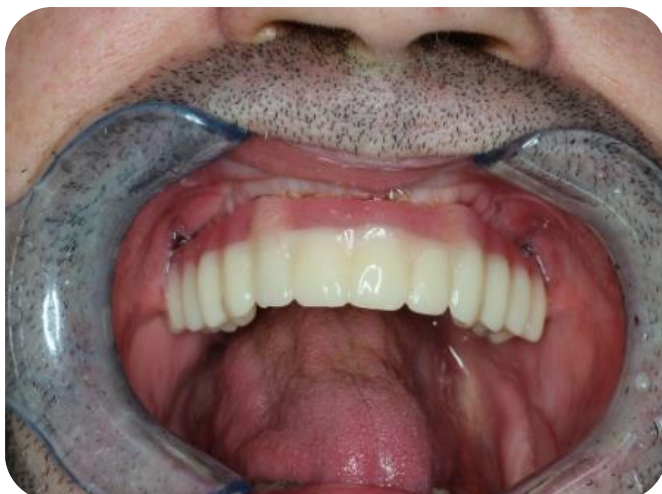

Figure 3: Temporary fixed prosthesis.

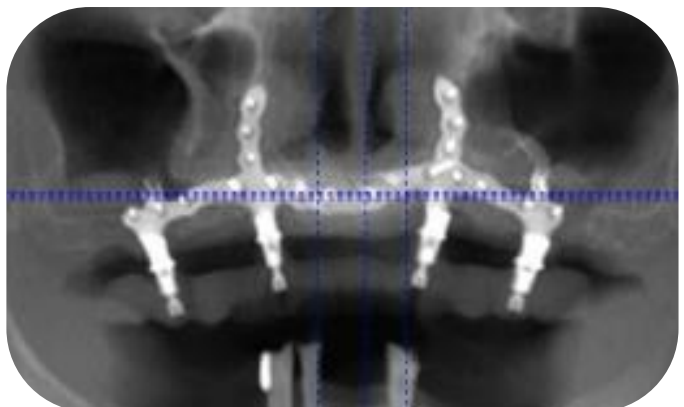


Figure 4: CBCT after operation.

The Influence of Pharmacotherapy in Chronic Diseases on the Severity of Painful Symptoms of Temporomandibular Disorders

Grad Katarzyna¹, Kazibudzka Zuzanna², Pihut Małgorzata², Wieczorek Aneta²

(¹University Dental Clinic, Cracow, Poland; ²Jagiellonian University Collegium Medicum, Cracow, Poland)

Objectives: Temporomandibular disorders (TMD) constitute a heterogeneous group of disorders affecting the temporomandibular joints, surrounding muscles, and bone structures. The etiology of these anomalies has been the subject of scientific debate for years due to their multifactorial and diverse nature, yet the influence of many factors remains ambiguous. Symptoms can manifest as painful conditions in the periarticular tissues or as painless symptoms characterized by the presence of acoustic manifestations in the joints or functional disturbances. The aim of the study was to verify the existence and evaluate the correlation between the use of pharmacotherapy in chronic disorders and the occurrence and severity of painful symptoms in temporomandibular disorders.

Materials and methods: Retrospective studies were conducted based on the analysis of 252 questionnaires completed by patients who had reported to the Prosthetic Clinic of the University Dental Clinic in Krakow due to symptoms of TMD. The group was divided into four subgroups, depending on the type of medications

used: endocrinological (24% of patients), cardiological (11% of individuals), psychotropic (7% of individuals), and others (18%). The data were subjected to statistical analysis using the R program, with a p-value < 0.05 considered significant.

Results: It was observed that in the group of patients taking endocrinological medications, there is an increased risk of experiencing headaches. No correlation was found between the use of any of the investigated medication groups and the severity of painful symptoms in TMD, both currently experienced and their average values from the preceding two months.

Conclusions: Statistically significant differences were not found between the types of medications used and the severity of painful symptoms in TMD. However, a correlation was demonstrated between the use of endocrinological medications and the risk of experiencing headaches.

Keywords: temporomandibular disorders, TMD, chronic diseases, pharmacotherapy, headache.

CBCT Single Scan With Intraorally Placed Radiopaque Complete Denture: A New Approach in Computer Designing of Patient Specific Subperiosteal Implants

Zimsek Mijovski Janet

(Department of Prosthodontics, University of Ljubljana, Faculty of Medicine, Department of Dental Prosthetics, Ljubljana, Slovenia)

Background: Maxillary alveolar ridge atrophy presents a clinical challenge for successful fabrication and stability of a complete denture. Extreme resorption of the maxillary alveolar ridge usually requires surgical augmentation and insertion of intraosseous implants before dentures can be produced. Augmentation procedures (vertical, horizontal, sinus lift) in such patients are demanding, results are unpredictable and time consuming. To avoid the aforementioned, prosthodontic treatment on patient specific subperiosteal implants (PSSI) is the method of choice. Before designing PSSI we have to know the position of the bone buttresses where the implant will be fixed to the maxilla and the thickness of soft tissues (gingiva) in order to optimize implant prosthodontic treatment.

Aim: With a CBCT scan of the patient's midface, intraoral soft tissues and the inserted patient's complete denture we obtained a high quality outset for computer assisted design and manufacture of PSSI model.

Material and Methods: To make the denture visible and soft tissues delineated on CBCT scan, additional radiopaque acrylic resin denture was produced with the use of barium sulphate powder. Small radiopaque acrylic resin plates (2 square centimetres) with

four different concentrations of barium sulphate (10, 20, 40 and 60%) were made and their radiopacity visually evaluated using a CBCT scan. The most favourably visualised plate was selected, with the 10% of barium sulphate, which presented our standard barium sulphate concentration in manufacturing acrylic resin denture duplicate for a single CBCT scan.

Results: In the first step a conventional complete denture was fabricated. In the second step a barium sulphate containing complete denture radiopaque duplicate was made. A maxillofacial CBCT single scan of the patient with intra-orally placed radiopaque complete denture duplicate was performed and used for segmentation and PSSI design.

Clinical implication: This approach has advantages over current (dual scan) method, including improved efficiency, faster times, and most importantly accuracy in three dimensional visualisation of the bone, soft tissues, denture and interjaw relationship. Only one CBCT scan is performed. Once the digital model based on CBCT single scan is created, the clinician can design PSSI by determining placement, size, shape, direction of fixation screws for the implant, and attachment elements for the prosthesis. The clinician can also use the model to simulate the outcome of the treatment and to evaluate the potential risks and benefits.

Restoration of an Implant With Modified Implant-Abutment Interface Using Digital Methods: A Case Report

Panagiotis Lambropoulos¹, Antonia Lianou², Ioannis Kanellos³, Aspasia Sarafianou⁴

¹Scientific Associate in Department of Prosthodontics, School of Dentistry, National and Kapodistrian University of Athens-NKUA; ²DDS, National and Kapodistrian University of Athens-NKUA; ³Postgraduate Student in Prosthodontics, National and Kapodistrian University of Athens-NKUA; ⁴Assistant Professor, Department of Prosthodontics, School of Dentistry, National and Kapodistrian University of Athens-NKUA

Introduction: Due to mechanical and/or biologic complications, implant-supported restorations may need to be redone or extended. The identification of implant company and type, as well as potential damage of implant-abutment interface or components is a common problem that has to be resolved.

Case Description: A male patient visited the dental office complaining of bleeding around an implant restoration consisting of three splinted crowns on 024-025-026. After peri-implantitis was diagnosed and treated, the replacement of the restoration was deemed necessary. The implant company was identified using information provided by the previous dentist. Radiographic examination revealed the absence of a retaining screw for the crown at 025. The attempt for intraoral scanning failed, as the fixation of a compatible scan body on the internal hex of implant crown at 026 was impossible. Scan bodies of the same company with different features were tried unsuccessfully. Scrutinized observation of the implant revealed that the inner

surface of the internal hex had been modified with a dental bur, possibly in an attempt by the previous dentist to seat the pre-existing restoration. A suitable non-rotating titanium base was connected to the implant at 026 and an intraoral scan was obtained using scan bodies for the rest of the implants. Crowns on 024 and 025 were digitally designed using the appropriate libraries, while the crown on 026 was designed to passively seat on the titanium base. All crowns were splinted. The restoration was screw-retained on implant 024 and a 17 degree multi-unit abutment was used for implant 025, in order to correct the tilt. The cantilevered crown on 026 was cemented intraorally with resin cement on the titanium base.

Discussion: This technique enabled the use of the implant 026, despite its internal hex deformation, which could render it inactive. The integration of digital technologies in the clinical practice expands its possibilities and facilitates dealing with technical problems.

A Fully Digital Workflow For a Staged Transition From a Terminal Dentition to Implant Rehabilitation

Antonia Lianou¹, Ioannis Kanellos², Panagiotis Lambropoulos³, Aspasia Sarafianou⁴

¹DDS, National and Kapodistrian University of Athens-NKUA; ²Postgraduate Student in Prosthodontics, National and Kapodistrian University of Athens-NKUA; ³Scientific Associate in Department of Prosthodontics, School of Dentistry, National and Kapodistrian University of Athens-NKUA; ⁴Assistant Professor, Department of Prosthodontics, School of Dentistry, National and Kapodistrian University of Athens-NKUA

Introduction: Intraoral scanning as a digital impression technique is a useful alternative to impression materials for periodontically affected teeth with mobility of third grade and inadequate bone support (final stage). Frequently, there is a risk of extraction for these teeth during analog impression techniques. Digital methods provide simplicity, ease and precision in maintaining and transferring the desired vertical dimension from terminal dentition or the interim prosthesis to the final restoration.

Case Description: An initial digital impression was obtained through intraoral scanning, where the existing vertical dimension was recorded. This vertical dimension was considered acceptable both aesthetically and in terms of function and it was decided to maintain it. This was followed by digital extractions and a digital diagnostic wax-up of the maxillary dental arch, which was imported in a surgical planning software program and was aligned with the dicom files of the CBCT, for guided direct implant placement planning. After direct implant placement was ruled out due to extensive periapical lesions and inability to safely choose acceptable

implant sites, extractions of all maxillary teeth with preservation of the canines were performed. The canines were prepared in the same appointment and scanned with post-extraction and edentulous spaces. On the 7th postoperative day, stitches were cut and the placement of a fixed transitional tripod metal-acrylic restoration was performed on the prepared canines.

The risk of tooth extraction during impression was eliminated and the delivered interim restoration required minimal occlusal equilibration. The vertical dimension was maintained without the process of cross-mounting on a mechanical articulator. Finally, the patient's aesthetic appearance and function were restored.

Discussion: The digital workflow:

- is a useful alternative to preserve desirable elements during the transition to final restoration.
- is a useful technique for designing and simulating complex perio-prosthetic cases.
- reduces clinical and laboratory time and provides satisfactory clinical accuracy.

Digital Partial Multifunctional Guide: One Guide for All; Surgery, Provisional, and Permanent Fixed Partial Dentures

Sebastian Bravo¹, Sofi Tapia¹, Sebastian Contreras Kock¹, Damla İlhan Atalay², Jonathan Can Atalay³, Pinar Turkoglu³

(¹Universidad Andres Bello, Santiago, Chile; ²Istanbul Kent University, Istanbul, Turkey; ³Istanbul Aydın University, Istanbul, Turkey)

Introduction: Prosthetically Driven Implant Dentistry (PDID) is described as the optimal approach for treating edentulous patients with implant-supported prostheses. This technical report aims to provide a step-by-step explanation of fabricating a partial multifunctional guide aiming to ensure correct implant positioning and reconstruction of the underlying tissues during osseointegration period leading to definitive prosthesis.

Case Description: A prosthetically guided approach was employed to a 60-year-old female patient with missing lower right molars in order to place two implants. The planning stage began with gathering patient data, including DICOM files from CBCT and STL files of the edentulous site. Virtual structures, mimicking the ideal anatomy for the rehabilitation area were created using laboratory planning software. These structures were designed with supporting cantilever placed on adjacent tooth occlusal surface, and chimneys were formed for prosthetic screw emergence. The structures were then modified and milled from PMMA discs matching the tooth color.

The surgical guide assisted in accurate implant placement then minor modifications were made to convert the guide into an adhesive provisional restoration. In the second-stage surgery, the same guide/provisional served as a reference for implant locations and the creation of the provisional restoration, designing the emergence profile for the future restoration.

Discussion: PDID provides a more controlled approach to implant placement, reducing the potential for errors and deviations from the planned position. Digital partial multifunctional guide ensures precise implant placement considering the patient's unique anatomical and prosthetic requirements. The guide's material allows modification with composite resin, facilitating the creation of an ideal emergence profile also the definitive model that can be duplicated during the production of the final prosthesis. Described multifunctional guide may be a practical alternative to conventional overcosting guide methods.

Keywords: Surgical guide, digital dentistry, CAD/CAM

Double-Crown Prosthesis Retention Using Peek Secondary Crowns: A Case Report

Ioannis Kanellos, Ioannis Papathanasiou, Spiridon Avgoustis, Phophi Kamposiora

(National and Kapodistrian University of Athens, Athens, Greece)

Introduction: This clinical report presents the use of a poly-ether-ether-ketone (PEEK) material as an alternative material for the fabrication of secondary copings for the retention of a fixed telescopic prosthesis. This material presents high biocompatibility, good mechanical properties and low modulus of elasticity (4 GPa) providing a cushioning effect that may reduce stresses transferred to the abutment teeth, while previous studies found no loss in retentive force of peek secondary crowns.

Case description: A 55-year-old woman presented for prosthetic rehabilitation of the upper jaw. Most of the remaining teeth (#17, 13, 12, 11, 23, 24 and 27) had questionable prognosis, thus a fixed double-crown prosthesis was fabricated offering stability and retrievability. After definitive impression and interocclusal centric relation record, tooth-supported chrome cobalt primary crowns with 0o taper and 0.3 mm thickness, were digitally designed and fabricated with

laser sintering. Their fit was verified intraorally and a pick-up impression was obtained. The new cast with the primary crowns was scanned and secondary crowns were CAD/CAM-fabricated by milling peek blanks (Tecno Med, Zirkozahn) with a thickness of 0.3 mm. A chrome cobalt framework for a fixed telescopic bridge was designed over the secondary crowns and fabricated with laser-sintering. The fit of the framework with the integrated peek secondary crowns was checked and then the secondary crowns were cemented in the inner surface of the final metal-ceramic prosthesis using a dual-cured resin cement. The final prosthesis was clinically evaluated and the patient was fully satisfied with the retention provided.

Discussion: PEEK can be a viable treatment solution for secondary telescopic crowns. However, more clinical studies are needed to evaluate the behavior of this material.

CBCT Evaluation of Bone Density in Maxillary Canines and Premolars Area in Patients with Periodontitis

Renata Symonenko, Leonid Etnis, Zinaida Zhehulovych, Vitalii Parii, Olena Astapenko

(Bogomolets National Medical University, Kyiv, Ukraine)

Objectives: to evaluate alveolar bone density in maxillary canines and premolars areas in patients with periodontitis according to cone-beam computed tomography examination.

Materials and methods: 42 cone-beam computed tomograms of adult patients with generalized and molar-incisor pattern periodontitis aged from 19 to 58 years (mean age 37.8 ± 12.3) were obtained and examined at Dental Medical Center of Bogomolets National Medical University. Measurements of CBCT bone density of 3 mm² area of medullar, vestibular and palatal cortical bone surrounding maxillary canines and premolars were made by InVesalius v.3.1 software. Results in Hounsfield units (HU) were presented as means and standard deviations and statistically analyzed with t-test using MedStat v.5.2 software. Statistical significance was set at $p < 0.05$.

Results: The mean values of CBCT bone density were as follows: 634.5 ± 272.5 HU (medullar bone), 1524 ± 305.4 HU (vestibular cortical bone), 1312 ± 260.3 HU (palatal cortical

bone) in canines area and 512.4 ± 167.6 HU (medullar bone), 1452 ± 305.7 HU (vestibular cortical bone), 1088 ± 222.7 HU (palatal cortical bone) in premolars area. There was not revealed statistically significant difference in bone density values between maxillary canines and premolars areas.

Conclusions: even though the values of bone density of individual patients in canines area were a little bit higher than in premolars area, it was not found a statistically significant difference between bone density values in maxillary canines and premolars areas among examined population. Further research is needed in order to find more evidence and use bone density values for prognosis of periodontitis course and treatment planning.

Keywords: cone-beam computed tomography, bone density, periodontitis, cuspid, bicuspid.

The authors declare the absence of any conflict of interest.

Fixed Partial Dentures Supported By Mini Dental Implants: Case Report

Sanja Persic Kirsic¹, Petra Rajcic², Nikola Petricevic¹, Zarko Udiljak^{2,3}, Anka Coric⁴

(¹School of Dental Medicine University of Zagreb, Zagreb, Croatia; ²Private Dental Clinic, Zagreb, Croatia; ³Faculty of Dental Medicine and Health, Josip Juraj Strossmayer University of Osijek, Osijek, Croatia; ⁴Health Center, Mostar, Bosnia and Herzegovina)

Introduction: Many patients prefer fixed partial dentures (FPDs) to replace missing teeth. However, lack of bone volume, deficiency in interdental space, financial resources, compromised health, are predominant factors that prevent patients from receiving FPDs by standard sized implants (SDIs). The introduction of mini dental implants (MDIs) has created more treatment options for a variety of clinical situations. This case report presents the MDIs supporting FPD in the mandibular incisor region.

Case description: A 65-year-old patient came to the clinic requesting mandibular incisor replacement. In the maxilla patient was missing posterior teeth and wearing removable partial denture. Upon clinical and cone-beam computed tomography (CBCT) examination, buccolingual bone width on the anterior mandible was found to be less than 5 mm. The patient declined SDIs supporting FPD due to the need for additional surgery and cost, so an alternative treatment option using three MDIs supporting FPDs was presented and approved by patient. Provisional acrylic bridge was made. After osseointegration final splinted metal ceramic restorations was made and cemented using a zinc phosphate cement. The MDIs supported FPDs have been in function successfully for 10 years. Marginal bone loss (MBL) was very low during the observation period.

Discussion: In this case report, 3 MDIs were placed in the incisor's site of the anterior mandible due their narrow diameter to avoid long-lasting treatment procedures needed for SDIs placement. MDIs were splinted to withstand MBL and/or implant body fracture. Namely, MDI is a one-piece implant without any abutment screw and the same force that causes screw loosening with SDI possibly may cause these complications. Small amounts of MBL recorded could also be due to low occlusal forces and higher bone density in the anterior mandible. The MDIs have been shown to be a predictable treatment option for the replacement of mandibular incisors for this patient.

Keywords: mini dental implants, fixed partial denture, one-piece implants, inadequate bone volume There is no potential conflict of interest.

Acknowledgment: To Croatian: Scientific Foundation for Funding Project No. 1218 from 2015 to 2020, "Mini Dental Implants"

Rehabilitation of a Periodontitis Patient With Implant Supported Fixed Prosthesis

Zeynep Büşra Duran*, Ali Balık*, Meltem Özdemir Karataş*

(Istanbul University Department of Prosthodontics)

Introduction: Periodontitis; It is a destructive inflammatory disease affecting the periodontal ligament, cementum, alveolar bone, and gingiva. Loss of supported tissues is one of the most common causes of tooth loss. In the prosthetic treatment of a patient with periodontal disease, functional and aesthetic problems are observed due to gingival recession and mobility of existing teeth. In this case, full mouth prosthetic restoration was performed after periodontal treatment and dental implant placement in a patient with periodontal disease and, maxillary and mandibular partial edentulism.

Case Description: A 42-year-old male patient with advanced periodontitis applied to the Department of Prosthetic Dentistry Clinic in Istanbul University, after the periodontal treatments and dental implantation were completed. In the clinical

examination of the patient, it was observed that the existing teeth in the mouth were excessively extruded. In order to provide splinting of the existing teeth, to bring the vertical dimension to an ideal level and to obtain a more aesthetic result, it was decided to crown the existing teeth by including them within implant supported prosthesis planning.

Conclusion: In a patient with periodontitis, after the necessary periodontal treatments were completed, a satisfactory result was obtained for the patient with the crowned of the teeth with gingival recession, both in terms of splinting and supporting each other, and with implant-supported fixed prosthetic restoration in terms of meeting aesthetic expectations.

Keyword: Periodontitis, Oclusal Vertical Dimension, Dental Implantation, Fixed Prosthesis

The Influence of ARCUSdigma™ 3 for Prosthodontic Digital Workflow of Implant-supported Restorations

Lenka Vavrickova¹, Martin Kapitan¹, Jindrich Charvat^{2,3}, Hana Hubalkova², Marie Bartonova⁴

(¹Department of Dentistry, Charles University, Faculty of Medicine in Hradec Kralove, and University Hospital Hradec Kralove, Czech Republic; ²Institute of Dental Medicine, First Faculty of Medicine of the Charles University and General University Hospital in Prague, Prague, Czech Republic; ³Private Dental Office, Státnice, Czech Republic; ⁴Private Dental Office, DMD, Prague, Czech Republic)

Introduction: Recent technological development, especially of digital technologies, opened new opportunities in clinical workflow in dentistry. For delivery of newly produced restoration with minimal intraoral adjustment, it is necessary to fabricate individually precise crowns and fixed partial dentures (FPDs). This is possible only with usage of virtual articulator and virtual simulation of mandible movements during chewing. The digital facebow can provide such individual data and values for CAD (computer aided design) settings for restoration milling or 3D-printing.

Case description: 65years old man came with the demand for a replacement of missing teeth 24, 25, 26, and 27. The implant-supported FPD (24-26) was planned (monolithic ZrO₂, screw retained). Due some additional issues, the plan was changed to porcelain fused to metal (PFM) FPD. Individual values were acquired from the digital facebow ARCUSdigma™ 3 and used for an adjustment of both virtual articulator (designing of the metallic framework) and conventional articulator (ceramics veneering). Currently, another two monolithic ZrO₂ FPDs were

milled (one with individual articulator setting and no post-processing improvements, one with average articulator settings and no post-processing improvements) to compare the occlusion in maximal intercuspal position (MIP) and in excentric movements of mandible and the influence of individual values settings for milling process. The amount of intraoral improvements during delivery appointment and the time demands were observed.

Discussion: The minimal necessity of intraoral improvements for PFM FPD (the individual values in the virtual articulator for the framework designing and in the conventional articulator for ceramics veneering) was proved. The maximal intraoral improvement was needed for milled monolithic ZrO₂ with average population values (Bennett angle 15°, sagittal condylar inclination 45°). Acquired individual values from digital facebow bring shortening of operator's working time during the delivery appointment and reduction in the amount of intraoral adjustments.

Keywords: digital, facebow, implant-supported

Effect of Tens on EMG Activity of Masticatory Muscles and Digital Occlusal Analysis in Bruxism-Patient

Elif Kilic

(Research Assistant, Gazi University Faculty of Dentistry, Department of Prosthodontics, Ankara)

Bruxism is a multifactorial and a parafunctional disorder which is characterized by grinding and clenching. Although bruxism is not a life-threatening disorder, it can influence the quality of human life, especially through dental problems, such as tooth wear, frequent fractures of dental restorations, and pain in the orofacial region. Masticatory muscle hyperactivity is a typical sign of bruxism and its mechanism have been explained previously. Transcutaneous electrical neuromuscular stimulation (TENS) has been described in the literature as a form of treatment for bruxism to decrease the pain perception and muscle relaxation.

In the present clinical report, a 26 years old female patient was referred to our clinic for the pain of the masseter area. In clinical examination patient had limited mouth opening (28 mm), masseter muscles pain on palpation and parafunctional

tooth wear. The patient was diagnosed as bruxism. Joint sounds were examined with BIO-JVA (Joint Vibration Analyses) to evaluate the TMD (Temporomandibular disorders). Before the application of occlusal splint, in order to increase the limited mouth opening and reduce pain, TENS therapy was applied for 40 minutes with ULF- TENS device (QuadraTENS). To evaluate the immediate effect of TENS, the electromyography (EMG) activity of masseter and anterior temporalis muscles (Bio-EMG 3) and digital occlusal analysis (Tscan 8) were recorded synchronously. Recordings was performed in clenching, protrusion, right and left lateral movement before and after TENS therapy. After the application of TENS therapy, patient had reduced EMG activity in the masseter and anterior temporalis muscles in resting and decreased occlusion time in multibite.

Keywords : BRUXISM, TENS, BIO-JVA, EMG, T-SCAN

Adjustment of Canine-Guided Occlusal Splint with Digital Occlusal Analysis in a Patient With Bruxism

Melike Ozbaykal

Sleep bruxism is an involuntary activity of the masticatory muscles that is characterized by clenching and/or grinding of the teeth during sleep. The occlusal splint has been frequently used as an effective treatment of sleep bruxism to protect teeth from damage caused by forceful jaw muscle contractions. Occlusal splints redistribute the load borne by the teeth and masticatory system. The relief of bruxism symptoms with splint treatment may be a result of redistribution of overloading, therefore an optimal occlusion with splints should be performed. In the adjustment procedure of occlusal splint with an optimal occlusion, clinicians usually use conventional methods; however, they cannot measure the surface area of contacts, amount of force and contacting time sequence. The use of digital occlusal analysis systems are advantageous to get objective data and to evaluate occlusal forces precisely.

A 27 years old male patient referred to our clinic with a history of teeth grinding. Based on anamnesis and clinical examination,

the diagnosis of bruxism was given with no significant internal joint derangement. A canine-guided occlusal splint was fabricated from self-cure clear acrylic resin. The occlusion of splint was adjusted with T-Scan III to fulfill the requirement of the optimal occlusion criteria. The occlusion was checked in both supine and upright positions so that any change in jaw posture does not create an uncomfortable contact. After adjustment of occlusal splint in centric relation even simultaneous contact with no premature contact was performed with appropriate occlusion and disocclusion time. Left and right force distribution was adjusted as 50,7% and 49,3% respectively. In centric relation, heavier posterior teeth contacts were performed than anterior in occlusion of occlusal splint. This technology provides a new standard of verification for the validation of occlusal splint fabrication with the optimal occlusion.

Keywords: OCCLUSAL SPLINT, TSCAN, DIGITAL OCCLUSAL ANALYSIS, BRUXISM

Implant-Prosthetic Rehabilitation of the Edentulous Maxilla

Petra Rajcic¹, Josip Kranjcic², Zarko Udiljak^{1,3}, Sanja Persic Kirsic²

(¹Private Dental Clinic, Zagreb, Croatia; ²University of Zagreb, School of Dental Medicine, Zagreb, Croatia; ³Faculty of Dental Medicine and Health, Josip Juraj Strossmayer University of Osijek, Osijek, Croatia)

Introduction: Although general medicine and dentistry have developed greatly, tooth loss is still a leading public health problem. Modern dentistry aims to provide patients with prosthetic therapy that would fully restore the aesthetics and function of the masticatory system. This case report presents the implant prosthetic rehabilitation of a patient with a completely edentulous maxilla.

Case description: A 72-year-old patient came to the clinic with old and damaged fixed restoration in the maxilla. There was no need for prosthetic treatment in the mandible. Maxillary teeth abutments were decayed and mobile; according to the clinical condition in the patient's mouth and radiographic analysis, the treatment plan was determined. The patient was informed about the possibility of treatment with multiple implants to support a fixed restoration in the maxilla. After extraction of the remaining maxillary teeth, the patient was restored in the maxilla with a removable immediate prosthesis. Three months after extraction, implant placement and sinus lift were performed. After six months, the implant sites were fully healed

and free of signs of inflammation. Fabrication of a screw-retained prosthesis was started. Unilateral balanced occlusion was performed. The patient was satisfied after placement, and no complications were noted during follow-up visits.

Discussion: In this prosthetic rehabilitation, 6 implants were placed in the maxilla for biomechanical reasons and to avoid cantilevers. The position of the inserted implants is planned based on optimal force transmission to ensure the longevity and success of the prosthetic rehabilitation. Screw-retained prosthesis was chosen to ensure retrievability, maintenance, and any necessary repairs. Implant prosthetic screw-retained restoration on six implants was considered the most appropriate treatment solution for this patient. Two years after completion of the prosthetic rehabilitation, no complaints occurred and the patient was completely satisfied.

Keywords: implants, rehabilitation, screw-retained

There is no potential conflict of interest.

From Hopeless Dentition to Immediate Dentures: A Fully Digital Workflow

Verniani Giulia ¹, Casucci Alessio ¹, D'Arienzo Luigi F.¹, Ferrari Marco¹

(¹Unit of Prosthodontics, University of Siena, Siena, Italy)

Introduction: To present the digital workflow for the fabrication of removable complete prostheses, from the hopeless dentition to the immediate dentures. To evaluate the effect of the treatment on masticatory performances.

Case description: A 58 year old patient referred to Siena University Prosthodontic Department complaining functional and esthetic discomforts. Anamnestic data and pictures were collected the clinical observation and rx evidenced- hopeless dentition in both arches due to severe periodontal problems. The Digital intraoral scans, a facial scan and the centric relationship were recorded in the same appointment. The treatment plan included the extraction of the teeth and delivery of an immediate post-extraction prostheses. The roots of lower canines were maintained for direct attachments anchorage. The immediate denture were obtained by ivotion oversize milling process (Ivoclar Vivadent). The prostheses were immediately

inserted after surgery and maintained during all the healing period. Pre and post insertion evaluations of masticatory performances were evaluated using two colored chewing-gum test and recording maximum bite force (Innobyte, Kube innovation). The patient was collaborative during treatment. No symptoms nor pain were reported either during the immediate post-extractive. In general, the patient reported good esthetic satisfaction and optimal functional comfort. The masticatory performances reported a slight improvement in the followup.

Discussion: The digital workflow for complete dentures fabrication requires short time and effort. The use of an intraoral scanner, a dental CAD software program, and a milling machine allowed the complete digital finalization of the clinical case, resulting in good prostheses adaptation and enhanced esthetic and functional patient's satisfaction.

Optimizing Pre-Graduate Education in Prosthetic Dentistry through Multidisciplinary Approaches

MDDr. Jindrich Charvat, Ph.D.^{1,2}, MUDr. Jindrich Charvat, CSc.^{1,2}, doc. MUDr. Hana Hubalkova, Ph.D.¹, Mgr. Magdalena Cesnekova¹, doc. MUDr. Marie Bartonova, CSc.³, MUDr. Lenka Vavrickova, Ph.D.⁴

¹Institute of Dental Medicine, First Faculty of Medicine of the Charles University and General University Hospital in Prague, 121 08 Prague 2, Czech Republic; ²Private Dental Office Statenice, 252 62, Czech Republic; ³Private Dental Office, DMD, Vinohradska 196, Prague 3, Czech Republic; ⁴Department of Dentistry, Charles University, Faculty of Medicine in Hradec Kralove and University Hospital Hradec Kralove, Czech Republic)

Introduction: Aging of European population press universities and dental schools to enhance dental education in the field of Gerontology and Geriatric Dentistry. During clinical training students are guided to take a comprehensive view of prosthetic treatment focusing on the senior polymorbidity. Presence of experienced clinician educators chairside allows understanding of basic principles of multidisciplinary cooperation and logically treat more complex cases. Understanding the principles of comprehensive prosthodontic treatment in undergraduate dental education is a valuable experience for dental students to support them in their future practice. Students learn how to gain patient's trust, explain complex dental procedures, and interact with a variety of patients whose backgrounds can have a major impact on treatment choices.

Case description: Man, 67 years old, dg. depressions, fear and anxiety, polypharmacy, psychological trauma in his adolescent age. Heavy smoker. Dentition: Kennedy II, III, extreme attrition, movement of teeth, periodontitis, poor oral hygiene.

Plan: Multiple extractions, conservative treatment, PFM crowns, upper complete and lower partial dentures. Students did not carry out more sophisticated treatment plan due to patient's psychiatric problems, unreliable cooperation and his financial situation.

Discussion: Clinical teaching of dentistry is a key part of the training of future dentists but is limited to a large extent by the time allotment and the number of different cases that individual students will encounter. For these reasons, it is optimal to conduct high-quality digital documentation so that students can study more clinical cases and develop their skills. Teaching of clinical prosthetic dentistry for the elderly is influenced by special needs, demands and conditions of older patients. Each student must respect all patient's equality. There frequent handicap is level of oral hygiene, time factor and socioeconomic circumstances. Respecting these complex conditions results in a higher health-related quality of life.

The Rehabilitation of the Completely Edentulous Mandible Using Removable Implant Prosthesis - Case Report

Antonela Berar, Andreea Kui, Smaranda Buduru

(Faculty of Dental Medicine, Department of Prosthetic Dentistry, Iuliu Hatieganu University of Medicine and Pharmacy, Cluj-Napoca, Romania)

Introduction: Complete edentulism is a complex pathological condition, in which the total loss of teeth affects the oral functions, determines morphological changes in the alveolar bone tissues and oral mucosa, while also having a negative impact on the general health. The replacement of missing teeth has been done for a long time with conventional complete denture, which does not always have retention and stability on the prosthetic field, due to the irreversible process of bone resorption, occurring mainly in the mandible.

Case Description: A female patient, aged 68, reported to the dental office mainly because of low retention, the instability of conventional mandibular complete denture and masticatory inefficiency. The clinical evaluation revealed a complete edentulous maxilla and mandible restored with conventional complete protheses. The mandibular prosthetic field had a reduced support area, with a marked atrophy of the alveolar ridge. Radiological examinations - panoramic radiography and CBCT (cone beam computed tomography) were also performed and after measuring the height and weight of the remaining

bone, the therapeutic decision was to carry out a new complete mandibular prosthesis supported by implants. The surgical phase consisted of the placement of three endosseous implants in the interforaminal region. The prosthetic phase followed the clinical and technical steps needed to manufacture the removable prosthesis attached to the implants through a laser sintered bar, virtually designed in Exocad Dental CAD software.

Discussion: Removable implant-supported denture is a viable treatment option that improves the retention and stability of the prosthesis, increases masticatory efficiency, enhances patient satisfaction and quality of life. Hence, the choice of restorative treatment in fully edentulous patients must be performed according to individual clinical features.

Keywords: complete edentulous, implants, removable prosthesis

Email: antonela_berar@yahoo.com

Phone number: 0040 745009563

Managing the Esthetic Problem of a Pregnant with an Exaggerated Gag-reflex

Spyridon Stefos

(Dentist-Prosthodontist, Private Practice, Ioannina, Greece)

Introduction: Pregnancy is a critical period in a woman's life. The management of a pregnant concerning her prosthodontic treatment can be challenging for completing clinical stages successfully. This case report aims to describe the successful prosthodontic management of the patient's esthetic problem of her smile, with dental implants and fixed prosthesis, despite her gag- reflex in the third trimester of pregnancy (31 weeks), something uncommon for an uncomplicated pregnancy.

Case Description: A 28-year-old woman, primigravida in the third trimester of pregnancy (31 weeks), with a present normal pregnancy and a free medical history, presented to our dental clinic to solve her esthetic problem of her smile. The

pregnant was very apprehensive concerning treatment, due to exaggerated gag-reflex. The clinical, especially prosthodontic, management succeeded by using proper dental implant and fixed prosthesis design and simple, but effective, table salt technique in order to face symptoms during the clinical stages and consequences of gagging associated with late pregnancy.

Discussion: Solving the esthetic problem with successful prosthodontic treatment of women during the third trimester of pregnancy with severe gag-reflex can be managed by the usage of the easy and very practical table salt technique.

Keywords: Esthetic, Dental Implants, Pregnancy, Gagging, Patient Satisfaction

The Role of Gingivectomy in Providing Anterior Aesthetics

Ali Saygın Özgür¹, Adnan Tezel¹, Ezgi Öztol², Fatma Beyza Koyuncu²

(¹Department of Periodontology, Ankara University Faculty of Dentistry, Ankara, Turkey; ²Department of Prosthodontics, Ankara University Faculty of Dentistry, Ankara, Turkey)

Introduction: Gingivectomy is a procedure performed to lengthen the crown length and/or to remove exaggerated gingival appearance in teeth with inadequate clinical crown length before prosthetic applications.

Gingivectomy procedure is indicated for the removal of gingival tissue in the aesthetic area by laser, scalpel or electrocautery.

In this study, it is aimed to explain the restoration of lost aesthetics and function in the anterior region by completing oral preparation with periodontal applications and fixed prosthetic applications with a case report.

Case Description: A 19-year-old female patient was admitted to Ankara University Periodontology Clinic with the complaint of poor appearance of her related teeth. The patient's anamnesis revealed that she did not have any systemic disease. In the intraoral examination of the patient, there was no bleeding on probing of teeth numbered 11-21; plaque score was recorded

as 1. In addition, a 2 mm gingival pocket was detected on the labial aspect of teeth 11 and 21. Free gingival growth was present in this area. Radiographic examination did not reveal any pathology. Phase I treatment was initiated. Oral hygiene education was given to the patient. When the patient's gums became clinically healthy, Phase 2 treatment was initiated. Gingivectomy was performed.

The patient was allowed to heal for 14 days before proceeding to the prosthetic phase. After the post application, monolithic zirconia made with cut back technique was applied to the related teeth.

Discussion: The patient achieved aesthetic results after the treatment. It was concluded that gingival visibility is an important parameter in terms of aesthetics. The follow-up process of the patient continues.

Keywords: Gingivectomy, Crowns, Anterior Aesthetics

Single Crown Restorations Supported by One-piece Zirconia Dental Implants: Case Series at a Mean Follow-up of 58 Months

Dr. Antonino Palazzolo, Prof. Diego Lops, Prof. Eugenio Romeo

(Unit of Fixed and Implant Prosthodontics, University of Milan, Department of Biomedical, Surgical and Dental Sciences, Dental Clinic, School of Dentistry, University of Milan, Milan, Italy)

We submit to your kind attention the following abstract to evaluate its presentation at the International Congress of the European Prosthodontic Association, Vilnius September 2023.

We certify that neither the abstract nor any parts of its content have previously been presented elsewhere.

Objective: The main aim of this case series was to report the clinical and radiographic outcomes of 22 one-piece zirconia dental implants positioned in 19 patients to restore single edentulisms and followed-up for at least 2 years.

Materials and Methods: Operative procedures were performed between July 2015 and January 2021. All of the 19 subjects participating in this study were affected by partial edentulism at one or more sites. Clinical evaluation was carried out following Buser's criteria. Marginal bone levels (MBL) were assessed through standardized dental radiographs and a dedicated software. The mean distance between the implant head and the first detectable bone to implant contact was calculated at the mesial and distal aspect of each implant.

Results: The mean observation period was 58.18 months. At the last follow-up visit no issues were reported by the patients such as foreign body sensation, discomfort or pain. No implant showed signs of infection with suppuration or implant mobility.. The mean MBL at baseline was 1,82 +/- 0,63 mm while the mean MBL at the last follow-up visit was 2,57 +/- 0,72 mm.

Conclusions: The results obtained in the present case series over a mean follow-up period of 58.18 months (range 27-96) showed that one-piece zirconia dental implants could be an alternative option to support single crowns in patients requiring metal-free restorations. Nevertheless, further research featured by adequate study design, longer follow-up and better controlled is needed in order to clarify advantages and limitations that are related to this treatment modality.

Keywords: Ceramic, clinical study, dental implant, fixed dental prosthesis, zirconia implant

Prevalence of Signs and Symptoms of Temporomandibular Disorders in Turkish Dental Students Using Fonseca's Questionnaire

Elif M Gurer¹, Dilek P Senyilmaz², Ragibe S Canay¹

(¹Hacettepe University, School of Dentistry, Sıhhiye, Ankara, Türkiye; ²Okan University, School of Dentistry, Akfırat, Tuzla, Istanbul, Türkiye)

Objectives: The aim of this study was to evaluate the prevalence of signs and symptoms of temporomandibular disorders (TMD) by means of the frequency distribution of data for 1533 dental students from a Turkish Government University using the Fonseca's questionnaire.

Materials and Methods: This study included 581 male and 952 female students from first to fifth grades.

Results: The results showed that 58.6 % of the subjects exhibited some degree of TMD. Women were the most affected group, with 62.6 % showing some level of TMD, against 37.4% of men. A statistically significant difference was found between education and TMD status ($p < 0.001$). The probability of TMD was 36.7% in the first grade, 46 % in the second grade, 65.5 % in the third grade, 79.6% in the fourth grade and 82.3% in

the fifth grade. It was observed that the probability of TMD increased as the education level increased. Students with any level of TMD showed marked characteristics: 73% of women and 66.8% male subjects considered themselves tense people; 74.5% of female subjects reported frequent neck pain. Women subjects exhibited headache 1.566 times more than men ($p < 0.001$) When considering awareness of the limitation of the mouth opening, women were approximately 1.677 times more affected than men.

Conclusions: In conclusion, clinical signs and symptoms of TMD can occur in young population and this information is of great importance for the early diagnosis of the dysfunction.

Keywords: Temporomandibular disorders, pain, Fonseca's questionnaire

No Influence of the Clinicians' Experience on the Outcome of Dental Implants: A Clinical Audit

Omair Aldowah

(Najran University, Najran, Saudi Arabia)

Objective: The purpose of this outcome audit is to evaluate the influence of the clinicians' experience on the outcome of dental implants. In addition, to identify the associated risk factors that might influence the success and survival of the implants.

Methodology: Records of patients treated with SLA/SLActive Straumann implants were screened. This enabled us to have a minimum of 12 months of follow-up. Eligible patients, according to inclusion criteria, were contacted and invited to undergo a follow-up assessment. Success was accounted for and defined in a comprehensive manner by considering four different categories: implant perspective, peri-implant soft tissue perspective, prosthetic perspective, and patient satisfaction. Patients' investigations included clinical examination of implant mobility, suppuration, width of keratinized mucosa, probing depth, plaque accumulation, prosthetic complications, and patient satisfaction. Also, a radiograph was taken to evaluate bone loss and peri-implant radiolucency.

Results: Thirty-eight patients with 84 SLA/SLActive Straumann implants were available for the assessment. The mean age of

the patients at implant surgery was 49.05 ± 13.19 years. Over the mean follow-up period of 26 months, no implant fracture was noted. Overall, eight implants were considered failures (9.5%). Two out of six patients with a history of periodontitis (HoP) and two out of five smokers exhibited failed implants. Patients' satisfaction responses showed that all the responses were statistically higher than the test median value of 3. The median value of general satisfaction using a visual analogue scale was 9 out of 10.

Conclusion: This five-year audit of 84 Straumann implants with an SLA/SLActive surface in thirty-eight partially and fully edentulous patients revealed high survival and success rates (100% and 90.5%). Within the limitation of this clinical audit, Regarding implant failure, there were no identifiable contributing factors that were specific to the students' inexperience. It can be concluded that implant practice among trainee programme is satisfactory. History of periodontitis and lack of patients' compliance with supportive periodontal therapy in some cases have been shown to be risk factors associated with increased implant failure, mainly peri-implantitis.

Correlation Between TMJ MRI Findings of the Two Sides: A Systematic Review of the Literature

Nicolò Giuseppe Sorrenti¹, Matteo Val², Filippo Sornig¹, Luca Guarda Nardini², Marco Ferrari¹, Daniele Manfredini¹

(¹University of Siena; ²Ca' Foncello Hospital of Treviso)

Objective: The aim of this paper is to highlight the presence of articles which compare by magnetic resonance (MRI) evaluation the left and right temporomandibular joint of the same patient.

Materials and Methods: In February 2023, a systematic research of literature in the main search engines (Pubmed, Medline, web of science) was carried out to identify all peer-reviewed English-language studies presenting a comparison of left and right TMJ sides in the same patients. A PICO-like selection of the articles was performed. The review was then structured following PRISMA guidelines.

Results: The search term "temporomandibular joint AND magnetic AND resonance" carried out 2561 results. Of them 3 fulfilled the inclusion criteria. The results of the papers included in the systematic review are not comparable due to the different aims in the evaluation of temporomandibular joints. Manfredini *et al.* highlighted a statistical correlation

between disc displacement, osseous changes, and joint effusion within the same joint and between joints of the contralateral sides. Koca *et al.* pointed out a relationship between pain and MRI findings. Meanwhile, Chu *et al.* revealed that 3D MRI reconstruction visualized in a single image aids the understanding of TMJ dysfunction in patients with TMD.

Conclusion: The literature concerning the correlation between the right and the left TMJ is still scarce; very few articles report a comparative analysis of the two sides of the temporomandibular joints in individual patients. As far as could be observed, most of the articles concerning the research rationale, study the joint by evaluating ipsilateral correlations or by serial analysis of only one side of the anatomical structure, never evaluating the TMJ in its entirety.

Keywords: TMJ, magnetic resonance imaging, temporomandibular joint disorders.

Integrated Treatment of Cleft Lip Palate: A Case Report

Gülsu Demir¹, Ali Balık¹, Başak Keskin Yalçın², Merve Öztürk Muhtar², Meltem Özdemir Karataş¹

(¹Istanbul University Faculty of Dentistry, Department of Prosthodontics, Istanbul, Turkey; ²Istanbul University Faculty of Dentistry, Department of Oral and Maxillofacial Surgery, Istanbul, Turkey)

Introduction: Cleft lip and palate (CLP) is an anomaly characterized by the deterioration of the lip and palate integrity as a result of insufficient development of embryonic tissues during the formation of the maxilla. Although it is possible to reconstruct the defect with surgical intervention, some cases may not be reconstructed completely. These developmental clefts in the nasomaxillary complex cause aesthetic, phonetic and functional distortions. In these patients, obturator prostheses to cover the defect area combined with fixed prostheses are included as the traditional treatment method in the prosthetic treatments. However, especially in edentulous CLP patients, the insufficiency of the remaining supporting tissues and the gravity affect the retention negatively. For this reason, the use of implants provides great benefit if the general health status of the patient is suitable. In this case report, an obturator prosthesis that gets additional retention from implant supported fixed prostheses was presented.

Case description: A male patient with CLP who has no systemic diseases was referred to Istanbul University with the complaints of aesthetic and functional deficiencies. Since general health and bone structure were suitable, a total of 6 implants for the right and left side of the maxilla were done. For prosthodontic treatment, it was planned to make a crown to the tooth numbered 23, which is the only natural tooth in the upper jaw, and fixed prostheses over the implants with metal-porcelain material were done. For the rehabilitation of nasomaxillary cleft, an obturator prosthesis with clasps were made.

Discussion: Obturator prosthesis retained by implant supported fixed prosthesis offers an advantageous treatment option to eliminate retention problems of conventional obturator prosthesis.

Keywords: obturator, cleft palate, cleft lip, esthetics, quality of life

Transforming a Patient's Smile: A Comprehensive Makeover Using a One-Guide Surgery, Immediate Loading and All-on-Four System for Compromised Teeth

Recep Uzgur, DDS, PhD,

(Specialist in Prosthodontics Private Practice, Turkey)

Introduction: This abstract presents a case report of a 54-year-old male patient with multiple missing and compromised teeth in the upper jaw. The objective was to describe a comprehensive treatment approach using dental implants to restore function and aesthetics.

Case Description: The patient underwent a two-phase treatment plan. All remaining teeth were extracted, and four Hiossen implants were placed in the upper jaw. These implants were specifically chosen for their NH surface specifications, known for enhanced osseointegration and faster healing. Immediate loading was achieved by placing a fixed temporary prosthesis in the same session. The precise implant positioning was facilitated by utilizing One Guide Surgery Guide and guided surgery techniques along with cone-beam computed tomography (CBCT) scans. Six weeks later, the temporary prosthesis was replaced with a final prosthesis, which was designed with a preview smile to ensure optimal aesthetics.

Discussion: The comprehensive treatment approach successfully addressed the patient's concerns and restored the missing and compromised dentition. Immediate loading of the temporary prosthesis not only provided functional and aesthetic benefits but also improved the patient's quality of life during the healing period. The utilization of Hiossen implants with NH surface specifications expedited the healing process and reduced the treatment time to six weeks. The NH surface, known for its enhanced osseointegration properties, improved implant stability and success rates. The guided surgery techniques, including the utilization of Osstem One Guide Surgery Guide and CBCT scans, ensured precise implant positioning, enhancing the accuracy and predictability of the procedure. The all-on-4 implant system, in combination with the Hiossen NH surface implants and guided surgery, offered an efficient solution for full-arch rehabilitation. This approach minimized the number of implants required and reduced the overall treatment time.

Limited Perceptions and Knowledge of Undergraduate Dental Students about Artificial Intelligence in Dental Schools, Cross-sectional study

Omair Aldowah, Yazeed Alghuwaynim, Mohammed Alhutaylah, Abdullah Almakrami, Ali Almansour, Ali Alswedan.

(Najran University, Najran, Saudi Arabia)

Objective: This study aims to assess the perceptions and knowledge of undergraduate dental students about artificial intelligence (AI) in dental schools through a cross-sectional study.

Methodology: This was a multicenter, cross-sectional study. Participants recruitment was achieved by sending an online questionnaire to the undergraduate students at the assigned universities. The questionnaire consisted of two parts. The first seven questions record general information about participants and their perceptions of AI. The remaining questions are about the knowledge of participants about the applications of AI. The data was analysed using SPSS version 26.

Results: 165 undergraduate students from 20 universities related to the dental sciences responded to the questionnaire. 80.6% of participants found the use of AI in dentistry exciting. I have a basic knowledge of the working principles of artificial intelligence. 80.6% of participants believe that applications of AI should be part of undergraduate dental training. 66.6%

of students are aware of the opportunities and threats that AI can create. The results show that 75% of the students indicated that they got their information about AI through social media. Regarding the association of years of studies with AI applications used in periodontics, the knowledge about AI applications in 'aggressive periodontics', 'compromised teeth', and 'success in rate of dental implant' was significantly higher in senior students than junior students ($p < 0.05$). Concerning applications of AI used in restorative dentistry and prosthodontics, only 'computer colour matching', tooth surface losses', and 'I do not know' showed statistical significance ($p < 0.05$) with the year of study of participants. Senior students show significantly better knowledge in 'success in re-treatment' and 'working length determinant'.

Conclusion: Although undergraduates are enthusiastic about AI and aware of its threats and benefits, their knowledge is limited. In addition, undergraduate programmes must exert more effort to prepare students for the era of artificial intelligence.

The Rehabilitation of Partial Maxillectomy Edentulous Patients: The Prosthetic Solution vs the Surgical Reconstruction

Amin Boukhari

(The Oral & Maxillofacial Surgery & Rehabilitation Departments, Rambam Healthcare Campus - Haifa)

Abstract: Edentulous patients with partial maxillectomy defects (due to trauma or tumor surgery) are the most challenging cases to treat. In such cases the function of mastication, swallowing and speech, also the aesthetics are severely impaired. The trauma or the surgical intervention creates communication between the oral cavity, the nasal cavity and maxillary sinus. Despite the fact that it is usually challenging to rehabilitate the normal edentulous patients it is even more difficult to succeed when partial maxillectomy defects are added to the edentulous area. The size & location of the defect influence the amount of impairment and make it even more difficult to treat. In such cases the main goal of

the oral & maxillofacial rehabilitation treatment is to restore the missing oral & extraoral structures three-dimensionally in order to restore the form and function that have been severely damaged and at the same time to act as a barrier between the communication among the various cavities.

Those patients can usually be rehabilitated either with a removable obturator prosthesis or alternatively with a micro vascular surgery. Both treatment options have pros & cons.

We will discover together during the presentation the advantages and disadvantages of each of these two therapeutic modalities.

Erosive Tooth Wear Combined with Bruxism and Parafunctional Habits: Prevention, Diagnosis and Treatment

Mario Dawud

(Tel Aviv University, Israel)

Erosive tooth wear is a prevalent oral condition frequently observed in Israel and other developed nations worldwide. Despite its gradual progression, it can significantly impact an individual's quality of life.

The risk factors for ETW include acids from both external and internal sources, sometimes coupled with physical forces such as abfraction, attrition, abrasion, and parafunctional habits.

Early detection plays a crucial role in determining the appropriate treatment. A constant "race" occurs between acids and the protective effects of the pellicle and saliva. It is the responsibility of dental professionals to thoroughly document this condition in clinical records and effectively communicate this information to patients.

Fortunately, we now have simple tools like the basic erosive wear exam (BEWE), which enables grading of the condition for each patient and guides dental professionals in managing individual cases.

In our presentation, we aim to discuss the diagnosis, prognosis, and treatment dilemmas by showcasing various dental cases

treated in the Postgraduate Program in Prosthodontics at the Prosthodontic Department of The Maurice and Gabriela Goldschleger School of Dental Medicine, Sackler Faculty of Medicine, Tel Aviv University, Israel.

We will present cases ranging from mild to moderate to severe erosive tooth wear, addressing the unique treatment challenges in each case. Additionally, we will introduce diverse treatment modalities, such as monolithic zirconia crowns, inlays, and onlays, while discussing the advantages and disadvantages of each approach. Different adhesion techniques and postoperative instructions for patients will also be covered.

Our ultimate goal is to enhance awareness among dental professionals, particularly considering the prevalence of an acid-rich diet in Israel due to its robust agriculture industry, various occupational activities with high risk for erosion, and stressful lifestyle, which can sometimes contribute to bruxism, further exacerbating tooth wear in combination with erosion.

By considering all these factors, we aim to provide guidance to dental professionals on how to effectively manage each case.

Past and Present in Implantology Success and Failure Criteria

Forna Norina Consuela, Agop-Forna Dorian

(Faculty of Dental Medicine, U.M.F "Grigore T.Popa" Iasi, Romania)

Success or failure of the implant-prosthetic therapy are complex concepts that depend on the criteria. Both systemic status, smoking, anatomical and morphological conditions as well as interdisciplinary collaboration of the implantologist or oral surgeon influence the long-term outcome. Literature data report wide range of implants survival and success as well as technical and biological complications. Basic criteria for implant success are lack of implant mobility, absence of peri-implant radiolucency, proper width of the keratinized mucosa, and absence of peri-implant infection or patient discomfort.

Prospective and retrospective studies have changed basic criteria related to systemic conditions. Diabetes 2 is no longer significantly associated to implant failure. Smoking can lead to implant failure but its effect on implant osseointegration is related to dose. Short and narrow implants inserted in resorbed alveolar bone are associated with increased implant failure. Higher release of TNF- α or IL-1 β markers are associated with increased implant loss rates. Present implant success/failure criteria must include genetical and immunological factors.

One Health Concept: Prosthodontics on Implants for Dogs. Future or History?

Raluca-Ioana Nedelea, DDS, PhD student, DVM student

(Cluj-Napoca, Romania)

Introduction: Since dental implants were introduced as feasible long-term solutions for edentulous areas in the oral cavity, dog models were used first. All the dogs introduced in the studies were sacrificed, helping human dentistry understand osteointegration, local and biological factors involved in osteointegration, and microscopic aspects when inserting a dental implant. No one has continued the study further. What are the long-term results of dental crowns on dental implants in a dog's oral cavity? Dogs are becoming family members. People address veterinary dental specialists for high-quality therapeutical approaches. Dental crowns have been placed on teeth in dogs for a long time, and dental crowns on dental implants are becoming more popular.

Objectives: This report aims to present one health concept applied to prosthodontic crowns on dental implants in dogs and cats applying human dentistry's concepts.

Materials and Methods: Two cases with short-term complications of prosthodontics on dental implants in dogs

were used to illustrate the one health concept with common principles in veterinary and human dentistry.

Results: One health concept, the overall vision, led to long-term results with a follow-up period of one year.

Conclusions: Dentistry should extend the studies in dogs and cats over the osteointegration period. The basic principles applied in prosthetics on implants were integrated into veterinary prosthodontics. Each specie has its own characteristics that should be taken in consideration. One Health concept will provide answers both in human and veterinary dentistry.

Raluca.Nedelea@dentovet.ro

00 40 740 149 815

www.dentovet.ro

www.dentoralmax.ro

Digital Planning Techniques and Pro-Implantation Preparations in The Current Management of Oral Implantology

Agop-Forna Dorian, Norin Forna, Claudiu Topoliceanu, Norina Consuela Forna

(Faculty of Dental Medicine, U.M.F "Grigore T.Popa" Iasi, Romania)

Digital planning techniques can assist the implantologists and oral surgeons in the preparation of the pro-implant and pro-prosthetic stage for patient candidate to implant-prosthetic therapy. Various planning software such (Planmeca Romexis, OneDemand, DDS) are at disposal of the practitioners for measurements of the implant site dimensional parameters (height, width, bone density), localization of risk areas (maxillary sinus, mandibular alveolar nerve), or virtual positioning of implants. The use of digital tools, especially in posterior areas, can increase the clinical performance and patient satisfaction following the implant-prosthetic therapy. Patients with severe maxillary and mandibular alveolar bone atrophy require rehabilitation of the muco-osseous support in order to improve the clinical and biological indices of the

prosthetic field. The oral surgeon must select proper technique and graft materials in relation to the alveolar bone defect extension and morphology as well as with systemic and loco-regional factors. In the pro-implantation stage various bone addition techniques can be used such from horizontal and vertical augmentation or inlay/onlay bone blocks to complex guided tissue regeneration techniques. In the posterior maxillary areas these techniques can be combined with sinus lifting. Success rate of the alveolar bone grafting techniques and long-term outcome of the implant-prosthetic therapy in grafted implant sites depends mostly by systemic status, clinician experience, follow-up duration, as well as compliance of patients to maintenance sessions

CAD/CAM Removable Dentures and Soft Tissue Health: A Review of the Literature

Elina Blūma, Prof. Una Soboļeva

(Institute of Stomatology, Riga, Latvia)

Objectives: To analyze the scientific literature on the effects of digitally fabricated removable denture constructions, materials and their effect on soft tissue.

Materials and Methods: Literature search was performed electronically in databases: EBSCO, Science Direct, PubMed, Cochrane Library the period from 2013-2023 in English. Preference for clinical randomized trials, including prospective and retrospective studies. Keywords: CAD/CAM, 3Dprinting, clinical outcomes, adaptation, fit of restoration, denture, denture base, framework, soft tissue, biocompatibility, plaque accumulation, surface roughness in various combinations.

Results: A total of 97 articles were selected according to certain inclusion criteria. Removable constructions can be milled (in most cases) and printed (SLA, DLP, SLM). Commonly included materials are polymers and metals (PEEK, Cr-Co, Ti) for permanent, temporary or immediate purpose using teeth, implants and soft tissue as support. The articles addressing the clinical performance of materials (accuracy, surface roughness,

hardness) and their effects on soft tissue were selected for review. Traditional manufacturing methods were found in comparative studies. The most frequent problems are related to traumatic ulcers, Stomatitis and the health of supporting teeth. Technical features mentioned as affecting soft tissue: surface roughness, denture base adaptation, accuracy, print orientation.

Conclusions: The porosity obtained using different techniques of the materials attracts plaque and can adversely affect soft tissues but is within clinical acceptability when the prosthesis is used as an intermediate structure. Arrival of new technologies does not eliminate hygiene habits, recall and follow-up visits. Post-processing can affect the exact fit – palatal /border seal. Printing technologies still have future potential for improve mechanical properties (including reduced surface roughness). Relining in a convenient way has to be developed.

Keywords: CAD/CAM, removable dentures, soft tissue

Biomechanical Risks of Teeth with Separated Original and Counterfeit Endodontic Instruments Localized at Different Levels Within Root Canal

Anastasia Biley, Yuriy Mochalov, Igor Noenko

(Uzhhorod National University, Uzhhorod, Ukraine)

Objectives: To evaluate if counterfeit origin of separated endodontic instruments influence biomechanical prognosis of tooth.

Materials and methods: Approximated single rooted mandibular premolar model was formulated for the finite element analysis (FEA). Imitation of separated endodontic file localization was provided at two different levels: through the curvature but 3 mm before root apex, and behind the curvature with blocking 3 the most apical mm within the root. Imitated curvature degree was 60°, while two different radius of curvature were imitated of 5 mm and 2 mm. Broken endodontic fragment of 3 mm in length and apical part of size 20 and taper 0.04 were imitated in the study. SEM analysis of counterfeit endodontic files revealed that they are characterized with deviant cross-section, specific angle of flutes and not ISO-standardized design of the apical part. All these aspects were considered while modeling original and counterfeit endodontic files within the root canal for further FEA. Stress distribution and stress concentration zones were studied while imitating of 350 N vertical load.

Results: Teeth with imitated broken counterfeit endodontic files separated in the projection through the curvature were characterized with the highest peaks of stress concentrations at the contacts of broken fragment with surrounded dentine compare to other imitated scenarios; nevertheless such level of local uneven stress distribution seems not to be clinically critical considering other zones of stress concentrations unrelated with broken instrument. Stress concentrations were higher at the projection of curvatures with the smaller diameter in cases when separated instruments were located right at the curvature ($p < 0.05$).

Conclusions: Provided FEA analysis revealed that teeth with separated original and counterfeit endodontic instruments characterized with analogical biomechanical risks if compared clinical scenarios of broken file localization are identical, and those risks could not be interpreted as clinically significant.

Keywords: endodontics, root canal therapy, biomechanical phenomena, bite force

Dental Implants-Induced Artifacts Limits the Value of Jawbone CBCT Features for the Forensic Dental Identification

Myroslav Goncharuk-Khomyn

(Uzhhorod National University, Uzhhorod, Ukraine)

Objectives: To verify the impact of dental implant-induced CBCT artifacts on the possibility of using established jawbone structures features as independent markers during forensic dental identification.

Materials and methods: 46 pairs of CBCT data sets obtained before and after single implant placement were collected from the CBCT clinical registry. In-depth image analysis was provided for peri-implant zone before and after implant placement. Bone clustering and fractal analysis was held using Bone J plugins for Image J software (NIH, USA) on the previously segmented bone area (InVesalius software, CTI, Brazil).

Results: As per operator grading of available 46 post-implant placement CBCT images only 65.22% of them demonstrated some visually detectable signs of metal-induced artifacts of limited spread referred only to the close peri-implant area (0.56 ± 0.49 mm). Changes of peri-implant bone density occurred at the distances of 1-5 mm distant from implant screw, while also in-depth bone parameters, such as level of anisotropy ($p < 0.05$), fractal count ($p < 0.05$) and structure model index ($p < 0.05$) were

changed in statistically significant manner at the same distances while comparing to the before implant placement situation. Unique fractal counts at the similar study clusters of peri-implant area were changed while comparing before and after implant placement situations, but those changes characterized with inter-individual variations (variation ration – 0.78).

Conclusions: Dental implants-induced artifacts provoke significant variations of not only bone density at peri-implant region compare to the situation before implant placement, but also differently pronounced bone fractal pattern changes. Present outcomes argument that fractalization itself should be carefully used during comparative and reconstructive dental identification, since such could be compromised by artifacts of different nature, while fractal differentiation within the limited zone of interest still could be serve as minor marker of correspondence during comparative analysis.

Keywords: forensic dentistry, bone-implant interface, bone density, fractal

Evaluation of Implant-Supported Single Crowns Fabricated by Incorporating Intraoral Scanner-Based Mandibular Movement Data: A Clinical Study

Choi Ha Eun^{*1}, Hwa Jung Lee², Kyung Chul Oh², Hong Seok²

(¹Department and Research Institute of Dental Biomaterials and Bioengineering, BK21 FOUR Project, Yonsei University College of Dentistry; ²Moon Department of Prosthodontics, Yonsei University College of Dentistry, Seoul, Republic of Korea)

Objective: This clinical study aimed to assess the performance of single implant-supported single crowns fabricated by utilizing intraoral scanner-based mandibular movement data.

Methods: Thirteen adult participants who underwent single-implant treatments in the posterior region were included in the study. Three single crowns were fabricated for each participant, divided into three groups: Group VA, Group S, and Group SWM. In Group VA, an implant-level impression was taken using impression copings, and the values for articulator elements were obtained with a jaw motion tracking device (JMA-Optic System; Zebris Medical GmbH). The crown was designed using computer-aided design (CAD) software (Dental System; 3Shape A/S) and the virtual articulator tool. In Group S, digital scan data were obtained using an intraoral scanner (TRIOS 3; 3Shape A/S) and a scanbody (GMS Scanbody; GeoMEDI). After replicating the scan data, the mandibular movement was recorded additionally, and the crowns were fabricated by incorporating this movement in the CAD software to manufacture the crowns of Group SWM. The weight of the crowns was measured before and after the

occlusal adjustment, and pre- and post-adjustment scan data were obtained. Changes in crown weights and root mean square (RMS) values were analyzed to evaluate the differences among the three groups. Statistical significance was set at $\alpha=0.05$.

Results: The weight difference of Group VA was significantly larger than that of Group SWM ($p=0.004$). With regard to RMS values, no significant differences were observed among the groups ($p>0.05$).

Conclusion: Incorporating intraoral scanner-based mandibular movement data in the fabrication of single implant-supported single crowns may reduce the need for occlusal adjustments and contribute to more precise prosthesis fabrication.

Keywords: single implant-supported crown, intraoral scan, mandibular movement, computer-aided design, virtual articulator

Acknowledgement: This work was supported by the National Research Foundation of Korea (NRF) grant funded by the Korean government (MSIT) (No. 2020R1F1A1072370).

Physicochemical Properties and Bonding to Self-Adhesive Prosthetic Cement of Dentine Subjected to Microabrasive Blasting

Marcin Szerszeń¹, Julia Higuchi², Barbara Romelczyk-Baishya³, Witold Łojkowski², Zbigniew Pakieła³, Elżbieta Mierzwińska-Nastalska¹

(¹Department of Prosthodontics, Medical University of Warsaw, Warsaw, Poland; e-mail: mszerszen@wum.edu.pl; ²Laboratory of Nanostructures, Institute of High Pressure Physics, Polish Academy of Sciences, Warsaw, Poland; ³Faculty of Materials Science and Engineering, Warsaw University of Technology, Warsaw, Poland)

Objectives: Dental air abrasion is a simple cavity preparation technique that uses an air-abrasive jet. In recent years, tools have appeared, described as abrasive micro sandblasters. The use of micro-sandblasters in the procedure of tooth preparation, in addition to preparation with drills, for the final optimization of the surface is not a widely used method. The aim of the study was to obtain data on the effect of micro air abrasion on the properties of dentin.

Materials and methods: The study used 90 human third molars extracted for orthodontic or surgical reasons. The material was divided into three equinumerous sets of samples A, B and C (control). Groups A and B were subjected to abrasive blasting using an abrasive micro sandblasting device, using two gradations of aluminum oxide Al₂O₃ abrasive. The microgeometry, chemical composition, contact angle, surface free energy and mechanical strength of the dentine-cement connection were evaluated.

Results: Dentine preparation using air microabrasion modifies its surface structure by increasing the roughness parameters and contributes to the development of the adhesive surface. The aluminum oxide used in the micro-sandblasting procedure caused changes in the chemical composition of the top layer of dentine, which did not adversely affect the connection of the dentin with the cementing material. Abrasive blasting in the form of air microabrasion increases the wettability and surface free energy of the dentin. The differences between the groups, in all conducted quantitative test, were statistically significant.

Conclusions: Air microabrasion with the use of aluminum oxide with a gradation of 27 mm and 50 mm, through multi-factor positive reorganization of the treated surface, increases the bond strength of the dentin with self-adhesive prosthetic cement and can be recommended as a treatment optimizing the surface of the prepared dentin for the procedures of cementation of prosthetic restorations.