

Cracked Tooth Syndrome: Assessment, Prognosis and Predictable Management Strategies

Keywords

Dental Restoration
Dental Bonding
Cracked Tooth Syndrome
Dental Onlay

Authors

Thomas Gill ^{**}
(BSc(Hons) BDS (Hons) MJDF (RCS Eng),
PG Cert, FHEA)

Alexander J. Pollard [§]
(BSc(Hons) BDS MFDS RCS Ed PgDip
PgCert)

James Baker [^]
(BChD(Hons) MScConDent(Dist) MFDS
RCS(Eng))

Christopher Tredwin [†]
(BSc(Hons) BDS (Hons)
MScConsDent(Dist) PhD MFDS RCS(Eng)
FDS(RestDent)RCS FHEA)

Address for Correspondence

Thomas Gill ^{**}
Email: thomas.ksgill@gmail.com

^{*} Academic Clinical Fellow & Specialist Registrar
Restorative Dentistry, Royal London Hospital,
Whitechapel Rd, Whitechapel, London, E1 1FR

[†] Honorary Clinical Research Fellow, Centre of
Oral Bioengineering, Queen Mary University of
London, Whitechapel, London, E1 1FR

[§] Specialist Registrar Periodontology, University
Hospitals Bristol, University of Bristol Dental
School, Lower Maudlin St, Bristol BS1 2LY, UK

[^] Specialist in Fixed & Removable Prosthodontics,
55 Wimpole Street, London W1G 8YL

[†] Professor of Restorative Dentistry and Head
of Peninsula Dental School, Peninsula Dental
School, University of Plymouth, Drakes Circus,
Plymouth, PL4 8AA

Received: 07.10.2020
Accepted: 19.02.2021
doi: 10.1922/EJPRD_2232Gill09

ABSTRACT

Cracked tooth syndrome (CTS) is a common presentation in general practice. The diagnosis and management of teeth with CTS may be difficult due to the unknown extent of the crack. This article reviews the aetiology, diagnosis, management and prognosis of teeth with CTS. A thorough examination is required to effectively assess CTS. Intervention should aim to relieve symptoms and brace the remaining tooth structure effectively against further flexion. Restored teeth with CTS have a guarded prognosis due to the risk of further crack propagation, but the chances of survival at 5-years is acceptable (74.1-96.8%).

INTRODUCTION

Cracked Tooth Syndrome (CTS) often presents as an incomplete tooth fracture. This can be defined as a fracture plane of unknown depth and direction passing through tooth structure which, if not already involving, may progress to communicate with the pulp and or periodontal ligament.¹ Cracks in teeth can be grouped broadly into: craze lines, fractured cusp, cracked tooth, split tooth and vertical root fracture (Table 1).² Talim and Gohil (1974) developed a more detailed (or topographical/structure-based) classification which divided fractures into: fractures of enamel, fractures involving enamel and dentine without pulp involvement, fractures involving enamel and dentine with pulpal involvement and fractures of the root.³

Diagnosis and management of cracked tooth syndrome (CTS) can present a significant clinical challenge. This frequently occurring clinical presentation is most commonly associated with patients over 40 years old, and there is no clear evidence of gender being a related factor.⁴ CTS is relatively common with 4.4 posterior teeth per 100 adults experiencing cracks each year, these are approximately 2.4 times more likely to occur in molars than premolars.⁵ The most commonly involved teeth are mandibular second molars, mandibular first molars and maxillary first molars.⁶

CTS is three times more likely to occur in teeth where a preparation involving the marginal ridge has been necessary, compared to teeth with an occlusal restoration.⁷ Treatment of CTS can range from minor, requiring simple treatment to resolve, to severe requiring root canal treatment or possibly extraction. However, the decision as to which treatment option to select has often been a dilemma for dentists. It is the purpose of this paper to help practitioners in making diagnostic and treatment decisions which may result in more predictable outcomes in the management of CTS.

Table 1. Adapted from AAE 2008.² Classification of cracks in teeth.

Crack	Description
Craze Lines	These are visible fractures that only involve enamel. However, it is not always (or ever) possible to determine that a visible fracture is limited to enamel.
Fractured Cusps	This crack originates in the crown of the tooth, extends into dentine, and the fracture terminates in the cervical region. They are usually associated with large restorations and consequent unsupported cuspal enamel and dentine.
Cracked Tooth	This crack extends apically from the occlusal surface of the tooth without separation of the two segments.
Split Tooth	This crack extends through both marginal ridges, usually in a mesiodistal direction, splitting the tooth completely into two separate segments.
Vertical root fracture	This crack originates in the root and is generally complete, although they may be incomplete.

AETIOLOGY OF CRACKED TOOTH SYNDROME.

The aetiology of CTS is multifactorial and can be difficult to determine clinically, occurring in unrestored and restored teeth. Lynch *et al.*, (2002) described the causes as restorative procedures, occlusal factors, or other factors such as developmental conditions.⁸ One possible mechanism for CTS occurring more commonly in the ageing dentition is the structures of the tooth becoming more brittle and less elastic, making them more prone to cracks through exceeding the elastic potential of dentine.^{9,10} In unrestored teeth, cracks can occur due to excessive occlusal loads due to bruxism, or masticatory accidents such as biting on a hard object. It has also been proposed that affected teeth may have developmental weaknesses due to incomplete fusion of calcifying areas leading to a propensity to form cracks.¹¹

If wedging forces, for example from the mesio-palatal cusp of an upper tooth, are placed on both buccal and lingual cuspal inclines the resultant crack may occur in the midline of the tooth and propagate towards the pulp, especially in unrestored teeth. A tooth which has a relatively large restoration will tend to fracture more superficially and produce fewer or no symptoms.⁷

The most commonly affected tooth is the mandibular second molar.¹² This is thought to be due to higher loading as the result of the class II lever effect and their proximity to the fulcrum (temporomandibular joint). In addition, a plunger cusp is a common anatomical feature of the opposing maxillary second molar, which can create a central wedging force. Premature contacts or interferences can also result in larger forces being placed on these teeth. Other natural predisposing features include extensive attrition or abrasion, or anatomical factors such as the lingual inclination of the lingual cusps of mandibular molars and steep cusp angle of maxillary premolars.¹³ The susceptibility of posterior teeth to increased forces can be due to toothwear reducing the steepness of

excursive guidance of the anterior teeth. Additionally, the under-contouring of restorations in posterior teeth can lead to over-eruption and result in deeper intercuspation of the posterior teeth, which fail to disclude in lateral excursion of the mandible. During mastication, forces placed on teeth are comparatively low (70.6-146N)¹⁴ compared to maximal biting forces (98-715N).¹⁵ The force ratio of molars, premolars and incisors is thought to be 4:2:1.¹⁶ However, individuals can create much higher forces during nocturnal bruxism than conscious function, due to the cortical inhibitors being suppressed during sleep.¹⁷

Preparation of teeth for caries removal has been shown to reduce tooth rigidity.⁷ In addition, un-restored carious teeth have also been shown to be more prone to fracture.¹⁸ Lab based studies have shown that cuspal flexion under load becomes greater with increasing restorative preparation from sound tooth to MO to MOD restoration.¹⁹ As the cusp height doubles, due to the relative apical movement of the cavity floor during caries removal, the deflection will increase 8-fold.⁷ This results in microcracks which can propagate and lead to the development of cracked tooth syndrome. Choice of restorative technique can also be an important factor, for instance differences in the coefficient of thermal expansion between the restorative material and tooth can induce fractures.¹³ Restorative procedures that have been shown to be linked with crack formation include the placing of self-threading dentine pins, non-incremental use of composite resin, excessive hydraulic pressure when luting tight fitting indirect intra-coronal restorations, or placing amalgam with excessive condensation pressure.^{20,21}

PRESENTATION AND DIAGNOSIS

Cracked tooth syndrome commonly presents as a short sharp pain on biting that worsens on release, but cracked teeth may be asymptomatic leading to a delayed diagnosis. If this is the case, cracks can propagate to the pulp causing pulpitis, pulpal necrosis or catastrophic failure. Diagnosis is typically made from a detailed dental examination and pain history, and by excluding other causes.²²

Characteristic signs of cracked tooth syndrome include patients who clench, grind, or press their teeth together, especially in teeth with a wear facet into dentine. Additional signs of CTS include visible cracks on the distal surface of a tooth, and cracks that block transilluminated light.²³ Diagnosis of CTS is likely when patients report clenching or grinding their teeth, have pain symptoms consistent with CTS, and clinical examination reveals a molar with crack that blocks transilluminated light. In addition, a localized periodontal pocket in an otherwise healthy dentition is highly suggestive of a crack.²⁴ Kanamaru et al. (2017) found presence of a non-working side interference was commonly found in vital molars with CTS (38 out of 44 teeth).²⁵

A thorough examination (*Figure 1*) should always be carried out but often cracks are not visible. Inspection of the tooth using magnification and rubber dam isolation can aid diagnosis. Vitality (sensitivity) of the tooth should be confirmed through two methods, typically cold testing and electric pulp tester (EPT). If the patient is symptomatic an attempt to elicit these symptoms should be made to confirm diagnosis. Pressure should be applied to the tooth with a crack finding tool. Utilisation of a crack finding tool is the most specific method to identify the symptomatic tooth as it can be applied to a single cusp and if symptoms are induced, specifically on release, it is a strong indicator of cracked tooth syndrome. Transillumination is another useful method to detect cracks. A curing light is shone towards the tooth from different angles, light will not usually be propagated beyond the fracture line. It should be noted that teeth with deep fissures can also prevent light propagation so the anatomy of the tooth should be considered. If cracked tooth syndrome is suspected, it is advisable to remove any restorations under rubber dam and high magnification to assess the remaining tooth structure and the floor of the cavity for cracks. At this stage an assessment of the tooth's restorability can be made (*Figure 2*).

MANAGEMENT OF CRACKED TEETH

Once a diagnosis of a CTS is made, the management of these teeth should be based clinically on pulp status, restorability of the remaining tooth structure, and the patient's wishes.

A thorough occlusal examination should be undertaken (as part of the diagnosis stage), which should include checking of the static and dynamic occlusion, as well as slides from retruded contact position (RCP) to the position of maximum intercuspation (ICP). When restoring teeth ICP contacts should be maintained to prevent an unplanned change in the occlusal scheme. However, damaging shearing forces can be avoided by planning restorations on non-guiding teeth to disclude on lateral and protrusive excursions of the mandible. The use of articulated study casts will help with planning restorations in cracked teeth.

In CTS, the aims of treatment should be to stabilise the remaining tooth structure to prevent further crack propagation which could result in pulpal communication or catastrophic failure of the tooth. In the first instance, the tooth should undergo a 'provisionalisation' treatment stage where the effect of the intervention on vitality and clinical symptoms are monitored. If the tooth is necrotic or has irreversible pulpitis, and has been checked under high magnification to exclude the possibility of a crack having propagated over the pulpal floor or into the roots, then the transition to the definitive restorative stage can be immediate (*Figure 3 and Figure 4*) after completing root canal treatment.

In a cracked tooth, some cusps may be undermined leading to weakness. Lateral pressure can be applied to the cusp to see if it fractures away. Cusps should be reduced so that they are approximately 2mm at their thinnest point.²⁶ Selective enameloplasty can be used to modify plunger cusps, or steep inclines of guiding cusps, prone to excursive forces, in order to minimise the forces on the cracked tooth. However, careful

Definitive Restoration of Cracked Tooth Syndrome Tooth

Full Coverage Materials:

- Gold,
- Non-precious metal,
- Monolithic Zirconia
- Monolithic Lithium disilicate
- Feldspathic Porcelain

Where possible gold is the preferred material, aesthetics allowing, due to the minimal thickness for its preparation. Monolithic restorations are preferable with appropriate staining where aesthetic requirements are higher. Porcelain bonded crowns may be considered where metal is utilised on the palatal and occlusal surfaces with buccal veneering porcelain.

Direct Overlay materials:

- Composite,
- Amalgam

Achieving biomechanical stability of the crown is aim of the definitive restoration. Therefore sufficient thickness must be achieved to ensure bracing of the tooth structure. Using direct materials may require the most preparation of tooth to achieve this.

Indirect Overlay materials:

- Gold,
- Non-precious metal
- Lithium disilicate
- Composite

Consider ability to achieve adhesive restoration and plan appropriate retention as needed. Consider discussing with laboratory thickness required to achieve aesthetic requirements.

Occlusal Considerations:

- If the tooth has been restored to the appropriate form in the provisional stage. This can be recorded and can be transferred for the definitive restoration.
- When the tooth is the first contact in RCP aim to maintain this through restoration to avoid uncontrolled equilibration and possible need for further preparation.
- Where possible maintain hold in ICP and disocclusion in dynamic movements.
- If involved in protrusive movements consider incorporating long centric design for crown.

Figure 1: Diagnostic assessment for Cracked Tooth Syndrome.

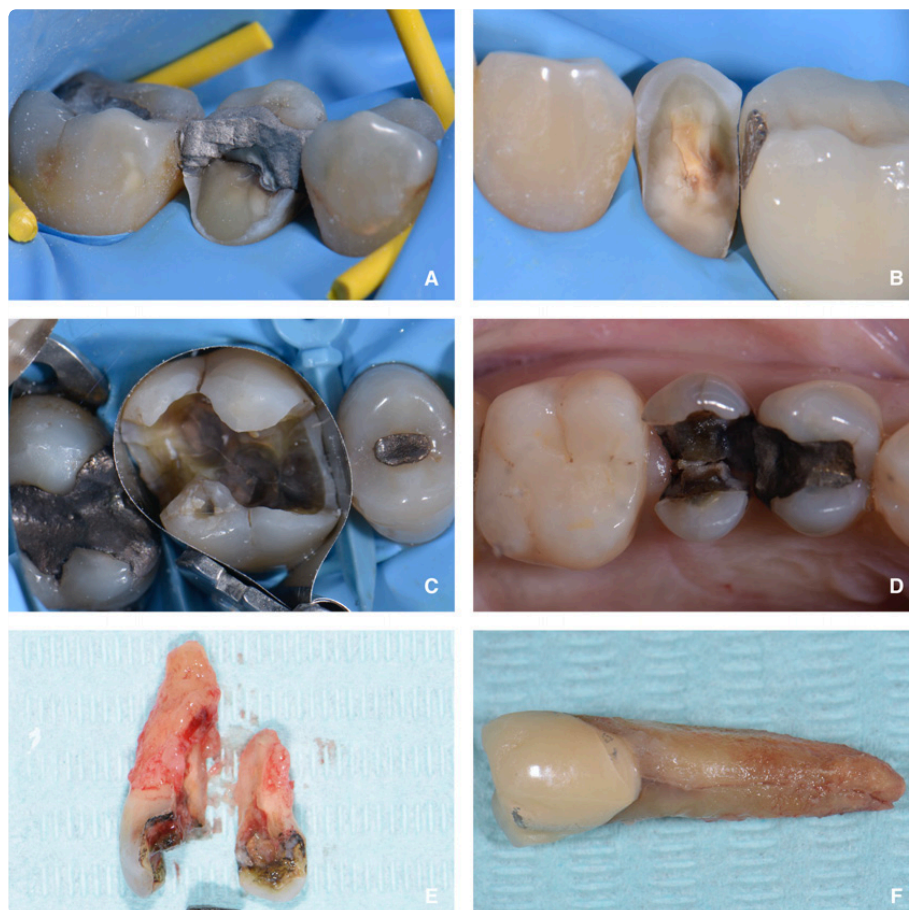

Figure 2: Cracked teeth. A) Tooth 45 presenting with buccal cusp fracture. B) Tooth 35 presenting with buccal cusp fracture also showing lingual cusp crack. C) Tooth 16 showing occlusal view of cracks. D) Occlusal view of subgingivally fractured 15. E - Tooth 15 extracted showing fracture to apical third of the tooth. F) Vertical Root fracture.

planning and consent is necessary if any occlusal modification is begin considered, especially if this involves adjustments to teeth not immediately effected by pathology.

In an unrestored tooth it may be advisable to place an orthodontic band²⁷ or composite splint.²⁸ The direct composite splint (DCS) is a directly bonded overlay, in supraocclusion, applied to a tooth with suspected CTS as a diagnostic tool.²⁹ A published audit of 151 CTS teeth treated with DCS showed that approximately 87% of the splints were successful at 3-months, and that the restorations were surprisingly well tolerated.²⁹ If placement of an orthodontic band or DCS resolves the patient’s symptoms then this can be considered confirmation of a diagnosis of CTS. Further, if the tooth remains asymptomatic it can then be predictably restored with a cuspal coverage restoration. However, if vitality remains unclear the tooth can be prepared, and a long-term provisional crown can be constructed (Composite or Polymethyl Methacrylate [PMMA]) to be placed with a temporary cement. It is essential to avoid eugenol containing temporary cements for this phase as the obtundent (sedative) effect on the pulp may mask underlying symptoms of pulpitis. After a period of monitoring nerve sensibility (the authors recommend 3-months asymptomatic whilst maintaining nerve vitality) a definitive restoration can be provided, or if indicated root canal treatment (RCT) can be completed prior to definitive restoration.

The choice of definitive treatment will depend on crack position, remaining tooth structure, type of restoration to be provided and patient preference. In a tooth with sufficient ferrule, a crown transfers the stresses of occlusal forces to the tooth structure circumscribed by the margin of the crown. If the crown is biomechanically stable this should increase the stability of the crack.³⁰ Whilst the ‘chasing out’ of cracks is debated in the literature, there is no convincing evidence that this practice improves outcomes,³¹ but where possible crown margins should be placed on sound tooth tissue.³²

The definitive restoration should provide cuspal coverage²⁵ and can be direct³¹ (Figure 5) or indirect (Figure 6 and Figure 7).³³ In teeth where symptoms are due to a cuspal base fracture the tooth can be restored with a partial coverage cuspal onlay restoration. However, in teeth where there is a central crack, we would advocate a full coverage restoration due to the previously mentioned need to increase the tooth’s biomechanical stability. The authors recommend gold as the material of choice due to superior biocompatibility and structural properties, along with minimal preparation being required. However, several tooth coloured materials also exist, and the decision will be patient and dentist derived after discussion of the risks and benefits.

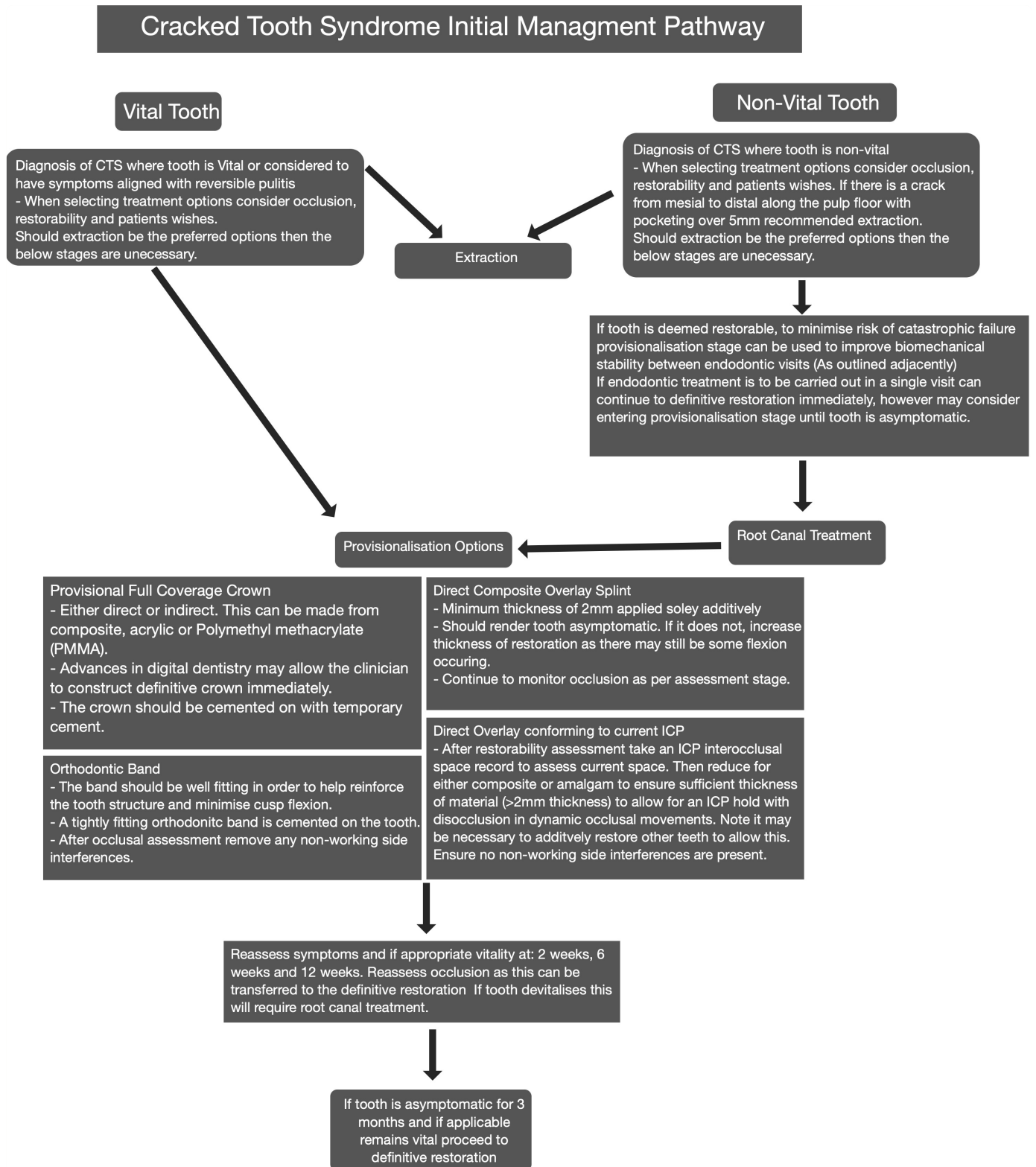


Figure 3: Initial management of cracked tooth.

Following restoration, patients with CTS will need their occlusion monitored and protected from parafunctional loads and an appropriately constructed splint (Figure 8) should be provided after delivery of the final restoration. Particularly if there is any concern regarding parafunction. It is not the remit of this paper to discuss splint design but Jagger and King (2018) give a considered overview of considerations on this topic.³⁴

PROGNOSIS OF CRACKED TEETH

Teeth diagnosed with CTS and reversible pulpitis, in the absence of a cuspal coverage are associated with over 8 times higher risk of pulp complications. Therefore, it is essential to brace cracked teeth to minimise flexion and crack propagation. When treated early, these teeth have been shown to maintain vitality in 71%

Definitive Restoration of Cracked Tooth Syndrome Tooth

Full Coverage Materials:

- Gold
- Non-precious metal
- Monolithic Zirconia
- Monolithic Lithium disilicate
- Feldspathic Porcelain

- Where possible gold is the preferred material, aesthetics allowing, due to the minimal thickness for it's preparation. Monolithic restorations are preferable with appropriate staining where aesthetic requirements are higher. Porcelain bonded crowns may be considered where metal is utilised on the palatal and occlusal surfaces with buccal veneering porcelain.

Direct Overlay materials:

- Composite
- Amalgam

- Achieving biomechanical stability of the crown is aim of the definitive restoration. Therefore sufficient thickness must be achieved to ensure bracing of the tooth structure. Using direct materials may require the most preparation of tooth to achieve this.

Indirect Overlay materials:

- Gold
- Non-precious metal
- Lithium disilicate
- Composite

- Consider ability to achieve adhesive restoration and plan appropriate retention as needed. Consider discussing with laboratory thickness required to achieve aesthetic requirements.

Occlusal Considerations:

- If the tooth has been restored to the appropriate form in the provisional stage. This can be recorded and can be transferred for the definitive restoration.
- When the tooth is the first contact in RCP aim to maintain this through restoration to avoid uncontrolled equilibration and possible need for further preparation.
- Where possible maintain hold in ICP and disocclusion in dynamic movements.

Figure 4: Definitive restoration of a cracked tooth.

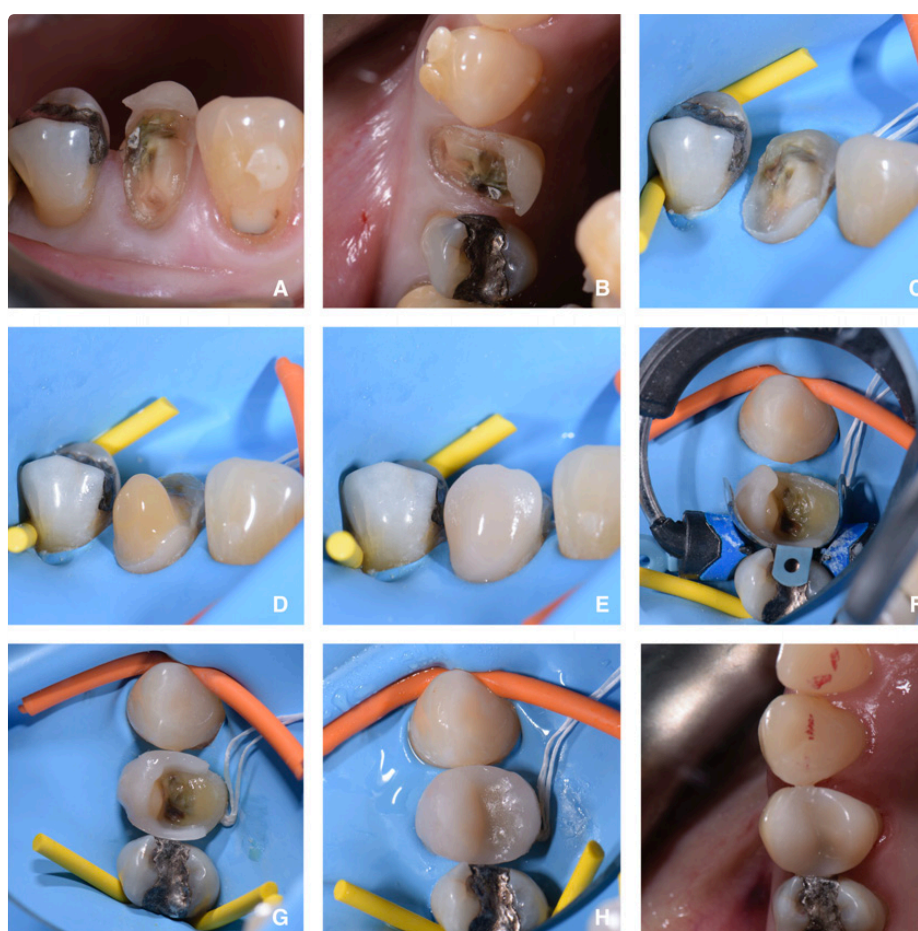


Figure 5: Direct composite onlay fractured 14. A) Initial presentation of 14 buccal cusp fracture, buccal view. B) Initial presentation of 14 buccal cusp fracture, occlusal view. C) Rubber dam isolation with lingual cusp reduction. D) Dentine cusp build up in composite. E) Enamel buccal cusp composite build up. F) Occlusal view of 14 with sectional matrix in place. G) Mesial and distal marginal ridges built up, occlusal view. H) Direct composite onlay 14. I) 14 direct composite overlay, occlusal view.

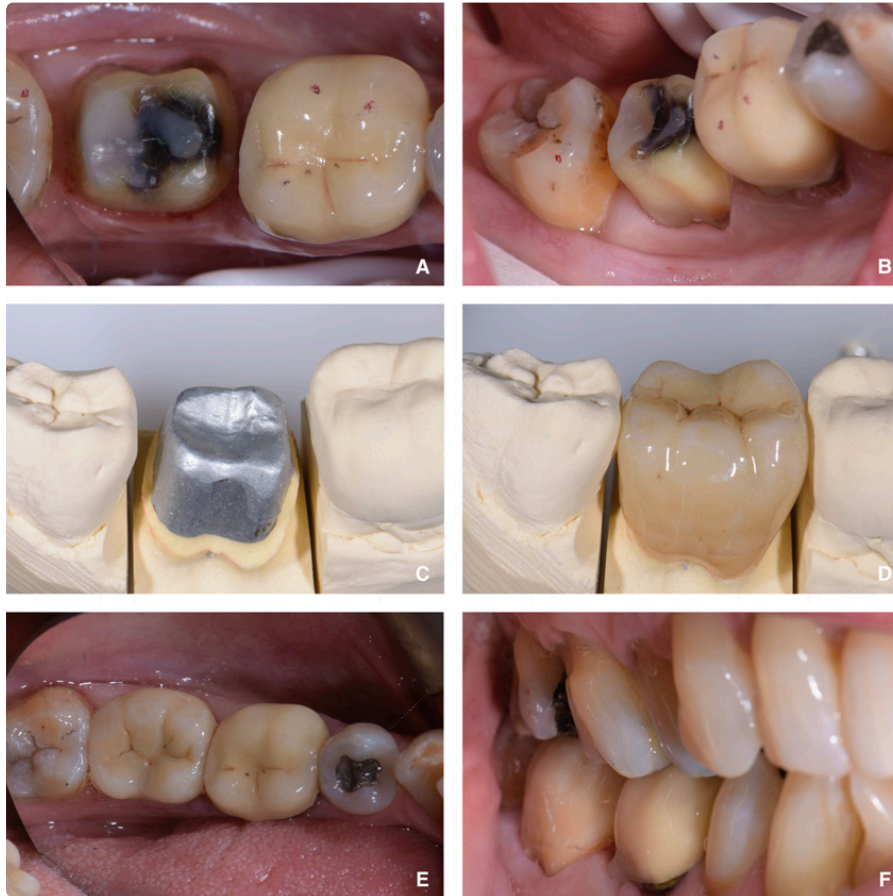

Figure 6: Previously diagnosed Cracked Tooth Syndrome 47 with full coverage crown. A) Occlusal view 47. B) Buccal view 47. C) 47 working die. D) 47 zirconia crown on cast. E) Occlusal view of restored 47. F) Buccal view restored 47.

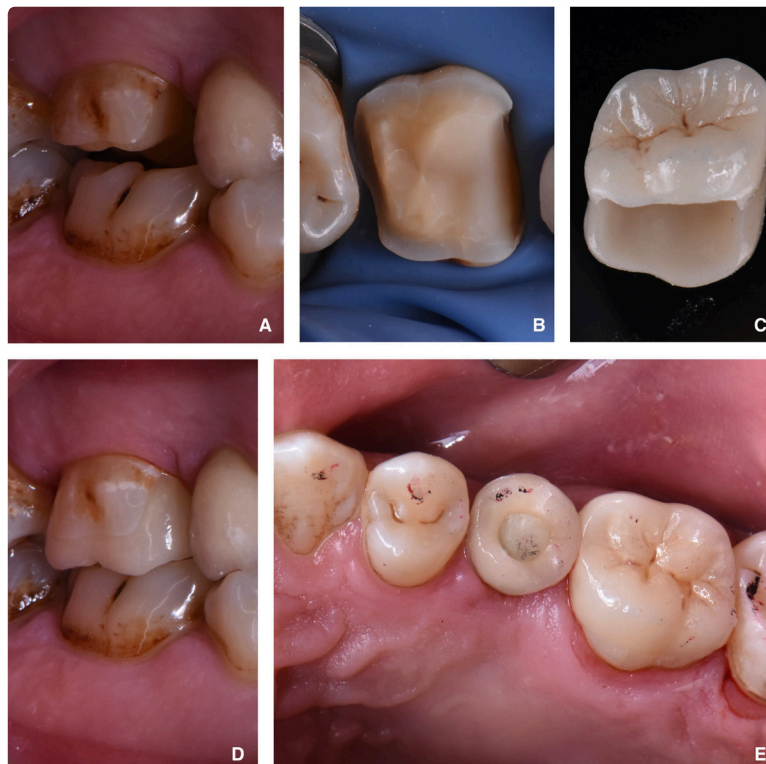

Figure 7: Indirect cuspal coverage 16. A) Buccal view of UR6 prepared for lithium disilicate onlay. B) Occlusal view of isolated 16. C) Lithium disilicate onlay. D) Buccal view restored 16. E) Occlusal view restored 16.

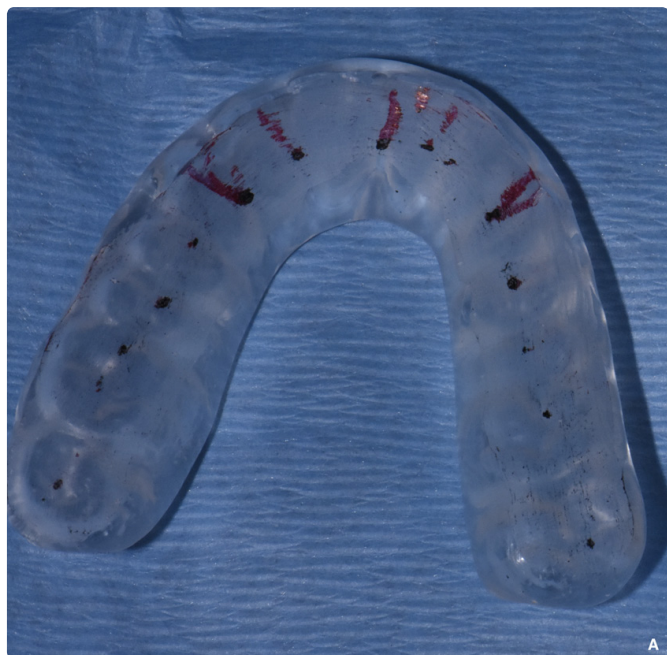

Figure 8: Michigan Splint with static and dynamic occlusion.

cases at 3 years.³⁵ However, research methodologies are variable and other studies have found much lower maintenance of vitality in treated teeth, some as low as 20%.³⁶ The literature shows that the proportion of teeth requiring root canal treatment is greater when there is an associated deep periodontal probing depth corresponding to a crack. Krell and Caplan (2018) found the key prognostic factors negatively associated with survival to be: distal marginal ridge crack, periapical diagnosis such as chronic periapical periodontitis, and pocketing depth over 5mm in the fracture line.⁶

Teeth with cracks extending onto the pulpal floor often require extraction (odds ratio = 4.5, P = 0.07), and multivariable analyses found that extension of cracks onto the pulpal floor independently increased the odds of tooth loss 11-fold (odds ratio = 11, P = 0.033), with other factors being held constant.³⁷ The 5-year survival estimate in the absence and presence of crack extension onto the pulpal floor was 99% and 88%, respectively.³⁷ Chen *et al.* (2017) found that visual cues can help to predict crack severity and showed that the larger the length of crack on the occlusal surface the longer the length of crack on the proximal surface and concluded that both length and width of crack on the occlusal surface are useful predictors of whether the crack involves the root.³⁸ However, the factor most consistently related to failure was having an isolated probing pocket depth of more than 5 mm in the line of suspected fracture.^{36,39,40} Clearly, probing pocket depths must be considered in the context of the patient’s general periodontal status.

There is debate regarding whether root canal therapy or extraction is the most appropriate treatment when a diagnosis of pulpal necrosis is considered. Berman and Kuttler (2010) have argued that extraction should be recommended in cracked teeth with necrotic pulps and minimal restorations, because of variability in outcomes.⁴¹ However, the authors suggest that if there are not probing pocket depths ≥ 5 mm

and a full coverage restoration is placed during and after root canal treatment, these teeth have a reasonable (74.1-96.8%) chance of survival at 5 years.⁴⁰ Krell and Caplan (2018) suggested a staging based on clinical findings which gave a prognostic outcome of success at 12 months (Table 2).⁶

Table 2. Adapted from Krell and Caplan (2018) 6-Prognostic outcomes of treated cracked tooth based on initial presentation.

IOWA staging Index	Description
Stage	
IOWA Stage 1	no pocketing over 5mm and no crack across the distal ridge (37% of teeth 93% success)
IOWA Stage 2	no probing pocket depths ≥ 5 mm, having a crack across the distal marginal ridge, and not having a periapical diagnosis of CAP/SAP/AAA (39% of teeth, 84% success)
IOWA Stage 3	no probing pocket depths ≥ 5 mm, having a crack across the distal marginal ridge, and having a periapical diagnosis of CAP/SAP/AAA (15% of teeth, 69% success)
IOWA Stage 4	≥ 1 mesial or distal probing pocket depth ≥ 5 mm (8% of teeth, 41% success).

CONCLUSION

Cracked tooth syndrome can be difficult to diagnose. Unfortunately, in dentistry no two presentations are the same and the diagnosis may not be entirely apparent. Understandably, clinicians may be concerned about undertaking irreversible, as well as biologically and financially costly steps for the management of such teeth. However, teeth with CTS have been shown to have encouraging success rates when treated early. In cases where a diagnosis is unclear, it is sensible to remove any interferences and place either an orthodontic band or direct composite splint. Then, once a diagnosis is confirmed the tooth should be prepared for direct or indirect cuspal coverage to prevent further flexion of the tooth. The superiority of full coverage versus more conservative treatments such as adhesive onlays is not clear in the literature. A balance between conservation of structure, maintenance of vitality, and the ability to brace and prevent flexion in the remaining tooth structure needs to be achieved.

In CTS, if a crack runs from the mesial to distal, especially in minimally restored tooth, the authors of this paper would give strong consideration to full coverage crown restoration. In cases where symptoms are due to a fractured cusp then a partial onlay restoration is more appropriate, depending on the restorative status of the tooth. The associated risks of loss of tooth vitality will need to be discussed with the patient. Patients who have

experienced CTS should have a thorough occlusal assessment and if appropriate establishment of protective anterior guidance and provision of a hard Michigan-type splint may be indicated.

Teeth diagnosed with cracked tooth syndrome do have a guarded prognosis but have been shown to have relatively high survival/success rates at 5-years when managed appropriately. However, in the presence of probing depths over 5mm and cracks across both marginal ridges these teeth have a poorer prognosis. In such cases, the patient should be made aware that it may not possible to predictably restore this tooth, and a conversation regarding the management of the resultant space may be required.

REFERENCES

- Ellis, S.G. Incomplete tooth fracture—proposal for a new definition. *Br Dent J* 2001; **190**:424-428.
- American Association of Endodontics. *Cracking the Cracked Tooth Code: Detection and Treatment of Various Longitudinal Tooth Fractures*. 2008 <https://www.aae.org/specialty/wp-content/uploads/sites/2/2017/07/ecfesum08.pdf>
- Talim, S.T. and Gohil, K.S. Management of coronal fractures of permanent posterior teeth. *J Prosthet Dent* 1974; **31**:172-178.
- Roh, B. and Lee, Y. Analysis of 154 cases of teeth with cracks. *Dent Traumatol* 2006; **22**:118-123.
- Bader, J., Martin, J. and Shugars, D. Incidence rates for complete cusp fracture. *Community Dent Oral Epidemiol* 2001; **29**:346-353.
- Krell, K.V. and Caplan, D.J. 12-month Success of Cracked Teeth Treated with Orthograde Root Canal Treatment. *J Endod* 2018; **44**:543-548.
- Homewood, C.I. Cracked tooth syndrome—incidence, clinical findings and treatment. *Aust Dent J* 1998; **43**:217-222.
- Lynch, C.D. and McConnell, R.J. The cracked tooth syndrome. *J Can Dent Assoc* 2002; **68**:470-475.
- Yahyazadehfar Mobin, Zhang Dongsheng and Arola Dwayne. On the Importance of Aging to the Crack Growth Resistance of Human Enamel. *Acta Biomaterialia* 2016; **32**:264-274.
- Nazari, A., Bajaj, D., Zhang, D., Romberg, E. and Arola, D. Aging and the reduction in fracture toughness of human dentin. *J Mech Behav Biomed Mater* 2009; **2**:550-559.
- Hasan, S., Singh, K. and Salati, N. Cracked tooth syndrome: Overview of literature. *Int J Appl Basic Med Res* 2015; **5**:164-168.
- Hiatt, W.H. Incomplete crown-root fracture in pulpal-periodontal disease. *J Colo Dent Assoc* 1975; **53**:4-15.
- Lubisich, E.B., Hilton, T.J. and Ferracane, J. Cracked teeth: a review of the literature. *J Esthet Restor Dent* 2010; **22**:158-167.
- Anderson, D.J. Measurement of stress in mastication. I. *J Dent Res* 1956; **35**:664-670.
- Helkimo, E., Carlsson, G.E. and Helkimo, M. Chewing efficiency and state of dentition. A methodologic study. *Acta Odontol Scand* 1978; **36**:33-41.
- Arnold, M. Bruxism and the occlusion. *Dent Clin North Am* 1981; **25**:395-407.
- Attanasio, R. Nocturnal bruxism and its clinical management. *Dent Clin North Am* 1991; **35**:245-252.
- Goel, V.K., Khera, S.C., Gurusami, S. and Chen, R.C. Effect of cavity depth on stresses in a restored tooth. *J Prosthet Dent* 1992; **67**:174-183.
- Hood, J.A. Biomechanics of the intact, prepared and restored tooth: some clinical implications. *Int Dent J* 1991; **41**:25-32.
- Trushkowsky, R. Restoration of a cracked tooth with a bonded amalgam. *Quintessence Int* 1991; **22**:397-400.
- Nguyen, V. and Palmer, G. A review of the diagnosis and management of the cracked tooth. *Dent Update* 2009; **36**:338-346.
- Kahler, W. The cracked tooth conundrum: terminology, classification, diagnosis, and management. *Am J Dent* 2008; **21**:275-282.
- Hilton, T.J., Funkhouser, E., Ferracane, J.L., Gilbert, G.H., Baltuck, C. Benjamin, P., et al. Correlation between symptoms and external characteristics of cracked teeth: Findings from The National Dental Practice-Based Research Network. *J Am Dent Assoc* 2017; **148**:246-256.e1.
- Mathew, S., Thangavel, B., Mathew, C.A., Kailasam, S., Kumaravadevel, K. and Das, A. Diagnosis of cracked tooth syndrome. *J Pharm Bioallied Sci* 2012; **4**:S242-S244.
- Kanamaru, J., Tsujimoto, M., Yamada, S. and Hayashi, Y. The clinical findings and managements in 44 cases of cracked vital molars. *J Dent Sci* 2017; **12**:291-295.
- Elayouti, A., Serry, M.I., Geis-Gerstorfer, J. and Löst, C. Influence of cusp coverage on the fracture resistance of premolars with endodontic access cavities. *Int Endod J* 2011; **44**:543-549.
- Ehrmann, E.H. and Tyas, M.J. Cracked tooth syndrome: diagnosis, treatment and correlation between symptoms and post-extraction findings. *Aust Dent J* 1990 Apr; **35**:105-112.
- Banerji, S., Mehta, S.B. and Millar, B.J. Cracked tooth syndrome. Part 2: restorative options for the management of cracked tooth syndrome. *Br Dent J* 2010 Jun; **208**:503-514.
- Banerji, S., Mehta, S.B., Kamran, T., Kalakonda, M. and Millar, B.J. A multi-centred clinical audit to describe the efficacy of direct supra-coronal splinting—a minimally invasive approach to the management of cracked tooth syndrome. *J Dent* 2014 Jul; **42**:862-871.
- Mamoun, J.S. On the ferrule effect and the biomechanical stability of teeth restored with cores, posts, and crowns. *Eur J Dent* 2014 Apr; **8**:281-286.
- Mamoun, J.S. and Napoletano, D. Cracked tooth diagnosis and treatment: An alternative paradigm. *Eur J Dent* 2015 Apr-Jun; **9**:293-303.
- Sharma, A., Rahul, G.R., Poduval, S.T. and Shetty, K. Short clinical crowns (SCC) - treatment considerations and techniques. *J Clin Exp Dent* 2012 Oct; **4**:230.
- Lin, C., Chang, Y., Hsieh, S. and Chang, W. Estimation of the failure risk of a maxillary premolar with different crack depths with endodontic treatment by computer-aided design/computer-aided manufacturing ceramic restorations. *J Endod* 2013 Mar; **39**:375-379.
- Jagger, R. and King, E. Occlusal splints for bruxing and TMD - A balanced approach? *Dental Update* 2018; **45**:912-918.
- Wu, S., Lew, H.P. and Chen, N.N. Incidence of Pulpal Complications after Diagnosis of Vital Cracked Teeth. *J Endod* 2019; **45**:521-525.
- Kim, S., Kim, S., Cho, S., Lee, G. and Yang, S. Different treatment protocols for different pulpal and periapical diagnoses of 72 cracked teeth. *J Endod* 2013; **39**:449-452.
- Sim, I.G.B., Lim, T., Krishnaswamy, G. and Chen, N. Decision Making for Retention of Endodontically Treated Posterior Cracked Teeth: A 5-year Follow-up Study. *J Endod* 2016; **42**:225-229.
- Chen, M., Fu, K., Qiao, F., Zhang, X., Fan, Y., Wang, L., et al. Predicting extension of cracks to the root from the dimensions in the crown: A preliminary *in vitro* study. *J Am Dent Assoc* 2017; **148**:737-742.
- Tan, L., Chen, N.N., Poon, C.Y. and Wong, H.B. Survival of root filled cracked teeth in a tertiary institution. *Int Endod J* 2006; **39**:886-889.
- Kang, S.H., Kim, B.S. and Kim, Y. Cracked Teeth: Distribution, Characteristics, and Survival after Root Canal Treatment. *J Endod* 2016; **42**:557-562.
- Berman, L.H. and Kuttler, S. Fracture necrosis: diagnosis, prognosis assessment, and treatment recommendations. *J Endod* 2010; **36**:442-446.