

Comparison of the Effect of Ovariectomy on Bone Mass in Dentate and Edentulous Mandibles of Adult Rats

Emad S. Elsubeihi* and Johan N.M.Heersche†

Abstract - We investigated the effect of ovariectomy (OVX) on bone changes in the edentulous and dentate mandibles and compared these to changes in tibiae and femorae using dual energy x-ray absorptiometry (DEXA) and histomorphometric measurements. One hundred and fifteen female rats had their molars and the incisor on one side of the mandible extracted at six months of age and allowed to heal for 4 months. At 10 months of age, animals were divided into an experimental group, which underwent bilateral ovariectomy, and a control group of intact animals. Sixteen OVX and sixteen control animals were sacrificed at 6-weeks, and at 6- and 9-months post-OVX. In addition 12 animals were sacrificed at the time of OVX to act as an internal control group. Bone mineral density measurements (BMD) using DEXA and bone volume measurements on undecalcified sections evaluated under backscattered electron microscopy were investigated in the edentulous and dentate mandibles as well as in tibiae and femorae. At 6-weeks post-OVX, there were no significant differences between the edentulous mandibles, dentate mandibles, tibiae and femorae of OVX and control groups. At 6 months post-OVX, BMD and cancellous bone volume were significantly decreased in the edentulous mandibles (-15.9%; -21.8%), proximal tibiae (-15.6%; -38.5%) and proximal femorae (-9.7%; -39.6%) of OVX group as compared to the control group. At 9 months post-OVX, BMD and cancellous bone volume were further decreased in the edentulous mandibles (-17.2%; -24%), proximal tibiae (-16.1%; -58.9%) and proximal femorae (-10.3%; -49.9%) of the OVX group as compared to the control group. On the other hand, OVX had no effect on the BMD and cancellous bone volume of the dentate mandibles at 6-weeks and at 6- and 9-months post-OVX. These results show that loss of bone mass in the edentulous mandible of OVX animals is similar to that occurring in the tibiae and femorae, while lack of a significant effect of OVX on bone mass in the dentate mandible suggests that functional loading related to biting force prevented bone loss in the dentate mandible.

KEY WORDS: mandible, dentate, edentulous, osteoporosis, ovariectomy.

INTRODUCTION

Because fractures as a result of postmenopausal osteoporosis do not occur in the human mandible, studies investigating the effect of postmenopausal osteoporosis on mandibular bone have generally relied on relating changes in bone mass in different skeletal sites to changes in a range of mandibular variables such as the height of residual ridge, reduced bone density or altered cortical pattern using indices measured on conventional radiographs such as the gonion index, the panoramic mandibular index or the mandibular cortical index. While some studies have found a correlation between bone changes in the edentulous mandible and changes in bone mass in the spine, the neck of the femur and/or the forearm, others did not detect such a correlation^{1,2}. Importantly, histomorphometric evaluation of biopsies from patients with severe residual ridge resorption of the mandible revealed that mineralization defects and secondary hyperthyroidism rather than osteoporosis are more often the cause of decrease in bone mass in the mandible^{3,4}. Thus studies relying on radiographic techniques alone have yielded

conflicting results due to lack of complete reproducibility of measurements, differing regions of the mandible studied and various measurements techniques¹. In addition, the lack of control for other confounding factors such as complete or partial edentulism, time of tooth loss and wearing of dentures further contributes to the conflicting results of the human studies on bone changes in the edentulous mandible². Studies using animal models have also yielded conflicting results: some investigators have reported that ovariectomy (OVX) has no effect on the dentate mandible^{2,5-8} and the dentate maxillae⁹, while others^{10,11} found that OVX resulted in reduction of trabecular bone volume of dentate mandibles of rats. Following bilateral extraction of the mandibular incisors, Cao et al.,¹² found that OVX caused a reduction in cancellous bone mineral density (BMD) of the edentulous part of the mandible of rabbits, while cortical BMD was not affected.

The aim of the present study was to investigate the effect of OVX on bone changes in the edentulous and dentate mandibles of adult rats and compare these to changes in tibiae and femorae using dual energy x-ray absorptiometry (DEXA) and histomorphometric measurements. We focused in particular on the differences between OVX-induced bone changes in dentate and edentulous mandibles in view of the possible contribution of the effect of biting forces on mandibular bone loss.

* BDS MSc PhD

† PhD

MATERIALS AND METHODS

115 female Sprague-Dawley rats were obtained at 3 months of age (Charles River, Quebec, Canada) and kept until they were 6 months of age. At 6 months of age the mandibular molars and the incisor on one side of the mandible were extracted and allowed to heal for 4 months as we described previously¹³.

Four months after teeth extraction, the animals were randomly divided into an experimental and a control group. The experimental group underwent bilateral OVX using a dorsal approach¹⁴. Ovariectomy was confirmed by histological examination of the tissue removed. Because evidence in the literature indicates that there are no differences in mechanical and histomorphometric parameters of bone between sham operated and intact animals¹⁵, we decided to use intact animals as a control group. After OVX, experimental and control animals were housed individually and pair fed throughout the rest of the experiment.

12 control animals were sacrificed at the time of OVX. 16 control and 16 OVX animals were sacrificed at 6 weeks, 6- and 9-months post-OVX. Edentulous and dentate mandibles as well as femorae and tibiae were dissected and fixed in 10% neutral buffered formalin for 24 hours, then stored in 70% alcohol until processed further. During the course of the experiment 6 animals were lost prematurely as a result of mammary tumours and respiratory infections.

Specimen preparation

The mandibles were split at the midline suture and all edentulous mandibles were screened for the presence of remaining roots using radiographs. Nine animals were excluded because of the presence of root fragments. Thirteen to fourteen animals in each group remained for analysis. First, BMD measurements were carried out on all animals using DEXA. The bones of 6-8 animals in each group were then prepared for morphological examination of 100 µm thick undecalcified sections using backscattered electron microscopy.

Assessment of bone changes using DEXA

BMD were measured using DEXA (Hologic QDR 4500 Elite series Bone Densitometer, Hologic Inc., Bedford, MA, USA) with the machine in Small Animal Appendicular mode using the ultrahigh resolution software program. During scanning, the position of the mandibles was standardized as we described previously¹³. Dentate mandibles were scanned with teeth and rescanned after removal of teeth. Tibiae and femorae were oriented such that the X-rays penetrated in an anterior-posterior direction, with the anterior side facing up.

On the resultant scans the whole edentulous mandible then the body of the mandible (defined as the area of the mandible anterior to the notch created by the insertion of the masseter muscle and incisure of facial vessels at the lower border of the mandible) was analysed. Tibiae and femorae were analyzed in their entirety followed by analysis of the proximal part only (defined as 25% of the total length of each tibia or femur measured from the proximal end).

Fourteen samples of each bone were scanned on three separate occasions and the percent coefficient of variation (CV %) for each bone calculated.

Assessment of bone changes using backscattered electron microscopy

Bone sections from 6-8 animals in each group were prepared for evaluation by backscattered electron microscopy. For the mandibles the mental and mandibular foramina were filled with dental amalgam before embedding. The specimens were then dehydrated in ascending concentrations of acetone and embedded in Spurr (Polysciences, PA, USA). To facilitate proper orientation during sectioning, we subsequently made four holes in each acrylic block using a round bur in a dental hand-piece and filled these with dental amalgam before taking a radiograph. Mandibular blocks were sectioned perpendicular to a line drawn between the mental and the mandibular foramina using a diamond blade mounted on low speed saw. The first section was made 3 mm posterior to the mental foramen, followed by ten 100 µm sections (Fig 1-A). Every fourth section, starting with the first section, was then polished with silicon paper and scanned using backscattered electron microscopy (Hitachi S-2500) at 100X magnification.

The proximal tibiae and femorae were similarly embedded in Spurr and the blocks were ground using coarse silicone papers until the marrow cavity was uniformly exposed (about 1/3 the thickness of the proximal part of the bone), polished with fine silicone paper and scanned using backscattered electron microscopy at 100X magnification. Following this, the surface was glued onto a glass slide using epoxy resin and a 100µm thick longitudinal section cut, polished and scanned again, resulting in 2 surfaces scanned for each tibia and femur.

The images of the backscattered electron microscopy scans were analyzed using image analysis software (Sigma Scan Pro version 4). For the mandible, we first analyzed whole sections of each edentulous and dentate mandible (excluding tooth sockets when analyzing dentate mandibles) and the total bone volume was obtained (Fig 1-B). This was followed by measurement of the total and cancellous bone volume in the area located above the level of the incisor (Fig 1-C). To standardize this area in the edentulous mandible, the area occupied by the incisor in the corresponding section of the contra-lateral dentate mandible was superimposed on the edentulous mandible. Cancellous bone volume was measured in an area 1.7 mm high starting 500µm above the incisor location (Fig 1-C). Cortical bone was considered to be the area delineated by the periosteal surface at the outside and the endosteal surface of the first marrow cavity closest to the cortex¹⁶. Cortical bone volume was measured by subtracting the cancellous bone volume from the total bone volume. Cancellous bone porosity was calculated as area of marrow spaces in the cancellous bone.

Cancellous bone volume of the proximal tibia was measured starting at 500µm below the growth plate and extending for 3 mm downward excluding the cortical bone. For the proximal femorae, cancellous bone volume was measured starting at 500µm distal to the growth plate and extending to the junction of the greater and lesser trochanter.

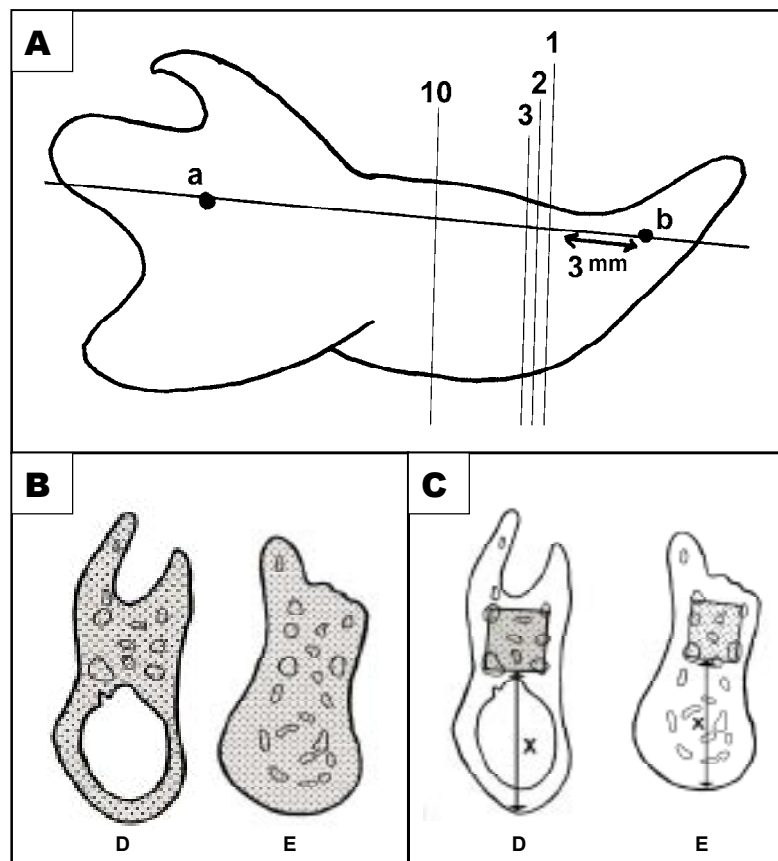


Figure 1. Diagram illustrating site of sections and definitions of areas measured on backscattered images of the edentulous and dentate mandibles. A; Ten successive sections on each mandible were made perpendicular to a line drawn between the mandibular (a) and the mental (b) foramina. The distance between adjacent sections was 100 μ m and every fourth section, starting with the first section, were selected for measurements. The first section was made 3 mm posterior to the mental foramen. B; shaded parts used for measuring total bone volume (of the whole sections) in dentate (D) and edentulous (E) mandibles. C; area used for measurement of the cancellous bone volume above the level of the incisor, X = height of the incisor + 500 μ m.

STATISTICAL ANALYSIS

Data are expressed as the mean \pm SEM. When the distribution of the data was not normal, natural log transformation was performed. For each bone, means were compared using one-way analysis of variance (ANOVA). In case of a significant F-test, the Tukey HSD test was used to determine which groups were significantly different from each other. In addition, we evaluated within group changes as a function of time for each bone using linear regression analysis. Statistical tests were performed as 2-tailed with a $p < 0.05$ considered significant.

RESULTS

The effect of OVX on BMD as measured by DEXA

BMD values for the dentate and edentulous mandibles of control and OVX are shown in fig (2) for the complete mandible and in table (1) for the body of the mandible. In the edentulous mandible, BMD was lower in the OVX group at 6 months and 9 months post-OVX (Fig 2-A & table 1). BMD in the control group did not change over the course of the experiment. In the dentate mandible, no differences were found between the OVX and control

groups at all time points whether scanned with teeth present (Fig 2-B & table 1), or after removal of teeth (Fig 2-C & table 1).

In the tibia, OVX decreased BMD at 6 months and 9 months post-OVX in both the whole tibia (table 1) and the proximal tibia (Fig 3-A). BMD values for the femur were also decreased in the OVX group at 6- and 9-months post-OVX in both the whole femur (table 1), and the proximal femur (Fig 3-B).

Table 2 summarizes the results expressed as percentage decrease or increase in BMD of the OVX group as compared to the control group.

The effect of OVX on bone volume and porosity of edentulous and dentate mandibles

Total bone volume, that is the percentage of surface area occupied by bone tissue, was similar in edentulous and dentate mandibles of OVX and control groups at all time points (table 3). It is important to consider the fact that total bone volume in the dentate mandible was exclusive of the area occupied by the tooth sockets, while in the edentulous mandible, the area represented by the healed sockets was included. To eliminate the area represented by the healed sockets from the comparison, we next

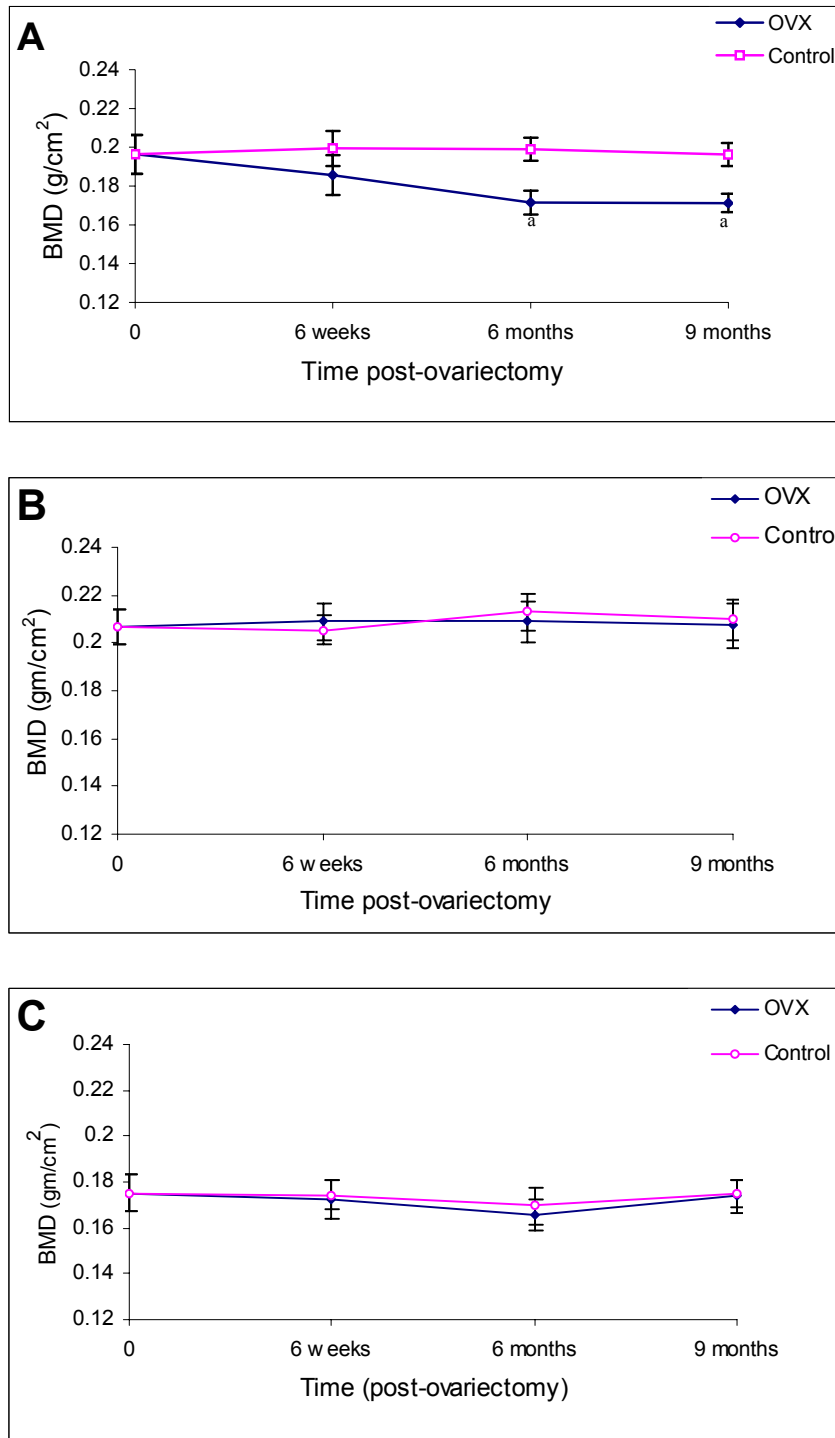


Figure 2. Changes in BMD of (A) edentulous mandible (B) dentate mandible measured with teeth present and (C) dentate mandible measured after removal of teeth. Each data point is the mean \pm SEM of 12-14 animals. *a* Significantly different from control at the same time point ($p < 0.001$).

analyzed bone parameters in the area above the level of the incisor (Fig 1-C) in both dentate and edentulous mandibles. Compared to matching control groups, total bone volume above the level of the incisor in the OVX group decreased by 18.6% at 6 months and by 19.2% at 9 months post-OVX in the edentulous mandible (Fig 4), while OVX decreased cancellous bone volume by 21.8% at 6 months and by 24% at 9 months (Fig 5). Neither of these parameters changed in the dentate mandibles as a result of OVX (Fig 4 & 5; table 4).

Analysis of the cancellous bone above the level of the incisor revealed a significant increase in porosity in the edentulous

mandible of the OVX group at 6 months (28.3%) and at 9 months (31.5%) post-OVX (table 3), whereas no differences were found in the dentate mandibles. Backscattered images of mandibles of OVX and control animals are presented in figures 6 and 7. Cortical bone volume above the level of the incisor did not change in both the dentate and edentulous mandibles of OVX and control groups (Fig 8).

OVX-induced changes in cancellous bone volume of the proximal tibiae and femorae: Cancellous bone volume of the proximal tibiae of the OVX group decreased by 38.5% at 6 months and by 58.9% at 9 months post-OVX when compared to the control group (Fig 9-A). Similarly,

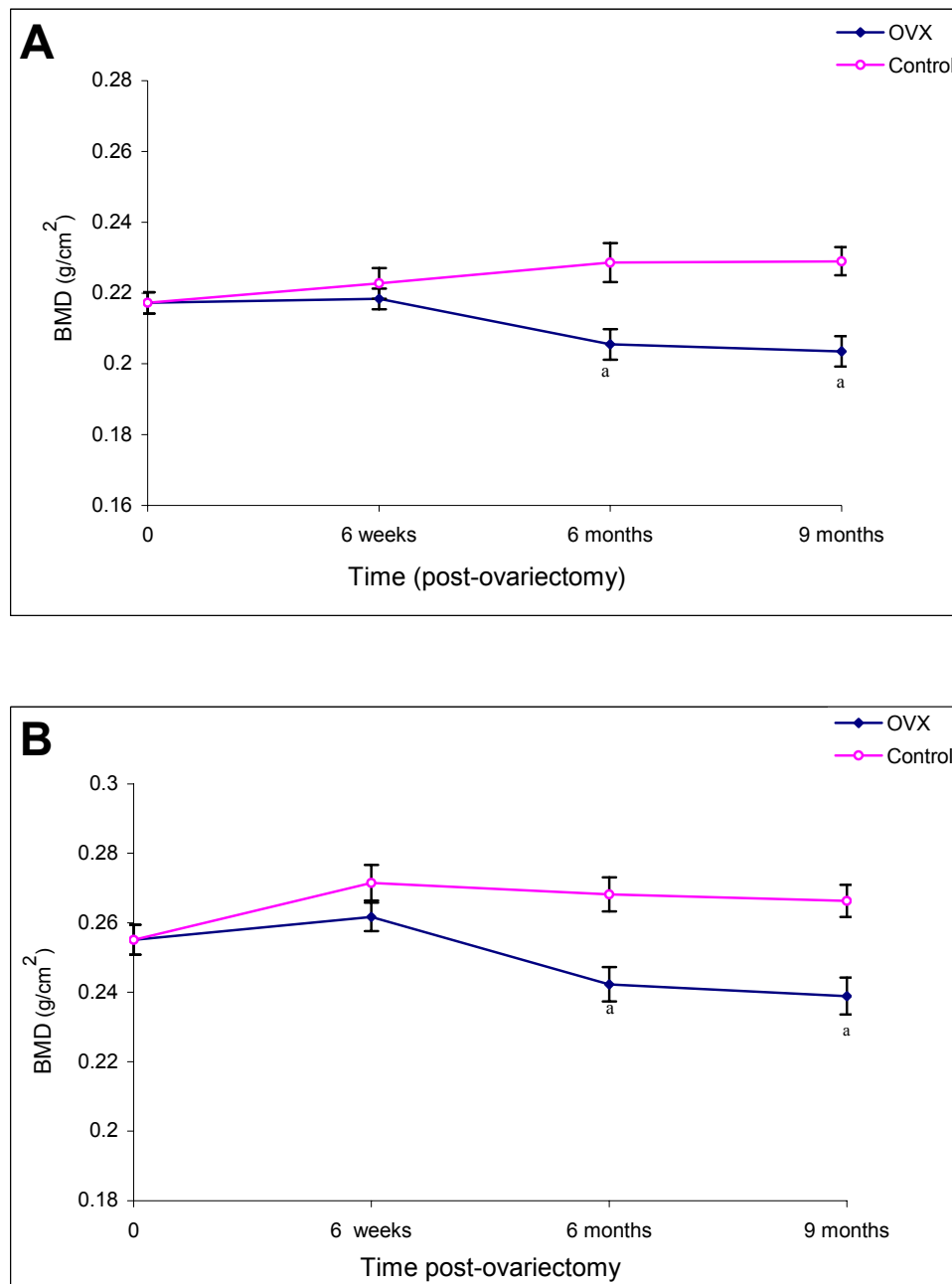


Figure 3. Changes in BMD of (A) proximal tibia and (B) proximal femur. Each data point is the mean \pm SEM of 12-14 animals. *a* Significantly different from control group at the same time point ($p < 0.001$).

cancellous bone volume of the proximal femorae of the OVX group decreased by 39.6% and by 49.9 % at 6- and 9-months post-OVX respectively (Fig 9-B). In both tibiae and femorae changes observed at 6-weeks post-OVX were not significant.

DISCUSSION

In the present series of experiments we studied the effects of OVX on bone loss in dentate and edentulous mandibles of rats and compared this with the known effect of OVX in tibiae and femorae. In order to exclude the possible effects of OVX on healing of extraction sockets, we allowed the extraction sockets of the molars and the incisor to heal for 4 months before OVX. We have shown previously that

in rats healing of the extraction sockets of the mandibular molars and the incisor is complete after 4 months¹³.

In the edentulous mandible, OVX resulted in bone loss at 6 months post-OVX as indicated by a decrease in BMD and bone volume values. Further analysis revealed that this bone loss was primarily due to a decrease in cancellous bone volume. OVX had no effect on the dentate mandible. In agreement with several other investigations¹⁷⁻²⁰, OVX resulted in a significant decrease in BMD and cancellous bone volume of tibiae and femorae at 6- and 9- months post-OVX. The similarity of OVX-induced bone loss in the edentulous mandibles and the tibiae and femorae is compatible with studies²¹ demonstrating a correlation between bone changes in the human mandible and other skeletal sites using panoramic radiographs.

Table 1. Changes in BMD of the body of the edentulous mandible, the body of the dentate mandible, the tibia and the femur.

Bone Group	Baseline	6 weeks Post-OVX	6 months Post-OVX	9 months Post-OVX
<i>Edentulous mandible</i>				
Control	0.225 ± 0.031	0.226 ± 0.036	0.225 ± 0.027	0.223 ± 0.021
OVX	-	0.213 ± 0.026	0.189 ± 0.031 ^a	0.186 ± 0.029 ^b
<i>Dentate mandible (teeth present)</i>				
Control	0.239 ± 0.017	0.251 ± 0.016	0.245 ± 0.019	0.252 ± 0.008
OVX	-	0.249 ± 0.012	0.249 ± 0.015	0.251 ± 0.014
<i>Dentate mandible (teeth removed)</i>				
Control	0.209 ± 0.026	0.210 ± 0.029	0.201 ± 0.025	0.212 ± 0.029
OVX	-	0.204 ± 0.027	0.196 ± 0.029	0.208 ± 0.031
<i>Whole tibia</i>				
Control	0.217 ± 0.011	0.223 ± 0.017	0.229 ± 0.022	0.228 ± 0.018
OVX	-	0.218 ± 0.011	0.206 ± 0.17 ^b	0.204 ± 0.019 ^b
<i>Whole femur</i>				
Control	0.253 ± 0.011	0.263 ± 0.018	0.265 ± 0.021	0.263 ± 0.013
OVX	-	0.251 ± 0.012	0.233 ± 0.011 ^b	0.231 ± 0.014 ^b

Data presented as the mean ± SD of 12-14 animals in each group. Significantly different from the control group at the same time point a p < 0.01, b p < 0.001.

Table 2. Changes in bone mineral density (BMD) values at different time points after OVX relative to controls, expressed as percentage increase or decrease. CV% = percentage coefficient of variation.

Bone	6 weeks post-OVX	6 months post-OVX	9 months post-OVX	CV%
Dentate mandible (Complete, teeth present)	+1.7%	- 1.9%	- 1.2%	1.0%
Dentate mandible (Body, teeth present)	+ 1.1%	- 1.6%	- 1.9%	1.3%
Dentate mandible (Complete, teeth removed)	- 1.0%	- 2.2%	- 0.9%	1.1%
Dentate mandible (Body, teeth removed)	+ 2.0%	- 2.7 %	- 1.7%	1.4%
Edentulous mandible (Complete bone)	- 6.9%	- 13.8%*	- 12.7%*	1.3%
Edentulous mandible (Body)	- 5.8%	- 15.9%**	- 17.2%*	1.5%
Whole-tibia	- 1.9%	- 10.0%*	- 11.1%*	1.2%
Proximal tibia	- 5.9%	- 15.6%*	- 16.1%*	1.5%
Whole-femur	- 4.3%	- 11.9%*	- 12.0%*	1.3%
Proximal femur	- 3.6%	- 9.7%*	- 10.3%*	1.7%

Significant decrease in BMD of ovariectomized (OVX) group * p < 0.001, ** p < 0.01.

Table 3. Total bone volume (whole section) and porosity of the edentulous and dentate mandible.

	Baseline	6 weeks Post-OVX	6 months Post-OVX	9 months Post-OVX
<i>Total bone volume of edentulous mandible</i>				
Control	76.45 ± 5.37	78.12 ± 6.11	79.10 ± 8.54	77.53 ± 7.41
OVX	-	73.31 ± 7.24	69.39 ± 7.31	69.85 ± 8.22
<i>Total bone volume of dentate mandible</i>				
Control	78.45 ± 5.99	76.15 ± 9.51	77.89 ± 10.26	75.88 ± 8.79
OVX	-	77.27 ± 7.11	75.66 ± 7.08	73.56 ± 9.22
<i>Porosity of edentulous mandible</i>				
Control	35.57 ± 7.96	36.13 ± 8.22	34.88 ± 7.06	32.95 ± 6.87
OVX	-	38.64 ± 5.71	48.64 ± 5.97 ^{a,b}	47.58 ± 5.49 ^{a,b}
<i>Porosity of dentate mandible</i>				
Control	35.17 ± 8.41	36.29 ± 8.02	37.01 ± 7.66	33.92 ± 8.79
OVX	-	37.98 ± 9.56	36.36 ± 7.48	34.45 ± 10.04

Data are presented as the mean + SD of 6 animals in each group. a Significantly different from the edentulous control group at the same time point (p < 0.001); b Significantly different from the dentate control and OVX groups at the same time points (p < 0.01).

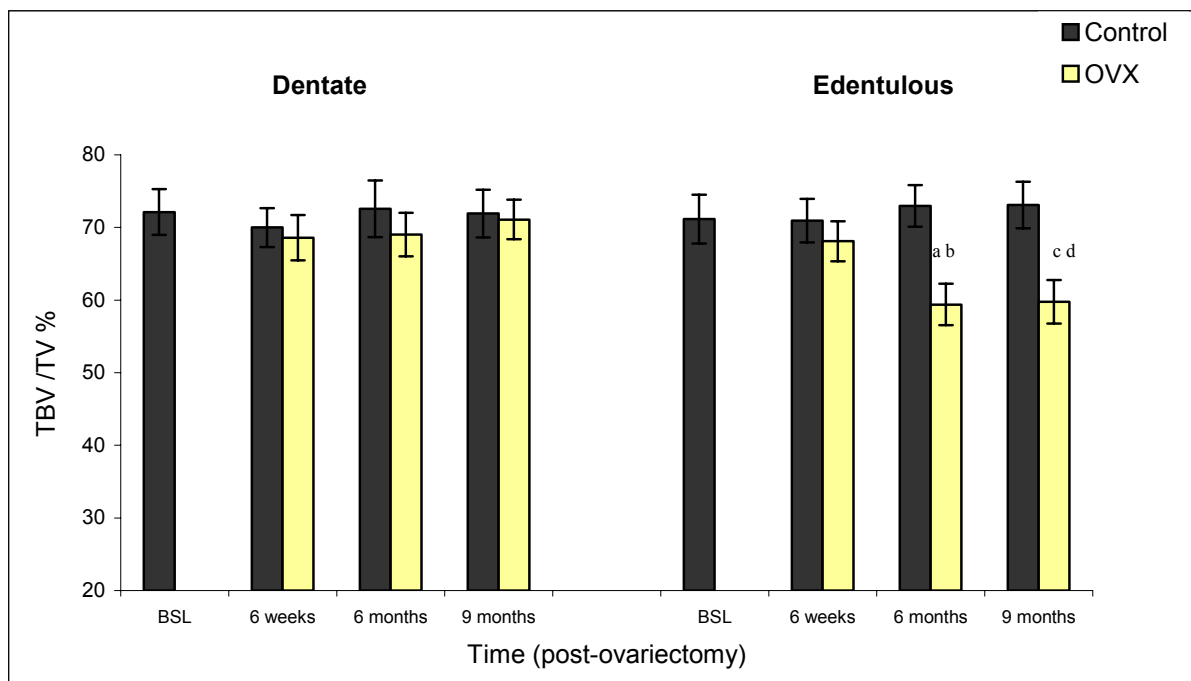


Figure 4. Changes in total bone volume (TBV/TV %) above the level of the incisor of dentate and edentulous mandibles. Each data point is the mean ± SEM of 6-8 animals. a Significantly different from edentulous and dentate controls at the same time point (p < 0.0001). b Significantly different from dentate OVX (p < 0.01). c Significantly different from edentulous control at the same time point (p < 0.001). d Significantly different from dentate control and OVX at the same time point (p < 0.01). OVX = ovariectomized group, BSL = baseline.

Table 4. Linear regression analysis showing the effect of time in control and OVX groups.

Variables ^a	Effect of time in control group			Effect of time in OVX group		
	slope	r	p	slope	r	p
<i>Edentulous mandible</i>						
BMD (complete)	- 0.000169	0.008	NS	-0.000687	0.297	0.026
BMD (body)	- 0.000531	0.27	NS	-0.00111	0.485	0.0001
TBV/TV ¹	0.04297	0.102	NS	-0.182	0.374	0.035
TBV/TV ²	0.06519	0.150	NS	-0.340	0.665	0.0001
Cn BV/TV	0.07554	0.151	NS	-0.377	0.653	0.0001
Porosity	- 0.0755	0.151	NS	0.378	0.654	0.0001
Ct BV/TV	- 0.0154	0.121	NS	0.03224	0.271	NS
Cross-sectional area	- 0.0435	0.461	0.008	-0.0641	0.580	0.0001
Height	- 0.0255	0.553	0.001	-0.0311	0.698	0.0001
Width	- 0.00215	0.175	NS	-0.00244	0.158	NS
<i>Dentate mandible</i>						
BMD (complete)	- 0.000398	0.049	NS	-0.0000791	0.089	NS
BMD (body)	0.0001164	0.010	NS	-0.0000648	0.050	NS
TBV/TV ¹	0.01489	0.025	NS	-0.0846	0.168	NS
TBV/TV ²	0.02638	0.070	NS	0.01226	0.027	NS
Cn BV/TV	0.03571	0.077	NS	0.0330	0.069	NS
Porosity	- 0.0357	0.077	NS	-0.0330	0.069	NS
Ct BV/TV	- 0.119	0.084	NS	-0.0196	0.164	NS
Cross-sectional area	- 0.0135	0.160	NS	-0.0222	0.249	NS
Height	0.0013	0.025	NS	-0.00539	0.111	NS
Width	- 0.0001114	0.011	NS	-0.00128	0.119	NS
<i>Tibia</i>						
BMD (whole)	0.0003128	0.289	0.031	-0.000447	0.547	0.0001
BMD (proximal)	0.0003617	0.254	NS	-0.000846	0.666	0.0001
Cn BV/TV	0.09355	0.294	NS	-0.249	0.677	0.0001
<i>Femur</i>						
BMD (Whole)	0.0002334	0.204	NS	-0.000662	0.636	0.0001
BMD (proximal)	0.0001753	0.147	NS	-0.000588	0.489	0.0001
Cn BV/TV	0.0163	0.021	NS	-0.513	0.644	0.0001

^a Bone mineral density (BMD) and bone histomorphometric variables. TBV/TV¹ = total bone volume of whole section, TBV/TV² = total bone volume above the incisor, Cn BV/TV = cancellous bone volume, Ct BV/TV = Cortical bone volume; OVX = ovariectomized group.

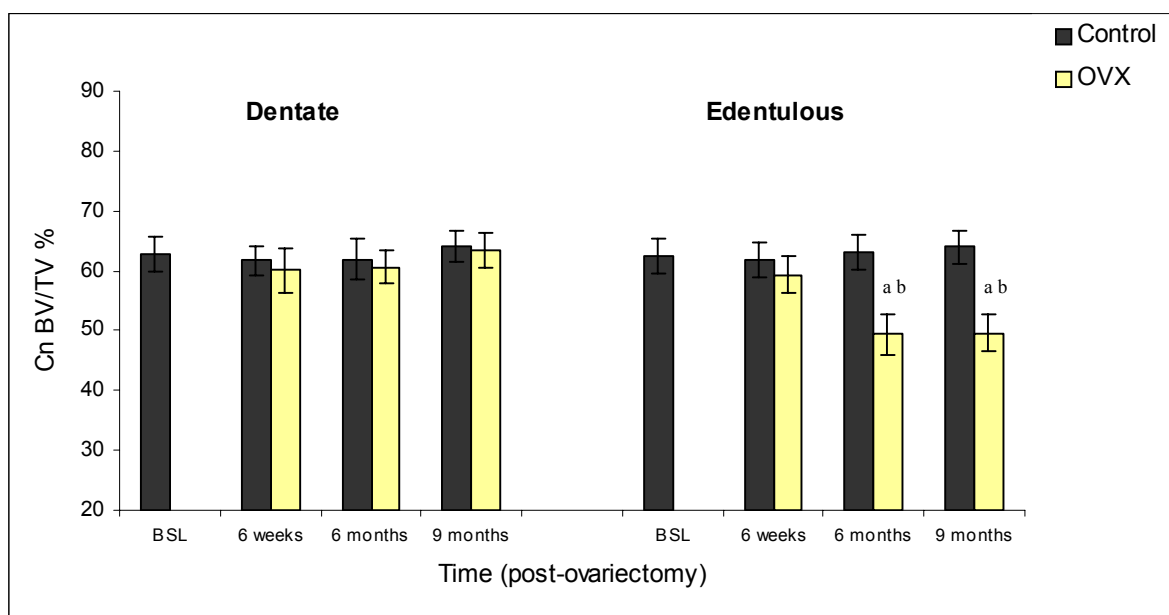


Figure 5. Changes in cancellous bone volume (Cn BV/TV %) above the level of the incisor of dentate and edentulous mandibles. Each data point is the mean \pm SEM of 6-8 animals. a Significantly different from the edentulous control group at the same time point ($p < 0.001$). b Significantly different from the dentate control and OVX groups at the same time point ($p < 0.01$). OVX = ovariectomized group, BSL baseline.

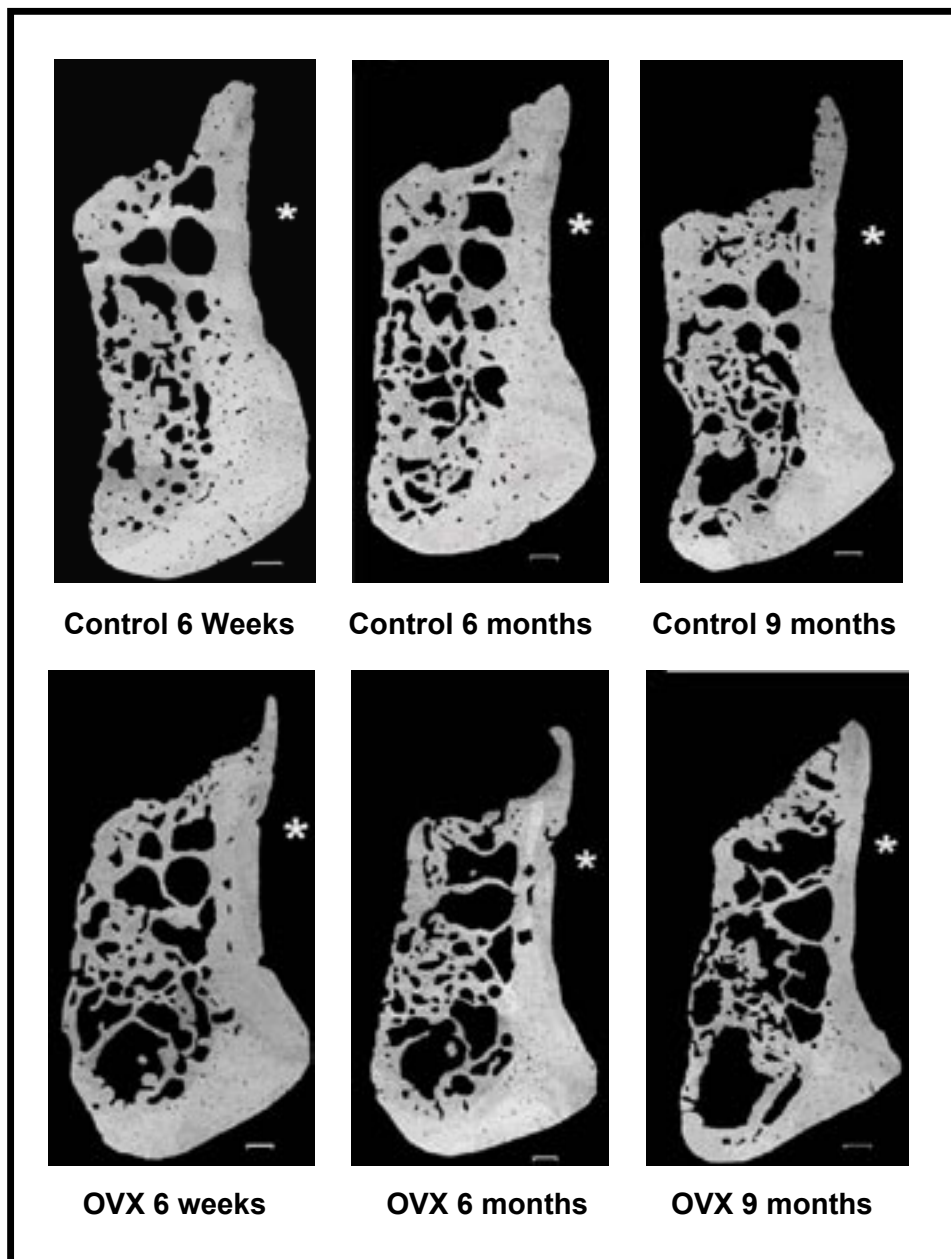


Figure 6. Backscattered electron microscopy images of bucco-lingual cross-sections of edentulous mandibles of OVX and control groups at different time points. * Buccal side of mandible. Bar = 0.3mm; X = 100.

That OVX has no effect on the dentate mandible while it induced bone loss in the edentulous mandible is striking and suggests that masticatory function prevented post-OVX bone loss in the dentate mandible. Our finding that OVX has no effect on the dentate mandible is in agreement with the findings of Elovic et al.,⁵⁻⁷ who found that neither bone area fraction nor stiffness or BMD of the functional dentate mandible was affected up to 200 days after OVX. Interestingly, they found that the combination of OVX and maxillary teeth extraction resulted in a decrease in stiffness and bone area fraction, but not of BMD, of the unopposed dentate mandible of rats and suggested that the presence of teeth in the dentate mandible might have obscured the effect of OVX when measured by DEXA. In our experiment, we analyzed the dentate mandible before and after removal of teeth and found that OVX did not affect BMD

of dentate mandibles whether measured with or without teeth. It seems likely that Elovic et al.,⁵⁻⁷ could not detect significant differences in BMD because they did not remove the maxillary incisor, as it has been shown that the incisor teeth in rats can produce large biting forces that range between 200 and 4,500 g²². This view is supported by results of Cao et al.,¹² who found a reduction in total BMD at 12 weeks post-OVX in edentulous mandibles of rabbits following extraction of mandibular incisors. Using peripheral quantitative computed tomography they also found that bone loss was due to a reduction in cancellous BMD while cortical BMD remained unchanged which concurs with our bone volume measurements¹².

Our findings for dentate mandibles are also in agreement with those of Mavropoulous et al.,⁸ who demonstrated

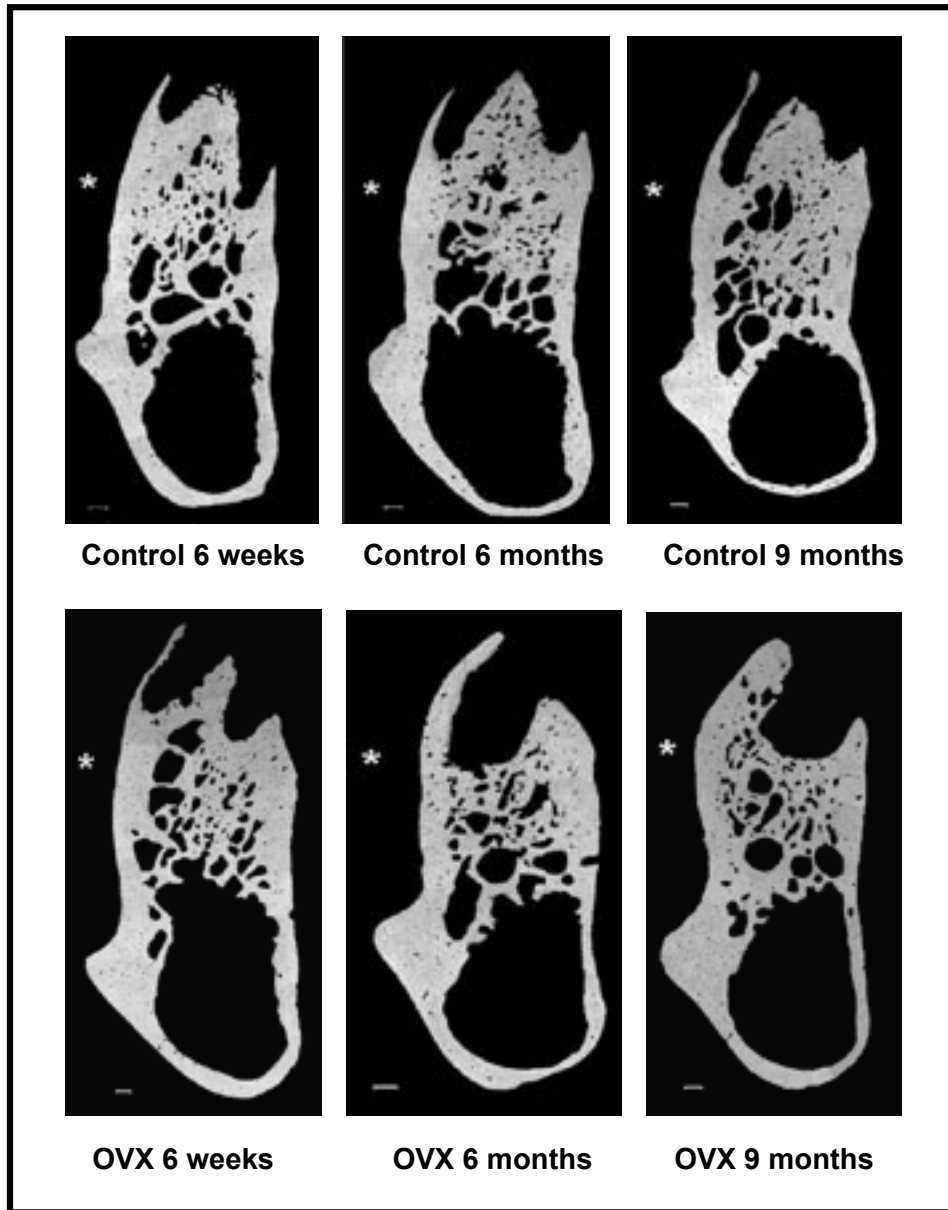


Figure 7. Backscattered electron microscopy images of bucco-lingual cross-sections of dentate mandibles of OVX and control groups at different time points. * Buccal side of mandible. Bar = 0.3 mm; X= 100.

that OVX alone did not affect the alveolar bone of dentate mandibles, and are compatible with those of Ishihara et al.,⁹ who showed that OVX had no effect on the dentate maxillae of rats up to 5 months post-OVX.

Our results as well as others⁵⁻⁹ are in disagreement with those of Tanaka et al.,¹¹ who found that OVX induced bone loss in the dentate mandibles of rats. These differences could be the result of different measurement techniques. We measured bone changes along the entire body of the mandible using BMD and a standardized sectioning method for histomorphometry measurements.

The hypothesis that functional stress may prevent OVX-induced bone loss is supported by the observations of West-erlind et al.,²³ who demonstrated that OVX induces a rapid and profound cancellous bone loss in the distal metaphysis of the femur (a site that has been shown to experience low strain energy), whereas the adjacent epiphysis (a site

that has been shown to experience high strain energy) was resistant to bone loss. Observations in humans suggesting that functional stresses generated by masseter muscle are involved in maintaining BMD in edentulous regions of the mandible²⁴ are compatible with this view.

Studies measuring strain levels in human tibiae have shown tibial strains to be about three times higher during vigorous activities such as sprinting and hill running (nearly 2000 microstrains) than during walking²⁵. Furthermore, strain gauge experiments indicate that peak strain magnitude measured in a variety of animals (including horse tibia, dog tibia, goose humerus, sheep femur and macaca mandible) were in the range of 2000- 3000 microstrains during various vigorous activities including trotting, flying and biting²⁶.

That OVX induces bone loss in the tibiae and femorae of rats while loading prevents OVX-induced cortical bone loss²⁷ and significantly reduces OVX-induced cancellous

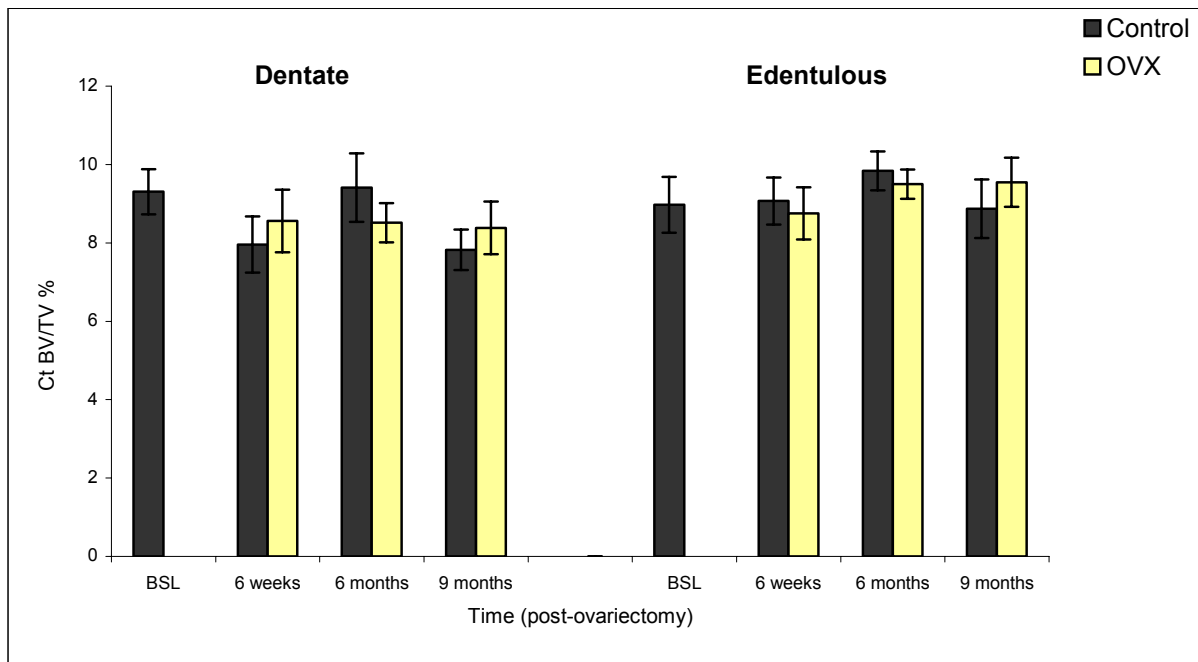


Figure 8. Changes in cortical bone volume (Ct BV/TV %) of dentate and edentulous mandibles. Each data point is the mean \pm SEM of 6-8 animals. OVX = ovariectomized group, BSL = baseline.

bone loss²⁸, together with the finding that increasing intensities of treadmill running exercise increasingly attenuate bone loss in the femorae of ovariectomized rats²⁹ indicates that exercise can prevent OVX-induced bone loss. The observation that high impact loading during gymnastics training produced higher femoral neck BMD than running and counteracted the increased bone resorption as a result of amenorrhea and oligomenorrhea seen in human females³⁰ further indicates that normal daily activities produce far smaller strain magnitudes than vigorous peak magnitude activity and are not enough to counteract the effect of OVX on bone loss³¹.

Previous studies indicate that only dynamic loads have a protective or osteogenic effect, and that strains of similar magnitude applied in static manner fail to cause an osteogenic response³². In addition there is evidence that after only 36 consecutive loading cycles (a total of 72 seconds per day), further loading cycles do not stimulate further osteogenesis³³, suggesting a threshold above which additional loading cycles produce no additional bone formation. The major use of the incisors of the rat has been shown to be during feeding and the time in which incisors are in functional occlusal contact has been estimated to be about 69-76 minutes/day³⁴. This suggests that biting forces are of a dynamic, non-repetitive pattern, which could enhance

the osteogenic response of bone to biting forces. In addition, it has been reported that, during biting, muscular forces create bending and twisting moments that produce substantial strains in both alveolar and basal regions of the mandible³⁵.

The beneficial effect of biting force on bone is further illustrated by observations in the dental implant literature where the magnitude of chewing forces placed on implant-supported dentures has been shown to be considerably greater than that for natural teeth and conventional dentures^{36,37}. This has been suggested to be responsible for the increased radiopacity seen around titanium dental implants³⁸. Moreover, the finding that implant-supported dentures minimized, and sometimes counteracted, the age related mandibular bone mineral content loss in humans^{39,40} supports this view.

Within the limitations of this study, it can be concluded that while OVX caused bone loss in the edentulous mandible as well as in the proximal tibiae and femorae of rats, it had no effect on the dentate mandible. Bone loss in the edentulous mandible was primarily due to a reduction in cancellous bone volume. The results strongly suggested that functional stress related to biting force prevents post-OVX bone loss in the dentate mandible.

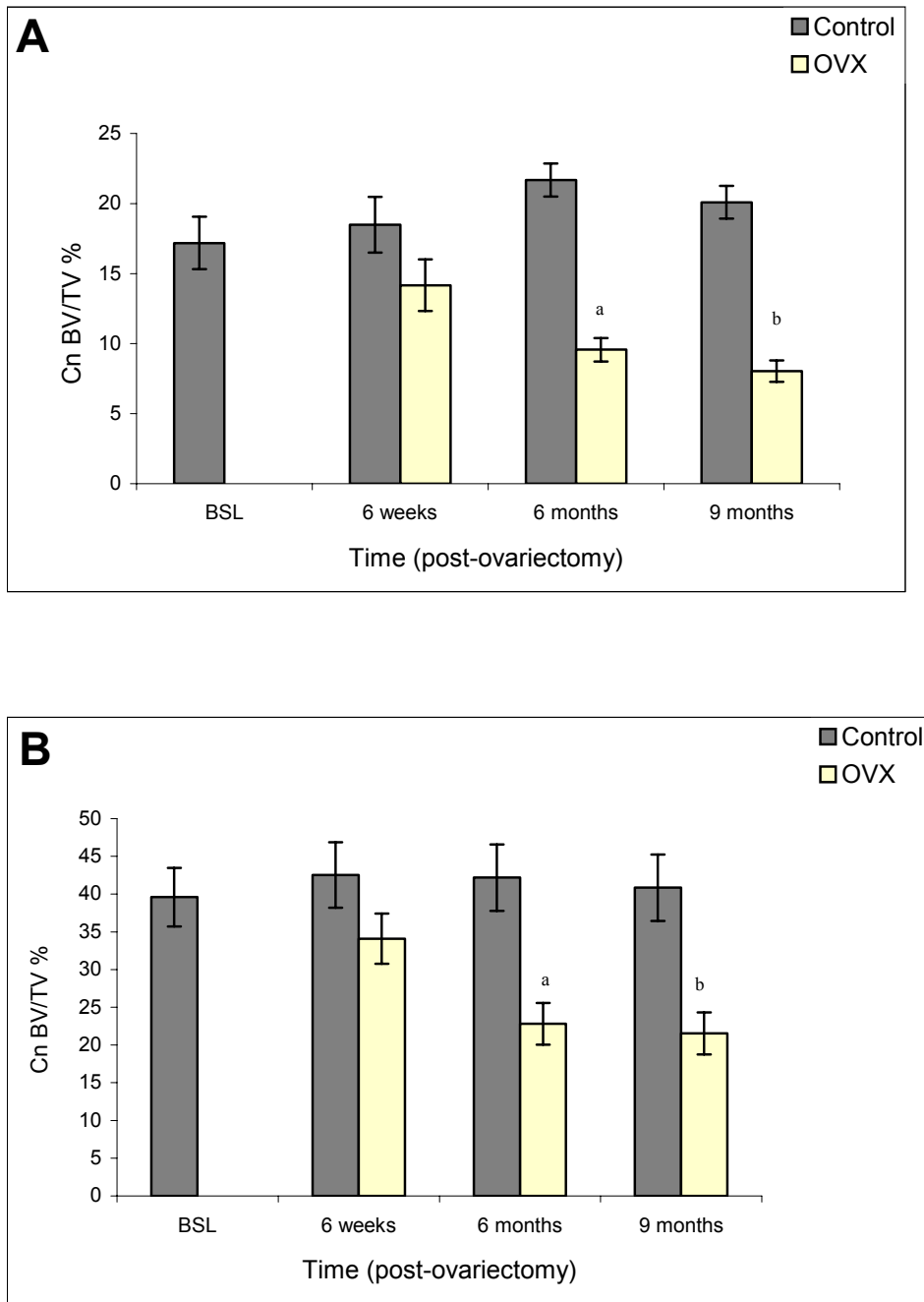


Figure 9. Changes in cancellous bone volume (Cn BV/TV%) of (A) the proximal tibia and (B) the proximal femur. Each data point is the mean \pm SEM of 6-8 animals. Significantly different from the control group at the same time point a $p < 0.02$, b $p < 0.001$.

ADDRESS FOR CORRESPONDENCE

Emad S. Elsubeihi, Dental Centre, Tawam Hospital in Affiliation with Johns Hopkins Medicine, P O Box 15258, Al-Ain, Abu Dhabi, UAE. E-mail: eelsubeihi@hotmail.com

REFERENCES

- White, S.C., Oral radiographic predictors of osteoporosis. *Dentomaxillofac. Radiol.*, 2002; **31**:84-92.
- Elsubeihi, E.S. and Heersche, J.N.M., Effects of postmenopausal osteoporosis on the mandible. In Zarb G.A. et al. (Eds): *Aging, osteoporosis and dental implants*. Hong Kong: Quintessence Publishing Co, 2002; 207-215.
- Habets, L.L., Bras, J., and Borgmeyer-Hoelen, A.M., Mandibular atrophy and metabolic bone loss: Endocrinology, radiology and histomorphometry. *Int. J. Oral. Maxillofac. Surg.*, 1988; **17**:208-211.
- Habets, L.L., Bras, J., and van Merkesteyn, J.P., Mandibular atrophy and metabolic bone loss: Histomorphometry of iliac crest biopsies in 74 patients. *Int. J. Oral. Maxillofac. Surg.*, 1988; **17**:325-329.
- Elovic, R.P., Hipp, J.A., and Hayes, W.C., Maxillary molar extraction decreases stiffness of the mandible in ovariectomized rats. *J. Dent. Res.*, 1994; **73**:1735-1741.
- Elovic, R.P., Hipp, J.A., and Hayes, W.C., Maxillary molar extraction causes increased bone loss in the mandible of ovariectomized rats. *J. Bone. Miner. Res.*, 1995; **10**:1087-1093.
- Elovic, R.P., Hipp, J.A., and Hayes, W.C., Ovariectomy decreases the bone area fraction of the rat mandible. *Calcif. Tissue. Int.*, 1995; **56**:305-310.
- Mavropoulos, A., Rizzoli, R., and Ammann, P., Different responsiveness of alveolar and tibial bone to bone loss stimuli. *J. Bone. Miner. Res.*, 2007; **22**: 403-410.
- Ishihara, A., Sasaki, T., Debari, K., et al. Effects of ovariectomy on bone morphology in maxillae of mature rats. *J. Electron. Microsc.*, 1999; **48**:465-469.
- Hara, T., Sato, T., Oka, M., Mori, S., and Shirai, H., Effects of ovariectomy and/or dietary calcium deficiency on bone dynamics in the rat hard palate, mandible and proximal tibia. *Arch. Oral. Biol.*, 2001; **46**:443-451.
- Tanaka, M. Eiichi, T., Shoji, K., Hidehiro, O. and Sadakazu, E. Long-term changes in trabecular structure of aged rat alveolar bone after ovariectomy. *Oral. Surg. Oral. Med. Oral. Pathol. Oral. Radiol. Endod.* 2003; **95**:495-502.
- Cao, T., Shirota, T., Yamazaki, M., Ohno, K., and Michi, K.I., Bone mineral density in mandibles of ovariectomized rabbits. *Clin. Oral. Implants. Res.*, 2001; **12**:604-608.
- Elsubeihi, E.S. and Heersche, J.N.M., Quantitative assessment of post-extraction healing and alveolar ridge remodeling of the mandible in female rats. *Arch. Oral Biol.*, 2004; **49**:401-412
- Waynforth, H.B., *Experimental and surgical techniques in the rat*. New York: Academic Press, 1980;161-163:
- Peng, Z., Tuukkanen, J., Zhang, H., and Vaananen, H.K., Alteration in the mechanical competence and structural properties in the femoral neck and vertebrae of ovariectomized rats. *J. Bone. Miner. Res.*, 1999; **14**:616-623.
- Verna, C., Melsen, B., and Melsen, F., Differences in static cortical bone remodeling parameters in human mandible and iliac crest. *Bone.*, 1999; **25**:577 -583.
- Wronski, T.J., Dann, L.M., Scott, K.S., and Cintron, M., Long-term effects of ovariectomy and aging on the rat skeleton. *Calcif. Tissue. Int.*, 1989; **45**:360-366.
- Li, M., Shen, Y., and Wronski, T.J., Time course of femoral neck osteopenia in ovariectomized rats. *Bone.*, 1997; **20**:55-61.
- Yoshida, S., Yamamuro, T., Okumura, H., and Takahashi, H., Microstructural changes of osteopenic trabeculae in the rat. *Bone.*, 1991; **12**:185-194.
- Elsubeihi, E.S., Bellows, C.G., Yia, Y., and Heersche, J.N. Ovariectomy of 12-month-old rats: Effects on osteoprogenitor numbers in bone cell populations isolated from femur and on histomorphometric parameters of bone turnover in corresponding tibia. *Cell. Tissue. Res.*, 2007; **330**:515-526.
- Taguchi A, Tsuda M, Ohtsuka M, et al. Use of dental panoramic radiographs in identifying younger postmenopausal women with osteoporosis. *Osteoporos. Int.*, 2006; **17**:387-394
- Robins, M.W., Biting loads generated by the laboratory rat. *Arch. Oral. Biol.*, 1977; **22**:43-47.
- Westerlind, K.C., Wronski, T.J., Ritman, E.L., et al. Estrogen regulates the rate of bone turnover but bone balance in ovariectomized rats is modulated by prevailing mechanical strain. *Proc. Natl. Acad. Sci. U S A.*, 1997; **94**:4199-4204.
- Klemetti, E., Vainio, P., and Kroger, H., Muscle strength and mineral densities in the mandible. *Gerodontology.*, 1994; **11**:76-79.
- Burr, D.B., Milgrom, C., Fyhrie, D., et al. In vivo measurement of human tibial strains during vigorous activity. *Bone.*, 1996; **18**:405-410.
- Rubin, C.T. and Lanyon, L.E., Dynamic strain similarity in vertebrates; an alternative to allometric limb bone scaling. *J. Theor. Biol.*, 1984; **107**:321-327.
- Hagino, H., Raab, D.M., Kimmel, D.B., Akhter, M.P., and Recker, R.R., Effect of ovariectomy on bone response to in vivo external loading. *J. Bone. Miner. Res.*, 1993; **8**:347-357.
- Lin, B.Y., Jee, W.S., Chen, M.M., Ma, Y.F., Ke, H.Z., and Li, X.J., Mechanical loading modifies ovariectomy-induced cancellous bone loss. *Bone. Miner.*, 1994; **25**:199-210.
- Peng, Z.Q., Vaananen, H.K., and Tuukkanen, J., Ovariectomy-induced bone loss can be affected by different intensities of treadmill running exercise in rats. *Calcif. Tissue. Int.*, 1997; **60**:441-448.
- Robinson, T.L., Snow-Harter, C., Taaffe, D.R., Gillis, D., Shaw, J., and Marcus, R., Gymnasts exhibit higher bone mass than runners despite similar prevalence of amenorrhea and oligomenorrhea. *J. Bone. Miner. Res.*, 1995; **10**:26-35.
- Fritton, S.P., McLeod, K.J., and Rubin, C.T., Quantifying the strain history of bone: spatial uniformity and self-similarity of low-magnitude strains. *J. Biomech.*, 2000; **33**:317-325.
- Lanyon, L.E. and Rubin, C.T., Static vs dynamic loads as an influence on bone remodelling. *J. Biomech.*, 1984; **17**:897-905.
- Rubin, C.T. and Lanyon, L.E., Regulation of bone formation by applied dynamic loads. *J. Bone. Joint. Surg. Am.*, 1984; **66**: 397-402.
- Robins, M.W., Circadian pattern of the use of the incisor teeth by laboratory rats. *Arch. Oral. Biol.*, 1973; **18**:641-645.
- Daegling, D.J. and Hylander, W.L., Occlusal forces and mandibular bone strain: is the primate jaw "overdesigned"? *J. Hum. Evol.*, 1997; **33**:705-717.
- Falk, H., On occlusal forces in dentitions with implant-supported fixed cantilever prostheses. *Swed. Dent. J. Suppl.*, 1990; **69**:1-40.
- Haraldson, T. and Zarb, G., A 10-year follow-up study of the masticatory system after treatment with osseointegrated implant bridges. *Scand. J. Dent. Res.*, 1988; **96**:243-252.
- Adell, R., Lekholm, U., and Branemark, P.-I., A long term follow-up study of osseointegrated implants in the treatment of totally edentulous jaws. *Int. J. Oral. Maxillofac. Implants.*, 1990; **5**:347 -359.
- von Wöwern, N., Harder, F., Hjørtting-Hansen, E., and Gotfredsen, K., ITI implants with overdentures: a prevention of bone loss in edentulous mandibles? *Int. J. Oral. Maxillofac. Implants.*, 1990; **5**:135-139.
- von Wöwern, N. and Gotfredsen, K., Implant-supported overdentures, a prevention of bone loss in edentulous mandibles? A 5-year follow-up study. *Clin. Oral. Implants. Res.*, 2001; **12**:19-25.