

Radiographic Evaluation of Healing Tissues of Early-failing Implants after Therapy: A Case Report

Salah Sakka* and Rami Alissa†

Abstract - *Aside from clinical evaluation, the interpretation of radiographic images is one of the most frequently applied diagnostic procedures in patients with oral implants. Radiology is an important part of treatment with tissue-integrated prostheses, both at the pre-operative stage to obtain full assessment of the bony host and at the post-operative stage to assess the clinical result. Radiographic examination of peri-implant tissues is an essential diagnostic prerequisite for the evaluation of success and failure of oral implants. A case of peri-implant radiolucency detected 3 months after surgical placement is presented. A remarkable regression of the radiolucency was noticed after a successful anti-infective therapy. The aim was to stress the role of oral radiology in exploring peri-implant bone defects. At this point, appropriate intervention might save early-failing implants from complete loss of osseointegration.*

KEY WORDS: Dental Implants, Implant Failure, Osseointegration.

INTRODUCTION

Radiological methods are an essential part of treatment with tissue-integrated prostheses, both at the preparation stage and in the short or long-term evaluation of the clinical result. For the pre-operative assessment, mapping of the implant site is necessary to obtain thorough knowledge of dimensions and quality of bone, outlines of marrow spaces and locations of nerve structures. In the post-operative regular check-up appointments, concern focuses on the development of bone anchorage and other tissue reactions. It is very important to acquire information on the density and architecture of bone and on the appearance of the anchorage site.

Despite high success rate of endosseous titanium implants, failures unavoidably occur. Early failures occur during osseointegration and lead to the loss of the implant before the suprastructure has been fabricated. Radiographs have been used after surgical placement of dental implants, in order to assess situations after anticipated osseointegration, and in case of failure. Moreover, radiographic parameters have been used in controlled studies to document peri-implant bone changes^{1,2}.

Case Report

A 22-year-old female presented with a chief complaint of congenital missing of both lower second premolars. Thorough clinical evaluation as well as preoperative radiographic examination using periapical radiographs were undertaken before the placement of 2 dental implants measuring 4.5mm in diameter and 15mm in length.

For the assessment of postoperative changes of the marginal bone level, standardised periapical radiographs were

taken using a Heliodont MD intraoral X-ray set (Siemens, Bensheim, Germany) operated at 70 kVp. All the imaging was performed using F-speed film (Kodak, Hemel Hempstead, UK). A paralleling technique and Rinn XCP film holder (Dentsply Rinn, Elgin, IL, USA) coupled to a beam-aiming device were used to achieve reproducible exposure geometry. All films were developed using the same automatic processor (Durr GmbH, Bietigheim-Bissingen, Germany) following the manufacturer's instructions. Periapical radiographs were taken at two weeks (baseline), three and six months post-placement. A total of three radiographs of each implant site were obtained.

The marginal bone level was assessed by measuring the distance in millimetres between the implant shoulder and the lowest observed point of marginal bone contact with the fixture. The measurements were made by the same investigator (S.S) using a viewing box and x8 handheld magnifier (MAG 6 Pyser-SGI Limited, Kent, UK) fitted with a graticule in its ring-base for linear measurement purposes on a scale of 20mm divided into 0.1mm graduations. This magnifier has a simple lens system with one focal plane, so that any observed object through the lens will only be clearly defined when it is in that plane. The graticule in the MAG 6 was positioned in that plane and kept in contact with the radiograph for both to be in focus. It was possible to adjust the focus of the eye-piece on the magnifier, by rotating the lens separate unit in the magnifier body until the graticule markings were as sharply focused as possible.

Implant length (a known dimension) was used for calibration. Taking into consideration the inevitable variation in magnification in the radiographs, the resulting magnification for each radiographic examination was accounted for by calculating the ratio of the observed length of the implant to the already known length. To transform the measured radiographic changes of bone level into estimated bone loss values, an algorithm^{3,4} was used by which the measured (mesial or distal) bone loss was divided by the unique magnification factor which was worked out

* DDS MSc PhD

† PhD

for each implant. The use of this handheld magnifier has been previously demonstrated to be a simple, reliable and reproducible method for measuring bone loss around dental implants⁵. The baseline linear measurements of the mean mesial and distal bone loss were 0.90mm and 0.50mm respectively (Fig a and b).

The patient was instructed for a good home oral hygiene, and received a one-week treatment of ibuprofen 600mg 6 hourly for pain relief. No post-operative antibiotics were prescribed.

The implants were exposed 3 months later at the second-stage surgery. The implants were immobile with no signs of infection. However, a remarkable progression of peri-implant radiolucency was detected where the mean mesial and distal bone loss of 6.70mm and 6.90mm was evident (Fig c and d) with no bleeding on probing. Patient was placed on a 10-day antibiotic regime (maxicillin 600 mg taken every 6 hours) and instructed to rinse twice daily with Chlorhexidine digluconate mouthwash 0.2% w/v. The patient was re-evaluated every 3 weeks where professional plaque control was performed. At the six months follow up appointment, no signs of either implant mobility or infection were detected. However, the mean mesial and distal bone loss of 3.80mm and 2.90mm was recorded (Fig e and f) with no bleeding on probing. That means a mesial and distal bone gain of 2.90mm and 4mm respectively was calculated between the periods of 3 months and 6 months follow ups. Patient was informed of the improved status of osseointegration and was happy to be referred to the prosthodontic department for the completion of the implant restoration.

DISCUSSION

Implantology is continually developing as new research results provide a better understanding of the biologic principles that direct the development of a dynamic interface between the living tissue and an artificial structure. The theory of dental implants osseointegration is an important concept where achievement of clinical stability is a prerequisite for the successful clinical function. As primary stability plays an essential role in implant success, secondary stability that often refers to implant stability after primary healing is of the same importance for achieving that success. Primary stability, which is necessary at the time of implant placement, is determined by the quality of the bone⁶, the surgical technique and the implant design⁷. Secondary stability needed following osseointegration is determined by primary stability and further stability that results from bone remodelling at the implant-bone interface.

Early-failing implants were saved from a total loss of osseointegration by anti-infective therapy that was either shared with a bone-stimulating treatment using a non-steroidal anti-inflammatory drug (flurbiprofen)⁸ or using the principles of guided tissue regeneration (GTR)⁹. The treatment of these implants was successful as the implants showed neither continuous peri-implant radiolucency nor clinical mobility.

In this case report, the considerable bone defect around the implants observed at 3-month follow-up stage (Fig c and d) was an interesting observation and failure of the implants was expected. Surprisingly, at the six-month

follow-up stage, the progression of peri-implant bone loss ceased and signs of osseointegration after conservative anti-infective therapy were evident. The reason for this is unknown. However, one possible explanation is an initiation of several remodelling events caused by certain factors (surgical trauma could be one of them), which might have resulted in a transient loss of anchorage and then followed by bone formation events. Increases in peri-implant bone height as well as density may be interpreted as positive signs of healing after anti-infective therapy as previous observations documented¹⁰.

The longevity of an osseointegrated implants is directly affected by the maintenance of its osseous anchorage¹¹. The latter authors proposed a radiographic index ranging from 0 to 6 describing marginal bone loss as a percentage relative to the implant body length. This takes into account the fact that bone loss of 2mm, for instance, may have a more marked effect on the prognosis for a short implant than for a long one. At this point, the radiographic examination remains one of the main tools for recognition of failed or failing implants in clinical practice.

In the present case report, a series of standardised radiographs were required to measure the bone level changes at interproximal aspects of the implants. It is well documented that the assessment of marginal bone loss using conventional radiographs has inherent limitations often related to the fact that conventional radiographs provide a two-dimensional representation of a three-dimensional anatomy. Therefore, not only changes at a facial bone level may be overlooked, but also sites which exhibit an osseous change can be undetected because of superimposition by unchanged areas. In addition, there are difficulties in achieving a perfect geometric standardisation especially when a series of radiographs is required to evaluate mandibular implants. In spite of the fact that efforts were made to implement a standardised protocol when taking the periapical radiographs, some degree of magnification and distortion of the images was inevitable owing to minor variations of the position of the film holder and the angulation of the central beam. It can be argued that although calibration of the images was carried out, there may still be possible minor variations in radiographic projection that might have accounted for some of the observed reduction in bone loss around the implant placed in this patient.

Diagnostic imaging in dentistry has dramatically developed in recent years and a specialised technology such as the Cone Beam CT (CBCT), has become available for the purpose of postoperative assessment of bony changes around dental implants with the help of computer tomography¹². It is possible that this advanced technology may be used for evaluating marginal bone loss around dental implants, because it provides three-dimensional and cross-sectional images without superimposition. On the other hand, one of the drawbacks of using three-dimensional computed radiography, is that during radiographic exposure, radiation from the source is transmitted through tissues and dense objects (restorations and titanium materials) which receive the scattered radiation. The resulting effects of this phenomenon including noise and artefacts could obfuscate the diagnostic task of bone loss assessment¹³. In addition, the relatively high cost and requirement of skills and training for interpretation of the reconstructed images may further limit the use of the technology.

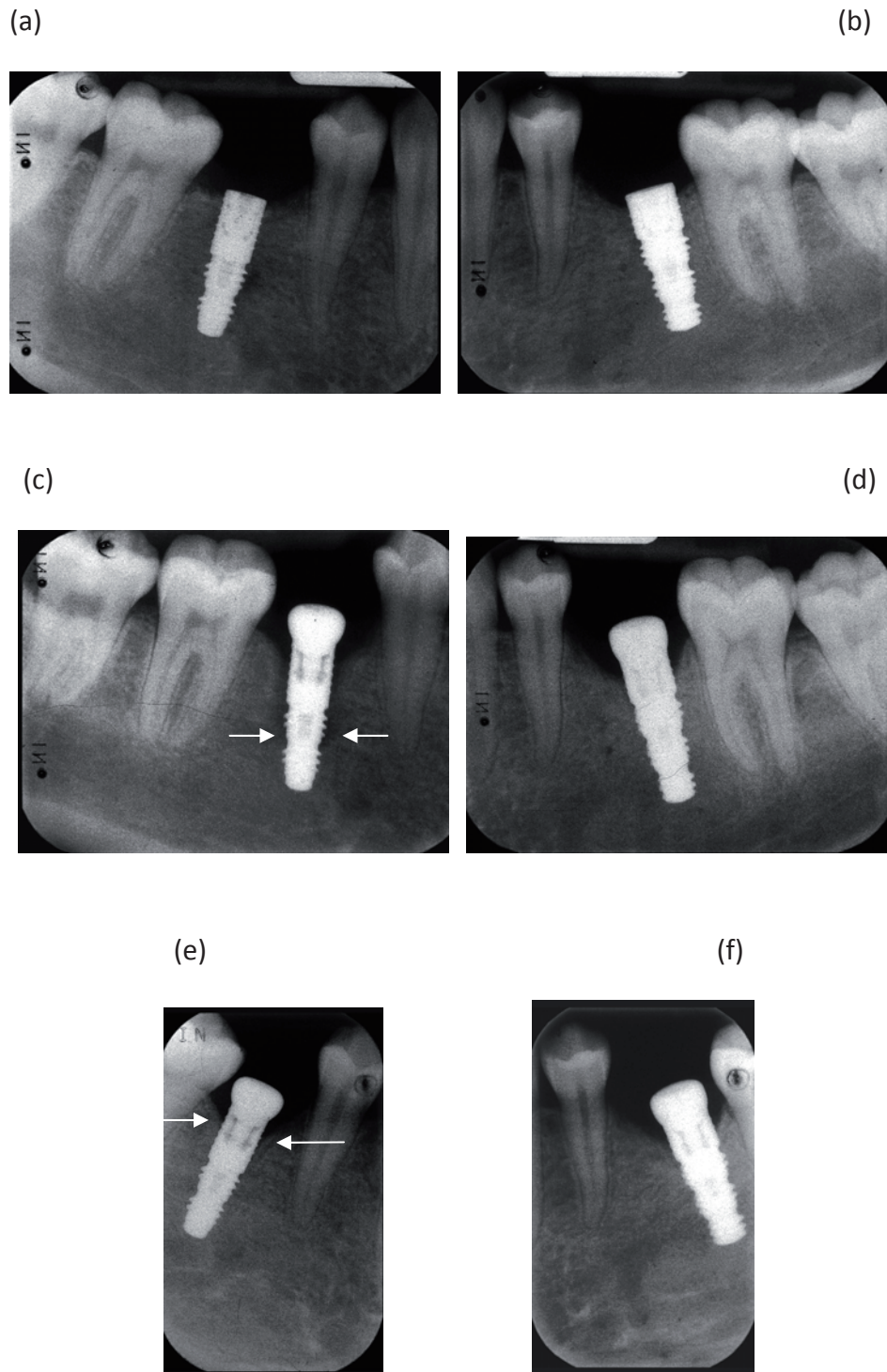


Figure 1. Radiographs of implants placed for restoration of mandibular left and right premolars

(a, b): Post-operative baseline.

(c, d): Three months follow-up. Arrows indicate level of bone defect.

(e, f): Six months follow-up. Arrows indicate level of bone loss.

CONCLUSION

Regular clinical and radiographic examinations are crucial in detection of peri-implant bone loss. This is very important in cases of early failures where appropriate interventions may save the implant and lead to adequate osseointegration.

MANUFACTURERS' DETAILS

- Frialit-II® (Friatec, Mannheim, Germany).
- Heliodont MD intraoral X-ray set (Siemens, Bensheim, Germany)
- F-speed film (Kodak, Hemel Hempstead, UK)
- Rinn XCP film holder (Dentsply Rinn, Elgin, IL, USA)
- Automatic processor (Durr GmbH, Bietigheim-Bissingen, Germany)
- Magnifier (MAG 6 Pyser-SGI Limited, Kent, UK)
- Corsodyl (Corsodyl, GlaxoSmithKline plc, Brentford, Middlesex, UK).

ADDRESS FOR CORRESPONDENCE

Rami Alissa, School of Dentistry, The University of Manchester, Higher Cambridge Street, Manchester, M15 6FH. UK. E-mail: Rami.Alissa@manchester.ac.uk or cloudy-eye86@hotmail.com

REFERENCES

1. Jeffcoat, M.K, Reddy, M.S, Wang, I.C, Meuninghoff, L.A, Farmer, J.B. and Koth, D.L. The effect of systemic flurbiprofen on bone supporting dental implants. *J. Am. Dent. Assoc.*, 1995; **126**:305-311.
2. Alissa, R., Sakka, S. and Oliver, R. et al. Influence of ibuprofen on bone healing around dental implants: a randomised double-blind placebo-controlled clinical study. *Eur. J. Oral. Implantol.*, 2009; **2**:185-199.
3. Reddy, MS., Wang, IC. Radiographic determinants of implant performance. *Adv. Dent. Res.*, 1999; **13**: 136-145.
4. Wakoh, M., Harada, T., Otonari, T. et al. Reliability of linear distance measurement for dental implant length with standardized periapical radiographs. *Bull.Tokyo. Dent. Coll.*, 2006; **47**: 105-115.
5. Sakka, S., Al-ani, Z., Kasioumis, T. et al. Interexaminer and intra-examiner reliability of the measurement of marginal bone loss around oral implants. *Implant. Dent.*, 2005; **14**: 386-388.
6. Sakka, S. and Coulthard, P. Bone quality: a reality for the process of osseointegration. *Implant Dent.*, 2009; **18**:480-485.
7. Khoury, F. and Happe, A. Soft tissue management in oral implantology: a review of surgical techniques for shaping an esthetic and functional peri-implant soft tissue structure. *Quintessence Int.*, 2000; **31**:483-499.
8. Reddy, M.S., Jeffcoat, M.K. and Richardson, R.C. Assessment of adjunctive flurbiprofen therapy in root-form implant healing with digital subtraction radiography. *J. Oral Implantol.*, 1990; **16**:272-276.
9. Lehmann, B., Bragger, U., Hammerle, C.H., Fourmousis, I. and Lang, N.P. Treatment of an early implant failure according to the principles of guided tissue regeneration (GTR). *Clin. Oral Implants Res.*, 1992; **3**:42-48.
10. Bragger, U. Use of radiographs in evaluating success, stability and failure in implant dentistry. *Periodontol. 2000.*, 1998; **17**:77-88.
11. Nasr, H.F. and Meffert, R.M. A proposed radiographic index for assessment of the current status of osseointegration. *Int. J. Oral Maxillofac. Implants.*, 1993; **8**:323-328.
12. Naitoh, M., Nabeshima, H., Hayashi H., et al. Postoperative assessment of incisor dental implants using cone-beam computed tomography. *J. Oral. Implantol.*, 2010; **36**: 377- 384.
13. Howerton, WB Jr., Mora, MA. Advancements in digital imaging: what is new and on the horizon?. *J. Am. Dent. Assoc.*, 2008; **139** Suppl:20S-24S.