

# Prosthetic Rehabilitation with Implant-Supported Mandibular Overdenture after Partial Glossectomy and Radiation Therapy: A Case Report

## Keywords

Radiation Therapy  
Tongue Cancer  
Oral Implant  
Overdenture  
CAD/CAM Bar

## Authors

Dr. Elina Rissa <sup>§</sup>  
(DDS)

Dr. Tia Kurki <sup>§</sup>  
(DDS, PhD)

Dr. Juhani Laine <sup>§</sup>  
(DDS, PhD)

Prof. Timo Närhi <sup>\* §</sup>  
(DDS, PhD)

## Address for Correspondence

Prof. Timo Närhi <sup>\*</sup>

Email: timnar@utu.fi

<sup>\*</sup> Department of Prosthetic Dentistry and Stomatognathic Physiology, University of Turku, Finland

<sup>§</sup> Clinic of Oral and Maxillofacial Diseases, Turku University Central Hospital, Turku, Finland

## ABSTRACT

*Implant-supported overdenture is a well-established treatment option for many patients who have functional problems with conventional dentures. It may be primary choice for patients with altered jaw anatomy, neuromuscular disorders, pronounced gag reflex, severe residual ridge resorption and oral tissue defects. In this article we describe a case report, where tongue cancer patients occlusion was rehabilitated with an implant-retained overdenture. In 2001 patient was operated for squamous cell carcinoma on the left side of the tongue. Before preoperative radiation therapy, small residual mandibular dentition was removed because of its poor prognosis. Radiation dose on mandible was 57-66 Gy. After tumor surgery patient received conventional complete dentures. Ten years later, the patient was referred again to the Turku University Central Hospital due to constant ulceration under the mandibular denture. The residual ridge of the mandible was severely resorbed. Patient's existing lower complete denture was replaced with a milled bar-retained overdenture on four implants. Treatment turned out to be challenging due to severely restricted tongue movement and tissue defects.*

## INTRODUCTION

Patients with a severely resorbed mandible have frequently problems to manage with their technically well-fabricated conventional complete dentures. Their problems include pain during mastication, insufficient stability and poor retention of the denture. Apart from these, there are often constant ulcers in the denture bearing mucosa and due to the decreased load-bearing area of the dentures patients complain about chronic soreness on the alveolar mucosa.<sup>1</sup>

Another group of patients with frequent denture wearing problems is oral cancer patients. Ninety percent of oral cancers are epidermoid carcinomas and they are most often located in the tongue, floor of the mouth or alveolar mucosa.<sup>2</sup> Small tumors are usually treated with ablative surgery, whereas in large and locally spread cancers radiotherapy with adjuvant chemotherapy is combined with surgery.<sup>3</sup> Tumor resection reduces the support area that stabilizes conventional prosthesis, provokes scar tissue formation, destroys mucous membrane and often alters mandibular anatomy by reducing the vestibular flange, even after a surgical reconstruction with free microvascular flaps.<sup>4</sup>

Received: 13.12.2017

Accepted: 06.03.2018

doi: 10.1922/EJPRD\_01789Rissa05

Furthermore, the patients suffer frequently from irradiation-induced hyposalivation, chronic mucositis, reduced mouth opening and unfavorable inter-occlusal relations. Many cancer patients may become unable to wear conventional prostheses, which in turn impairs their chewing, swallowing, speaking ability and quality of life.<sup>5</sup>

Dental implants have become an increasingly common treatment option for many edentulous patients. Due to the persistent tissue defects, functional impairment and side effects of radiation therapy, most of the oral cancer patients are potential candidates for implant supported overdenture therapy.<sup>6</sup>

After a high-dose radiotherapy, the reduced regenerative capacity of irradiated tissues results in hypoxic, hypovascular and hypocellular tissues, which may hamper the implant osseointegration and even cause a risk of osteoradionecrosis.<sup>7</sup> Hyperbaric oxygen therapy (HBO) has been used to improve healing capacity after irradiation, but the benefit of HBO is unclear.<sup>8-9</sup> Schoen *et al.* used dental implants with or without HBO in a randomized trial in head and neck cancer patients, and found no difference in the implant survival or complication rate between the study groups.<sup>10</sup> Nyberg *et al.* studied experimentally the effect of HBO on the bone-implant-contact and the results revealed lower bone contact area in the HBO group.<sup>11</sup> On the other hand, recent study shows that HBO can induce clinically measurable oxygen tensions both in irradiated oral mucosa and skin.<sup>12</sup>

According to systematic reviews, the survival of implants placed in radiated jaw bone seems to be slightly lower compared to the implants placed in non-radiated implant sites.<sup>13-14</sup> Schignitz *et al.* have suggested in their meta-analysis that the failure rate in the irradiated and non-radiated mandibles is the same if the modern implant types are used.<sup>15</sup> However, evaluation of the current literature is difficult, because most of the studies are retrospective and several systemic and local co-factors may influence on the forming and maintenance of osseointegration in radiated patients (timing of implant placement from radiation to implantation, surgical technique, loading protocol, prosthesis design, radiation dose, smoking, alcohol consumption and oral hygiene<sup>16</sup>). Several authors have suggested that optimal time for postradiation implant placement would be between 6 to 24 months, whereas implant failure risk increases significantly in patients irradiated several years before the implant surgery.<sup>14,16</sup>

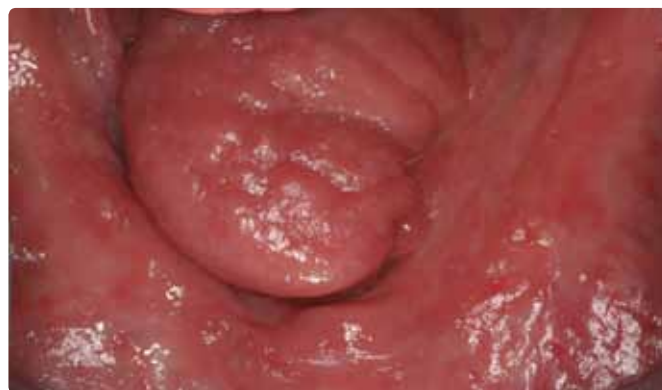Previous studies in non-radiated patients have indicated that the function of the denture or patient satisfaction is not dependent on the number of implants or type of the attachment in mandibular overdentures. The anatomical conditions in and between upper and lower jaws influence the number of implants and the type of attachment.<sup>17</sup> Weischer and Mohr observed that prosthetic related pressure lesions that increase the risk of septic osteoradionecrosis, were seen only in implant and mucosa-supported prostheses. Therefore, the

authors recommended totally implant-supported prostheses after irradiation of jaws.<sup>18</sup> This usually requires the use of four implants. The implants should be placed with equal interimplant distances in the anterior mandible, allowing placement of at least three retention clips in the overdenture. The bar design with distal extensions will decrease the mucosal loading even more. Recently, milled bars fabricated with CAD-CAM-techniques have offered a large variety of new options including rigid bars with integrated attachments.

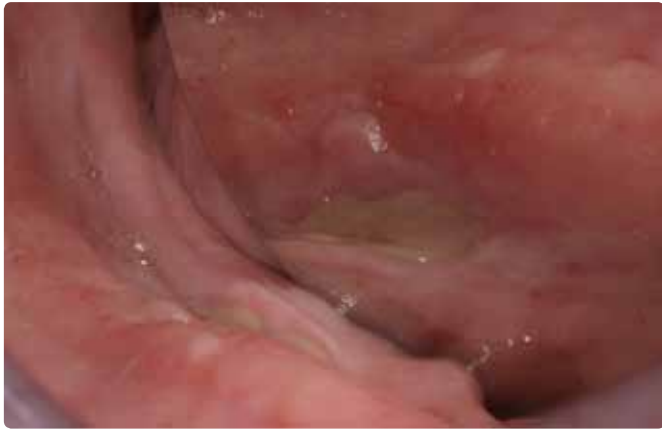## CASE REPORT

The patient is a 76 years old male. He was diagnosed to have T<sub>2</sub>N<sub>0</sub>M<sub>0</sub> squamous cell carcinoma on the left side of the tongue in 2001. He received a preoperative, hyperfractionated radiotherapy and a partial glossectomy was performed four weeks after radiotherapy. Surgical resection included the anterior and middle parts of the mobile tongue. Radiation dose on lower jaw was 57-66 Gy. After recovery patient received conventional complete dentures on both jaws. During the following four years patient had recall examinations every six month at the Clinic of Oral and Maxillofacial Diseases of the Turku University Central Hospital. After the four year recall visit, all necessary dental treatments were given by own dentist.

Ten years later, the patient was referred again to the Clinic of Oral and Maxillofacial Diseases by his physician due to problems with ill-fitting lower denture. The lack of stability and retention of the mandibular denture, together with decreased chewing ability, were the main complaints of the patient. The residual ridge of the lower jaw was severely resorbed (*Figure 1*). Furthermore, the lower denture caused constant pain and ulceration in the mouth (*Figure 2*). Patient complained also about fissures radiating for the angles of the mouth, which he had treated with over the counter antifungal emulsion. The presence of angular cheilitis was noticed also at the time of clinical examination. Patient showed no signs or symptoms of TMD problems. No recurrence of tongue cancer had occurred since the initial treatment. In 2004 the physician had administered Thyroxin substitution medication. No other changes had occurred in his general health status.



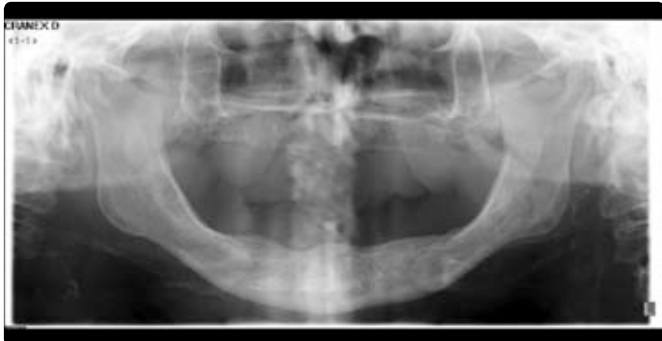**Figure 1:** Clinical view of severely resorbed mandible.



**Figure 2:** Large mucosal wound on the lingual side of the mandibular first molar region.

**TREATMENT PLANNING**

Due to demanding anatomical conditions, advanced resorption and restricted tongue movement, the ill-fitting lower complete denture was decided to be replaced with an implant-supported bar-retained overdenture. New set of complete dentures was first made to evaluate vertical dimension of occlusion and the available volume in denture base for bar construction. Radiological evaluation with panoramic radiograph and cone beam computer tomography revealed that existing bone volume allowed placement of four implants in the interforaminal region (Figure 3).

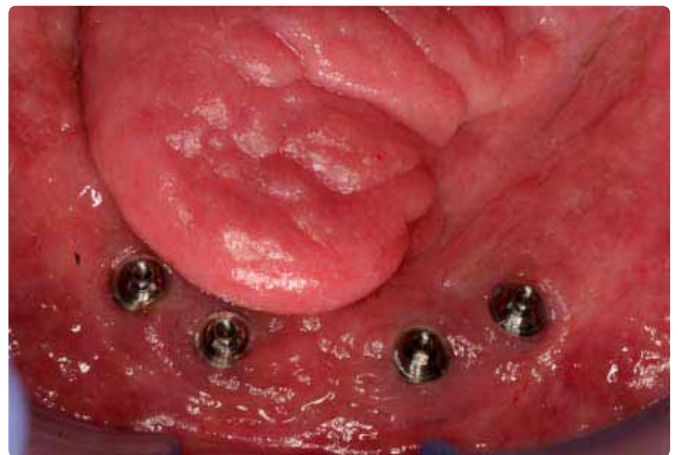


**Figure 3:** Panoramic radiograph of the edentulous jaws.

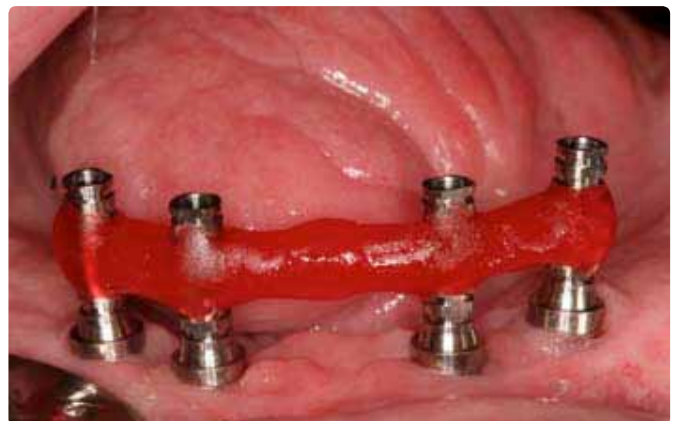**TREATMENT**

Four Astra Osseospeed implants (4.0S, length 13 mm, Astra Tech®, Dentsply, Germany) were chosen for the implantation. Amoxicillin 750 mg, 1x2, LC was given to support healing. Antibiotic treatment was started three days prior the implantation and continued during the two weeks uneventful healing. Implants were placed in the interforaminal region of the mandible in previously planned positions using a standard two-stage procedure. Primary stability of all implants was considered excellent, which allowed a four months osseointegration period before abutment connection. Implant surgery was performed ten years after radiation therapy.

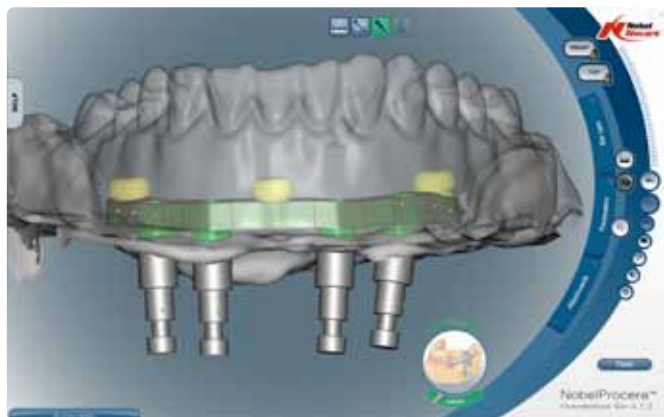
Following the implant disclosure, Multi-Unit abutments (Brånemark System®, Nobel Biocare, Switzerland) for the Astra Tech implant system were connected on all implants (Figure 4). An open tray impression was taken from the abutment level with polyether impression material (Impregum®, 3M ESPE, USA). While the overdenture was constructed the abutments were protected with healing caps and existing denture was adjusted with soft relining material. After fitting a try-in bar (Figure 5) on the implants the final milled bar construction with three Locator precision attachments was ordered (Figure 6) (Procera®, Nobel Biocare, Switzerland). The milled bar with three integrated Locator components was attached to implants (Figure 7) and Locator female parts were connected to the mandibular overdenture. New conventional complete denture was made on upper jaw (Figure 8).



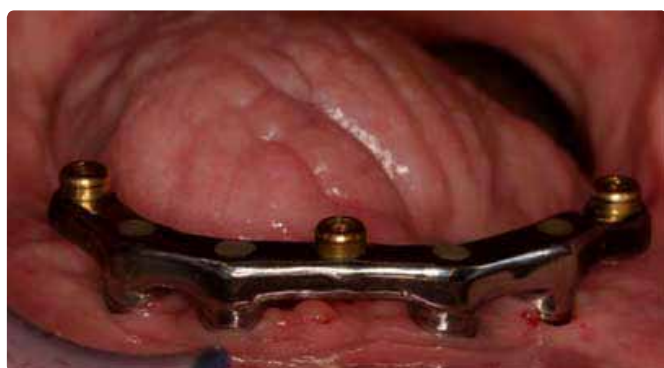**Figure 4:** Brånemark Multi-Unit abutments connected to implants



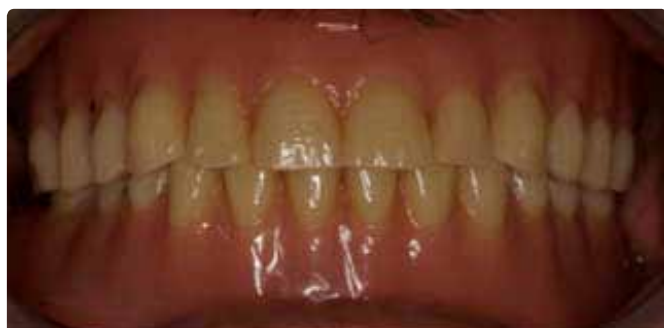**Figure 5:** Try-in bar to confirm the precision of fit for CAD-CAM production



**Figure 6:** Computer aided planning of the milled bar



**Figure 7:** Milled bar with Locator attachments connected to implants



**Figure 8:** Final prostheses in occlusion

## DISCUSSION

This case report describes implant supported overdenture treatment of an edentulous patient with a history of partial glossectomy and radiation therapy. Typically, resection of tongue tumor changes oral anatomy and causes functional problems. Also in our patient tongue movement was impaired due to tissue defect and scar formation. This further restricted his ability to manipulate traditional complete dentures. Problems started to accumulate some years after the cancer treatment with frequent ulceration under denture flanges. Because residual dentition was removed prior to cancer treatment, bone resorption in the anterior mandible had resulted

in severely resorbed alveolar crest ten years later. Resorption had been compensated with relines but at this stage modification of the existing dentures would not have been improved denture function. Totally implant supported overdenture on four implants was considered best alternative for this patient since his main complaints in addition to poor retention were pain and frequent ulcerations. Dryness of the oral mucosa due to hyposalivation was an additional complicating factor.

Radiation therapy impairs bone remodeling and may disturb osseointegration. Hyperbaric oxygen therapy has therefore been used to support osseointegration when placing implants in the irradiated bone. However, high implant survival rates have been reported with modern implants also without using hyperbaric oxygen.<sup>10</sup> In the present case report good primary stability was achieved and osseointegration proceeded normally without hyperbaric oxygen. No marginal bone loss was observed during the 12 months follow up period, which indicates good prognosis for the osseointegration.

Fixed implant supported prosthesis on four implants would have been a possible alternative, but due to the restricted tongue movement and reduced tissue volume smooth denture surface was preferred. Smooth overdenture surface supports function of the tongue during eating and prevents food remnants from packing in between alveolar ridge and prosthetic structures. Final suprastructure was a milled titanium bar with three Locator anchors, which allowed good retention and made it possible to relieve the oral mucosa from the denture pressure. In our patient vertical dimension of occlusion was determined by the traditional bite registration procedures of the edentulous persons. Freeway space was determined by the closest speaking distance method which resulted in 2-3 mm space between upper and lower dental arches in the rest position. Although satisfactory occlusion and articulation was achieved patient could not swallow properly which is a typical problem in radiated and operated oral carcinoma patients who have received no surgical free flap reconstruction. Vertical dimension of occlusion was diminished three times before final functional jaw relationship was achieved and the patient adapted to new dentures. According to our experience, routine bite registration methods cannot be followed while treating glossectomy patients with restricted tongue movement. Denture fabrication must be made through the functional approach, where main emphasis is put on evaluation of patient's ability to swallow. After glossectomies without free flap reconstruction, food intake and swallowing is usually compromised in spite of successful prosthetic rehabilitation.<sup>19</sup>

Our patient was enrolled in the maintenance program which included oral hygienist visits every 6 months and restorative dentist examination annually. Good oral and denture hygiene is extremely important for the edentulous overdenture patients because of the increased risk for peri-implant mucositis. In our patient radiation induced hyposalivation further enhances this risk. Furthermore, changes in peri-implant bone level must be carefully followed. Our patient's ability to maintain oral self care is evaluated during the re-call visits and maintenance program is updated accordingly.

Fit and retention of dentures is evaluated during restorative dentist's re-call visits. Locator attachments will lose their retention over time and these will be changed when needed. Mechanical complications in the milled bar overdentures are usually restricted to acrylic fractures and wear of prosthetic teeth. Screw loosening or fracture on abutment and framework level are also possible, but less frequent than in fixed implant retained prostheses. Tightness of the retentive screws is evaluated during our patient's annual re-call visits. Denture relines will be done when needed.

## REFERENCES

- Batenburg RH, Meijer HJ, Raghoebar GM, Vissink A. Treatment concept for mandibular overdentures supported by endosseous implants: a literature review. *Int J. Oral. Maxillofac. Implants.*, 1998;**13**:539-545.
- Engholm G, Ferlay J, Christensen N, Kejs AMT, Johannesen TB, Khan S, Leinonen MK, Milter MC, Ólafsdóttir E, Petersen T, Trykker H, Storm HH. NORDCAN: Cancer Incidence, Mortality, Prevalence and Survival in the Nordic Countries, Version 7.2 (16.12.2015). Association of the Nordic Cancer Registries. Danish Cancer Society. Available from <http://www.ancr.nu>, accessed on day/month/year.
- Hakulinen T, Tryggvadóttir L, Gislum M, Storm H, Bray F, Klint Å, Engholm G. Trends in the survival of patients diagnosed with cancers of the lip, oral cavity, and pharynx in the Nordic countries 1964–2003 followed up to the end of 2006. *Acta Oncol.*, 2010;**49**:561-577.
- Mancha de la Plata M, Gías LN, Díez PM et al. Osseointegrated implant rehabilitation of irradiated oral cancer patients. *J. Oral. Maxillofac. Surg.*, 2012;**70**:1052-1063.
- Speksnijder CM, van der Glas HW, van der Bilt A, Van Es RJJ, van der Rijt E, Koole R. Oral function After Oncological Intervention in the Oral Cavity: A Retrospective Study. *J. Oral. Maxillofac. Surg.*, 2010;**68**:1231-37.
- Korfage A, Raghoebar GM, Huddleston Salter JJR, Roodenburg JLN, Witjes MJH, Vissink A, Reintsema H. Overdentures on primary mandibular implants in patients with oral cancer: a follow-up study over 14 years. *Br. J. Oral. Maxillofac. Surg.*, 2014;**52**:798-805.
- Marx RE, Johnson RP, Kline SN. Prevention of osteoradionecrosis: A randomized prospective clinical trial of hyperbaric oxygen versus penicillin. *J. Am. Dent. Assoc.*, 1985;**111**:49-54.
- Annane D, Depondt J, Aubert P, Villart M, Gehanno P, Gajdos P, Chevret S. Hyperbaric oxygen therapy for radionecrosis of the jaw: A randomized, placebo-controlled, double-blind trial from the ORN96 study group. *J. Clin. Oncol.*, 2004;**22**:4893-900.
- Esposito M, Worthington HV. Interventions for replacing missing teeth: hyperbaric oxygen therapy for irradiated patients who require dental implants. *Cochrane Database Syst Rev* 2013.Sep30;**9**:CD003603. doi: 10.1002/14651858.CD003603.pub3. Review.
- Schoen PJ, Raghoebar GM, Bouma J, et al. Rehabilitation of oral function in head and neck cancer patients after radiotherapy with implant-retained dentures: Effects of hyperbaric oxygen therapy. *Oral. Oncol.*, 2007;**43**:379-88.
- Nyberg J, Herzman S, Svensson B, Johansson CB. Osseointegration of implants in irradiated bone with and without hyperbaric oxygen treatment: An experimental study in rat tibiae. *Int. J. Oral. Maxillofac. Implants.*, 2013;**28**:739-46.
- Svalestad J, Thorsen E, Vaagbo S, Hellem S. Effect of hyperbaric oxygen treatment on oxygen tension and vascular capacity in irradiated skin and mucosa. *Int. J. Oral. Maxillofac. Surg.*, 2014;**43**:107-12.
- Nooh N. Dental implant survival in irradiated oral cancer patients: a systematic review of the literature. *Int. J. Oral. Maxillofac. Implants.*, 2013 Sep-Oct;**28**:1233-42.
- Dholam KP, Gurav SV. Dental implants in irradiated jaws: a literature review. *J. Cancer. Res. Ther.*, 2012;**8**(S2):S85-93.
- Schignitz E, Al-Nawas B, Kämmerer PW, Grötz KA. Oral rehabilitation with dental implants in irradiated patients: a meta-analysis on implant survival. *Clin. Oral. Invest.*, 2014;**18**:687-98.
- Anderson L, Meraw S, Al-Hezaimi K, Wang H-L. The influence of radiation therapy on dental implantology. *Impl. Dent.*, 2013;**22**:31-8.
- Kuoppala R, Näpänkangas R, Raustia A. Outcome of implant-supported overdenture treatment—a survey of 58 patients. *Gerodontology.*, 2012;**29**:e577-584.
- Weischer T, Mohr C. Ten-year experience in oral implant rehabilitation of cancer patients: treatment concept and proposed criteria for success. *Int. J. Oral. Maxillofac. Implants.*, 1999;**14**:521-8.
- Canis M, Weiss BG, Ihler F, Hummers-Pradier E, Matthias C, Wolff HA. Quality of life in patients after resection of pT3 lateral tongue carcinoma: Microvascular reconstruction versus primary closure. *Head Neck.*, 2016;**38**:89-94.