

Continuous Scan Strategy (CSS): A Novel Technique to Improve the Accuracy of Intraoral Digital Impressions

Keywords

Accuracy
Passive Fit
Intraoral Scanners
Intraoral Digital Impressions
Fixed Implant Prosthodontics
Prosthetic Success

Authors

Mario Imburgia *
(DDS, PhD)

John Kois §
(DMD, MSD)

Elio Marino ^
(MD, DDS)

Henriette Lerner †
(DDS)

Francesco G. Mangano †
(DDS, PhD)

Address for Correspondence

Francesco G. Mangano †

Email: francescomangano1@mclink.net

* Private Practice, Palermo, Italy

§ Kois Center, Private Practice, Seattle (WA) USA:
Assistant Professor, University of Washington,
Seattle (WA), USA

^ Private Practice, Milan, Italy

† Private Practice, Baden-Baden, Germany

‡ Private Practice, Gravedona (CO) Italy:
Lecturer, Sechenov First State Medical
University, Moscow, Russia

Received: 13.05.2020
Accepted: 22.06.2020

doi: 10.1922/EJPRD_2105Imburgia14

ABSTRACT

Purpose: To present the results obtained with the “Continuous Scan Strategy” (CSS), a direct intraoral scanning technique based on the connection of the implant scan bodies (SBs) with thermoplastic resin. *Methods:* 40 patients were restored with 45 long-span monolithic implant-supported zirconia restorations (10 partial prostheses [PP] and 35 full arches [FA]) fabricated via a full-digital workflow after the capture of an intraoral impression (Trios3®) using the CSS technique. The primary outcomes were the marginal adaptation and passive fit of the superstructures, checked at T0 (intraoral try-in of polyurethane or metal replica of the final prosthesis) and T1 (delivery of the final zirconia restoration). The secondary outcomes, registered at T2 (2 years after the delivery of the final prosthesis), were implant survival, prosthetic success, and complications. A throughout statistical analysis was performed. *Results:* At T0, 40/45 replicas demonstrated a perfect passive fit and adaptation. At T1, one prosthesis had fractured, and at T2, an additional prosthesis had fractured and one had chipped. The implant survival rate was 100%. The prosthetic success was 93.3%. *Conclusions:* CSS seems to represent a viable option for capturing accurate intraoral digital impressions for the fabrication of precise long-span implant-supported restorations.

INTRODUCTION

The digital revolution is transforming the world of dentistry. Intraoral,^{1,2} desktop³ and face scanners,⁴ condylographs and digital occlusometers,⁵ and cone-beam computed tomography (CBCT)⁶ allow practitioners to acquire three-dimensional (3D) patient information. This information, when loaded into computer-assisted-design (CAD) software, can be combined, allowing patient virtualization,⁷ and is used for the diagnosis and planning of treatment.⁸ Finally, powerful machines such as milling units⁹ and 3D printers¹⁰ allow for the physical production of a whole series of devices, usable in various clinical disciplines (restorative dentistry,¹¹ prosthetics,¹² surgery¹³ and orthodontics¹⁴).

Intraoral scanners (IOSs) are digital devices that capture optical impressions.² The operating mechanism of the IOS is relatively simple: they emit a structured light grid (or less commonly, a laser beam) with known characteristics that impacts the surface of the model.² Upon impact, the grid undergoes deformation that is captured by powerful cameras, which send the signal to the reconstruction software.² This software produces a point cloud, combining all the images captured from different angles, taking

into account the relative movements of the machine, and the distances from the scanned object;^{2,15} this point cloud is triangulated to generate a mesh, or surface reconstruction, of the object.¹⁵

In implant prosthodontics, IOSs allow for direct capture (without the need to take an impression and pour a plaster cast of positive models of the dental arches and therefore of the position of the implants) through the use of the scan bodies (SBs), which are the digital version of the old impression transfer copings.^{2,15} The SBs are mathematically coupled to an implant library; in the CAD software, therefore, the dental technician replaces the mesh of the SB with a bonding base and can model a screwed superstructure or a customized abutment above it, to support the future prosthetic restoration.^{2,15}

The advantages of IOSs are manifold. They eliminate the discomfort caused by conventional tray impressions, which is extremely helpful in patients with a strong gag reflex.¹⁶ Furthermore, they simplify the capture of the impression for the clinician (particularly in the case of multiple implants or in the presence of undercuts), reduce the number of clinical procedures (no need to pour plaster models), and make communication with the dental laboratory easier, saving time and money.^{2,16,17} Finally, IOSs represent a powerful marketing tool with the patient.¹⁷

Several *in vitro*^{1,18-20} and *in vivo*^{12,15,21} studies have demonstrated that IOSs represent an accurate and reliable solution for the capture of impressions in partially edentulous patients for the fabrication of short-span restorations (single crowns [SCs] and partial prostheses [PPs]).

However, other studies^{22,23} and reviews²⁴⁻²⁶ have reported a persistent accuracy problem with intraoral scanning when long-span prosthetic restorations (fixed partial prostheses supported by multiple implants, and full arches [FAs]) must be fabricated. Screw-retained superstructures, (i.e. fixed prostheses screwed directly onto multiple implants) require the highest accuracy, because the acceptable tolerances are minimal, and there is a need for absolute passive fitting.²⁷ Although recent technological improvements have been impressive, IOSs still have challenges when scanning multiple fixtures.²⁷ These difficulties are mainly due to the mechanism by which the IOS acquires the images, which requires “attaching” frames to each other during the process of acquisition. Regardless of the acquisition technology, this intrinsic error is expected to grow with the extension of the scan.^{2,24-26,28} In fully edentulous patients, due to lack of reference points, accuracy is more difficult to achieve when the IOS reads the distance between different SBs, which are also at a different height than the soft tissues.²⁸ Nevertheless, other factors that could be potential sources of inaccuracy include the light conditions,²⁹ the level of operator experience,³⁰ the implant position, depth and angulation,²⁸ and the SBs themselves.³¹ Reducing the distances and the “jump” between the implant SBs could improve the accuracy of the scan, reducing the intrinsic scan error. In totally edentulous patients, Tallarico *et al.*³² introduced a method based on the

3D-printing duplication of the pre-existing removable complete prosthesis. This replica, ground out in the SB area and inserted into the mouth, allows for the capture of a sufficiently accurate impression for the manufacture of a FA fixed restoration (Toronto bridge), as well as simplifying the registration of the vertical dimension of occlusion. Mangano *et al.*³³ developed this strategy, and applied it to the manufacture of bar-retained overdentures, with the bar milled in polyether-ether-ketone (PEEK). More recently, hybrid digital-analog approaches have been proposed, which use custom measuring aids (CMAs)^{34,35} and solid indexes³⁶ to connect the SBs to improve the accuracy of FA digital impressions. The rationale of these approaches is to reduce the distances between the different SBs and to provide artificial landmarks to reduce inaccuracies, thereby allowing for the fabrication of long-span screw-retained superstructures to fit onto implants passively.^{35,36}

Our present retrospective study focuses on this latter strategy, intending to present the clinical results obtained using a novel scanning technique named “Continuous Scan Strategy” (CSS), based on the connection of the scan abutments through thermoplastic resin, thereby eliminating the “jump” between the different SBs and reducing the intrinsic scan error.

MATERIALS AND METHODS

PATIENT DATA, INCLUSION AND EXCLUSION CRITERIA

Patients enrolled in this retrospective clinical study were selected from the customized dental records of two private dental centres (M.I. and E.M. private dental clinics, Palermo and Milan, Italy, respectively).

Inclusion criteria for enrollment in this study were patients who had been treated with multiple (≥ 4) implants (Nobel Active Internal Connection®) via a full digital workflow with the “Continuous Scan Strategy” (CSS) for the restoration with fixed implant-supported prostheses (fixed partial prostheses [PPs] and full arches, [FAs]), over a 4-year period (2014–2017). Further inclusion criteria were the presence of complete documentation within the customized records and a follow-up of at least 2 years from the delivery of the final prosthetic restoration.

Exclusion criteria for this study included any of the following: the presence of systemic diseases or immunocompromised status, uncontrolled diabetes, bisphosphonate therapy (administered parenterally or orally, in the past and/or at the time of enrollment in the study), anti-cancer treatments, alcohol and drug abuse, incomplete documentation, or absence of a follow-up for at least 2 years. Pre- and peri-implant regenerative bone therapies were not considered as criteria of exclusion for the present study (pre-implant regenerative therapies were considered bone regenerative therapies to which the patient underwent 4 to 6 months before implant surgery; conversely, peri-implant regenerative therapies were regenerative procedures made at the time of implant placement).

For the enrolled patients, the chart review included the collection of patient-related (gender, age at the delivery of final implant-supported restoration, presence/absence of parafunctions such as bruxism and clenching, smoking habit), implant-related (site/position of the fixtures, type, length and diameter of the fixtures, presence/absence of bone regeneration procedures), and restoration-related (the type of restoration and delivery date) information. In addition, the customized patient records noted all the biologic or prosthetic complications (mechanical or technical) that had occurred during the entire follow-up period, as well as any implant failure that had occurred. Complications or failures were noted both if patients returned to the dental clinic for treatment and were also intercepted during annual scheduled check-ups (at least 2 control visits per year for all patients, with professional oral hygiene sessions). All this information, along with the clinical photographs taken during the different phases of the prosthetic treatment and the related radiographs, were the basis for this retrospective study and were used for the statistical analysis.

The present retrospective clinical study was conducted in full compliance with the principles of the Declaration of Helsinki on Clinical Research and Experimentation in Humans (revision 2008).

PROSTHETIC TECHNIQUE

The proposed intraoral scanning technique presented in the study, named the "Continuous Scan Strategy" (CSS), is based on the direct connection between the implant SBs through thermoplastic resin. This technique aims to reduce the level of inaccuracy of intraoral digital impressions by eliminating the problem of the distance between the SBs, which are connected by thermoplastic resin; this connection also reduces the vertical "jump" that the IOS must make from one SB to another and during the registration of soft tissues between the different SBs.

The scanning technique proceeded as described. One-piece titanium SBs (Scan Abutment AQ®) were screwed onto the implants, with the notch surface or the oblique section in the head oriented towards the buccal side. After confirming the SBs were screwed correctly, the thermoplastic resin was heated and molded intraorally to connect the different SBs to each other on the palatal/lingual side. To increase the stability of the thermoplastic resin and avoid detachments, small quantities of flowable composite resin were added laterally to the SBs to connect them with the thermoplastic resin. They were then polymerized to ensure the assembly. Neither the thermoplastic material nor the composite interfered with the notch surface (marker surface) of the SB, whose head must be completely free and visible. Once the stability and rigidity of the elements thus assembled were verified (SB, thermoplastic resin and flowable composite resin), it was possible to proceed with the scanning using the IOS (Trios3®), conducted through a "zig-zag" technique. The technique started from the more distal SB (palatal/lingual side) and passed above it to end in the buccal

area, with progressive advancement guided by the thermoplastic resin until the next SB. Particular attention was paid to the capture of all the details of the SB. Once the scan was captured and the mesh quality checked, the standard tessellation files (.STL) were sent to the dental technician for modelling the final structure in CAD software. Care was taken during the CAD modelling to perform the best possible superimposition (best-fit) of the library files of the SB onto the corresponding meshes. If the superimposition was perfect, with an overall mean deviation of $\leq 20 \mu\text{m}$, the technician could proceed.

In the CAD software, appropriate titanium bases were selected, and the final prosthetic superstructure was designed. Then a replica of the same superstructure was milled with a 5-axis milling machine (DWX-52®) into a rigid and radiopaque material (polyurethane for the PPs, metal for the FAs). This replica was used to test the passive intraoral adaptation (verification of the "passive fitting" or Sheffield test) of the final prosthesis. This grey and radiopaque replica was screwed into the mouth on the corresponding titanium bases and its marginal adaptation was verified, both clinically and radiographically. A series of intraoral x-rays were captured to verify the quality of the fitting. If the quality of the passive adaptation was optimal, the technician could proceed with the manufacture of the final zirconia prosthesis, starting from the CAD project itself. If it was not, or the values detected through the best fit in the early stages of the CAD were considered unreliable ($\geq 30 \mu\text{m}$), the clinician proceeded to separate the polyurethane replica into several parts until a passive adaptation was obtained; these portions were connected intraorally with low-contraction resin, and the assembly was transferred to the technician who re-scanned it with a desktop scanner and modified the CAD project accordingly. After the passive fitting and the optimal adaptation of the structures were confirmed, the prosthetic CAD project was ready to be used for the manufacture of the final prosthesis. The final monolithic zirconia prosthesis (Katana ML®) was milled with the same 5-axis milling machine (DWX-52®), sintered and, if necessary, coloured on the buccal surfaces. Particular attention was paid to the milling of the engagements for the titanium luting bases, to provide close correspondence between the parts, and a unique position. The position of the luting base was determined only and exclusively by the housing milled inside the zirconia structure. The milling parameters of the aforementioned interface were kept "tight", thus avoiding any play that could have inserted inaccuracies and, consequently, a misfit of the structure. At this point, the dental technician could cement the luting bases chosen during the CAD modelling inside the monolithic structure. This cementation took place extraorally, using anaerobic cement (Variolink Hybrid Abutment®); no luting was performed within the patient's oral cavity. The luting of the titanium bases to the monolithic structure was carried out in all cases without the aid of any 3D printed model. After this, the final monolithic zirconia prosthesis was ready to be delivered to the clinician for application.

OUTCOME VARIABLES

The primary outcome of this study was the marginal quality of closure of the superstructures and their passive fit. This outcome was recorded in two stages: at the time of testing the final structure, by means of a milled replica in polyurethane or metal (time 0 = T0), and at the time of delivery of the final monolithic zirconia restoration (time 1 = T1). The marginal closure and adaptation were determined through careful clinical and manual inspection by the prosthodontist, who worked with magnifying glasses (Zeiss 4.5%®), and were confirmed by intraoral radiographs of all implant platforms.

The secondary outcomes of the present study were the survival of the implants and the success of the prostheses. These outcomes were collected 2 years after delivery of the final prostheses (time 2 = T2) and were recorded during the scheduled recall visits for professional hygiene. Implant survival indicated that all the implants were regularly in function, under masticatory load; implants that were lost for any reason (fracture of the fixture, loss of osseointegration, or removal of the implant due to mechanical overload or infection) were classified as failures. Finally, prosthetic success indicated that the final monolithic zirconia prosthesis was regularly in function during the entire period 2-year follow-up (from delivery to final inspection) without the occurrence of any major mechanical (such as macroscopic fractures of the framework), minor mechanical (related to the pre-established components sold by the implant manufacturer, e.g., screw loosening) or minor technical (related to superstructure problems, such as chipping) complications.

STATISTICAL ANALYSIS

The data collected from the records of the patients enrolled in the study were entered into a spreadsheet (Excel 2003®) and included in statistical analysis. First, a descriptive analysis of the patient population and the implant-supported restorations were performed. This analysis was based on patient demographics (gender, age at the delivery of the final restoration, smoking habit, and history of parafunctions), distribution of the implants (site and position, length and diameter, association with bone regeneration procedures), and type of implant-supported prosthesis (PP or FA). For this descriptive analysis, mean \pm standard deviation (SD), range, median, and 95% confidence interval (CI) were calculated for quantitative variables (e.g., patient age). For the qualitative variables (i.e., patient gender, smoking habit, history of parafunction; site and position, length and diameter of the implants, association with bone regenerative procedures and type of prosthetic restoration), absolute (n°) and relative (%) distributions were calculated. Using this information, the Chi-square test was utilized to assess homogeneity or non-homogeneity within the groups, with a level of significance set at $p < 0.05$.

The primary outcomes of the study (i.e., the clinical and radiographic quality of the adaptation and the passive fitting of the prosthetic superstructures) were investigated both at the time

of testing the final structure through a polyurethane or metal (T0) replica, and at the time of delivery of the final monolithic zirconia prosthesis (T1), and were assessed by the prosthodontist. A binary code of satisfactory or unsatisfactory was used. If the adaptation and passive fitting were satisfactory at T0, the laboratory could fabricate the final zirconia prosthesis, using the same CAD project; if they were not, the dentist had to separate the polyurethane or metal replica into several parts until a passive adaptation was obtained. These portions were then luted intraorally with low-contraction resin, and the assembly was transferred to the technician who re-scanned it with a desktop scanner and modified the CAD project accordingly. If the adaptation or passive fitting were adequate at T0, but not adequate at T1, the work was sent back to the laboratory for refurbishment.

Finally, with regards to the secondary outcomes of the study, i.e., the variables investigated during the scheduled follow-up control 2 years after the delivery of the final prosthesis, the incidence (%) of failures and complications was calculated. The survival of implants and of the prostheses were calculated at the implant- and at the restoration-level, respectively. The occurrence of a single event or complication during the 2-year follow-up period was sufficient to allocate the prosthesis into the failure category.

RESULTS

The analysis of the personalized medical records of the two different dental offices involved in this retrospective clinical study revealed that over a period of 4 years (2014–2017), a total of 40 patients (15 males, 25 females; age 45–74 years, average age 62.1 ± 8.1 years; median 65 years; CI 95% 59.6–64.6 years) met the conditions set out in the inclusion criteria, and also did not have any of the conditions established in the exclusion criteria. Of these patients, 6 had a clinical history of parafunction or bruxism, and 9 were smokers. The characteristics of the enrolled patients are summarized in Table 1. Most of the enrolled patients were non-smokers ($p = .010$) and had no parafunctions ($p = .0008$).

In all, over the period indicated above, 45 prosthetic rehabilitations were constructed, of which 10 fixed PP (8 maxillary, 2 mandibular) were supported by ≥ 4 implants, and 35 FA (20 maxillary, 15 mandibular) were supported by 6–8 implants. In all cases, the implants used were Nobel Active Internal Connection®. The characteristics of the implants, their distribution based on position, length and diameter, the association (or not) with bone regeneration techniques and the type of restoration supported by them are summarized in Table 2. The majority of the implants were located in the maxilla ($p < .00001$), and most of the implants were in native bone ($p < .00001$), and placed to support FAs ($p < .00001$).

In all cases, the rehabilitations were performed following the CSS protocol, starting from a direct optical impression with IOS and consisting of monolithic full zirconia prostheses, screwed

Table 1. Distribution (number, %) of the patients by gender, age at surgery, smoking habit and history of parafunctions (clenching and bruxism).

	Patients number	%	p*
Gender			
Males	15	37.5%	.259
Females	25	62.5%	
Age at surgery			
45- 54 years	8	20%	.186
55- 64 years	10	25%	
65- 74 years	22	55%	
Smoke			
Yes	9	22.5%	.010
No	31	77.5%	
History of parafunction			
Yes	6	15%	.0008
No	34	85%	
Total	40	100%	-

p* = Chi-square test.

directly onto the implants (Figures 1-12). Implant disparallelisms were limited due to computer-guided implant planning and positioning; however, if, for anatomical limits, the implant axis did not coincide with the prosthetic axis, a digital correction of the angled screw hole was made, using connection screws with Cardan engagement.

In 40 out of 45 cases, the marginal adaptation of the prostheses at T0 (proof of the replica in polyurethane or metal) was optimal and the case could proceed directly to the production phase of the final prosthesis. In five cases, however, passive adaptation was not optimal; therefore, the clinician proceeded to separate the polyurethane or metal replica into several parts, until a passive adaptation was obtained. These portions were then luted intraorally with low-contraction resin, and the assembly was transferred to the technician who re-scanned it with a desktop scanner and modified the CAD project accordingly. In all these cases, > 30 µm distances between meshes and libraries of multiple SBs had emerged during the early stages of CAD (best-fit).

Table 2. Distribution (number, %) of the implants by position, length, diameter, bone regeneration and type of prosthesis.

	Implants number	%	p*
Position			
Maxilla	215	83.3%	<.00001
Mandible	43	16.7%	
Length			
10 mm	114	44.2%	.007
11.5 mm	87	33.7%	
13 mm	57	22.1%	
Diameter			
3.0 mm	59	22.8%	.021
3.5 mm	91	35.3%	
4.3 mm	108	41.9%	
Bone regeneration			
Yes	28	10.9%	<.00001
No	230	89.1%	
Type of prosthesis			
PP	48	18.6%	<.00001
FA	210	81.4%	
Total	258	100%	

p* = Chi-square test.

At the time of delivery of the final monolithic zirconia prostheses (T1), there were no complications, since the passive fit and the marginal adaptation of 44 of the 45 prosthetic structures was optimal. However, in a case of mandibular FA in a 56-year-old woman, a minimal friction problem emerged at the time of screwing, which did not seem to prevent the correct positioning of the prosthesis. The prosthesis was screwed on, but a few minutes later, following a patient yawn, the prosthesis fractured in the middle portion (area of the incisors). This fracture was therefore attributed to an imperfect passive fit and mandibular flexure in maximum opening. In addition, the design of the structure had reduced thicknesses in the area surrounding the Ti Base of the more anterior implant. This complication was solved by redesigning a new prosthesis.

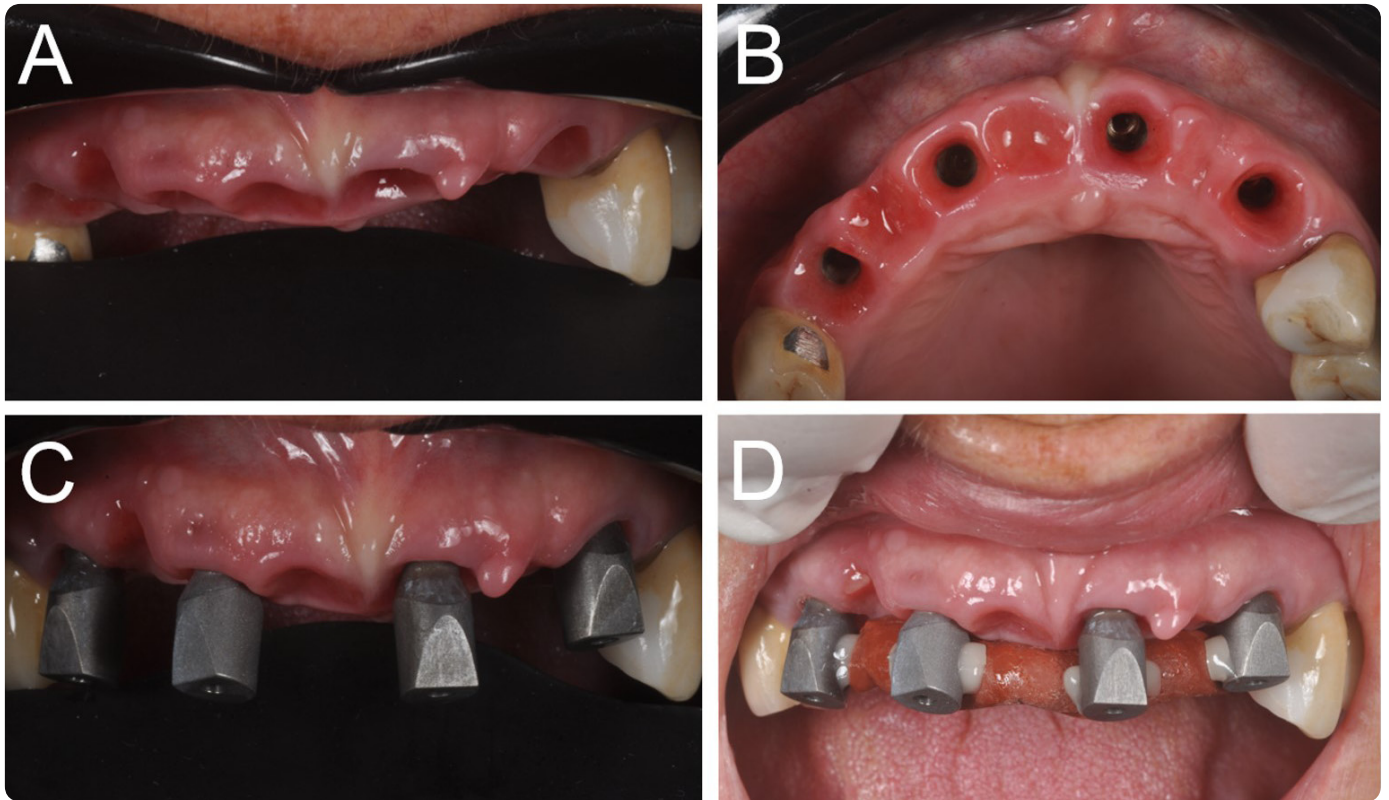


Figure 1: Partially edentulous patient with four implants in the anterior maxilla: clinical pictures of the scanning procedure. (A) Frontal view: the mucosal collars after the removal of the healing abutments. (B) Occlusal view: the mucosal collars are visible. (C) The SBs are screwed on the four implants. (D) Thermoplastic material and composite resin are used to connect the SBs, avoiding any interference with their marker surfaces and heads.

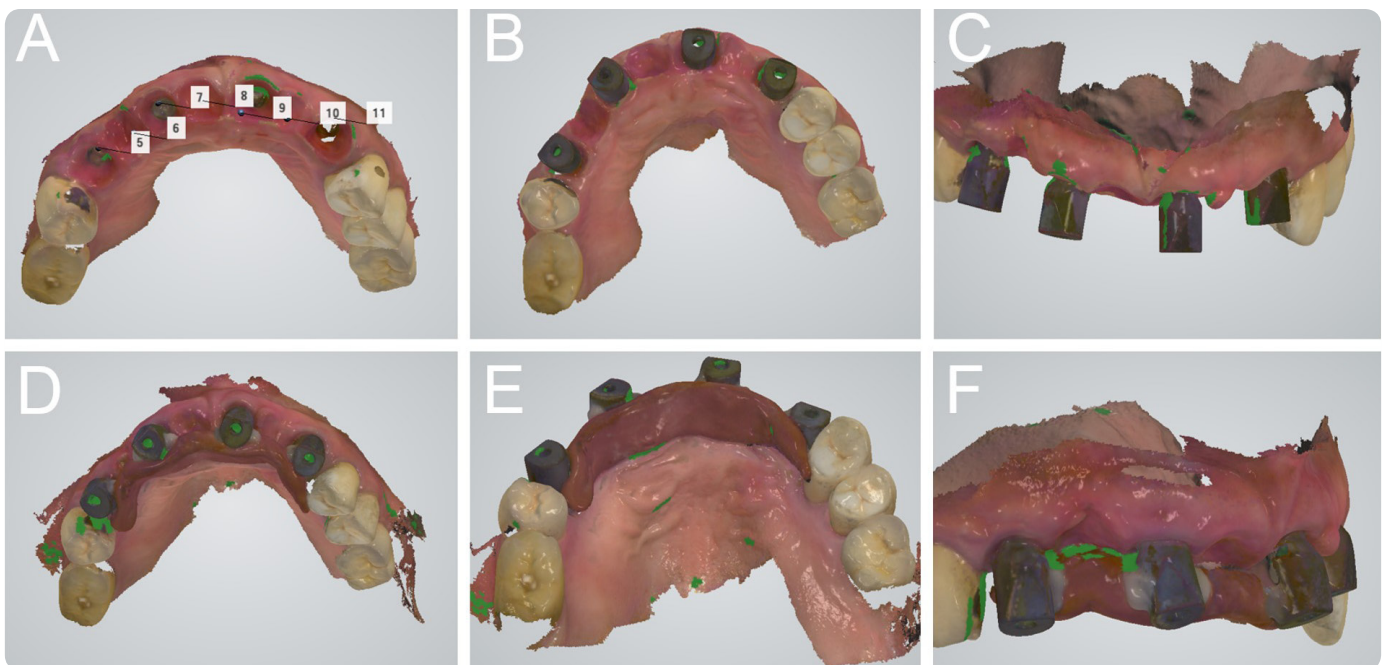


Figure 2: Partially edentulous patient with four implants in the anterior maxilla: screenshots of the intraoral scan. (A) Occlusal view: the mucosal collars after the removal of the healing abutments. (B) Occlusal view: the SBs are screwed on the four implants. (C) Frontal view of the SBs. (D) Occlusal view: thermoplastic material and composite resin connect the SBs, avoiding interference with the SB marker surfaces and heads. (E) Palatal view of the SBs linked with thermoplastic material and resin. (F) Lateral view of the assembly.

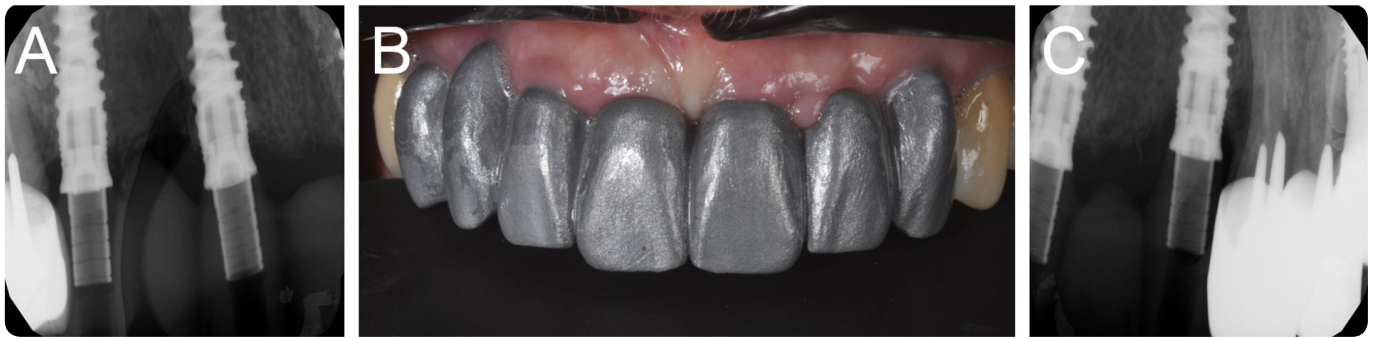

Figure 3: A replica of the final CAD project is milled in polyurethane hard resin and screwed intraorally to verify the passive fitting and the marginal adaptation. Intraoral radiographs are taken to verify the adaptation. (A) Radiographic image of the replica, implants in the right side. (B) The milled replica screwed intraorally. (C) Radiographic image of the replica, implants in the left side.

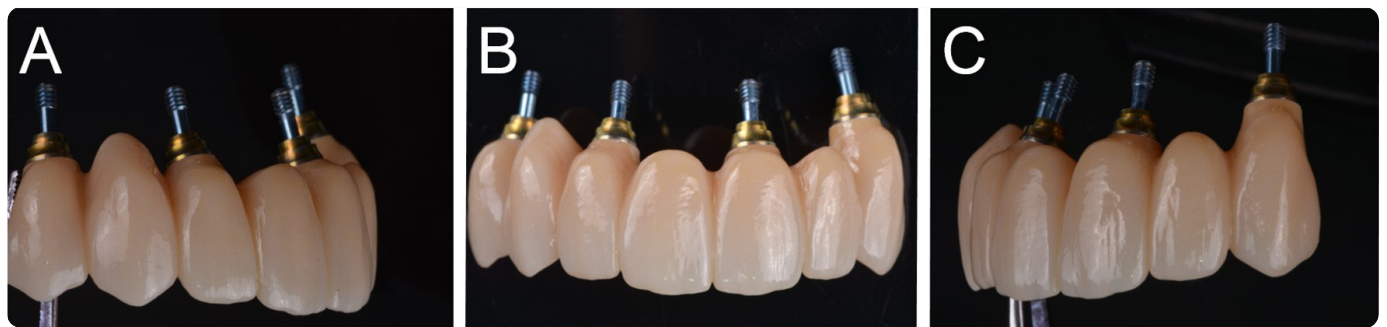

Figure 4: The final screw-retained fixed PP is ready to be delivered to patient. (A) Right view. (B) Frontal view. (C) Left view.

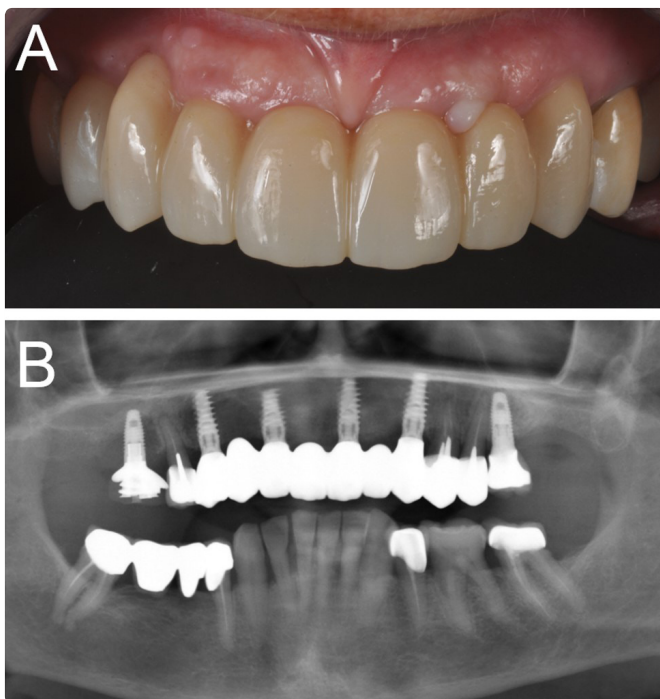


Figure 5: Delivery of the final screw-retained fixed PP. The same CAD project of the milled prototype is duplicated in zirconia. (A) Clinical view. (B) Panoramic radiograph.

Two years after the delivery of the final restorations (T2), the implant success was high (100%) with all implants in function, but another prosthesis fracture occurred in a mandibular FA of a 66-year-old man. The prosthesis had to be replaced with a new one, and again the fracture occurred in an area where

the thickness of zirconia was non-optimal. Another complication occurred in a maxillary FA of a 68-year-old female, due to chipping of a distal extension on the right upper first molar; however, this complication was solved simply by polishing the surface of the fractured connector. At the end of the study, 42/45 final zirconia prosthesis (93.3%) were considered successful because they functioned without any complications registered during the subsequent two years. Conversely, the incidence of prosthetic complications was 6.7%. Among these complications, two (fractures of the zirconia framework) were major, and one (chipping) was minor. Regardless, all these complications were technical.

DISCUSSION

To date, multiple published reports have proposed that the insufficient accuracy of IOS in capturing impressions for the manufacture of long-span restorations (such as FA) is the significant limit to the use of these machines in implant prosthodontics.²²⁻²⁶

Although there are statistically significant differences in the accuracy of the various IOS on the market, numerous scientific studies^{22,23} and reviews of the literature²⁴⁻²⁶ have confirmed the intrinsic difficulty of scanners in capturing multiple implant impressions, particularly in completely edentulous patients. It is now clear that the inaccuracy of the models generated by direct intraoral scanning does not depend solely on the machine and therefore on the technology used for the acquisition,² but also on other factors (lighting conditions,²⁹

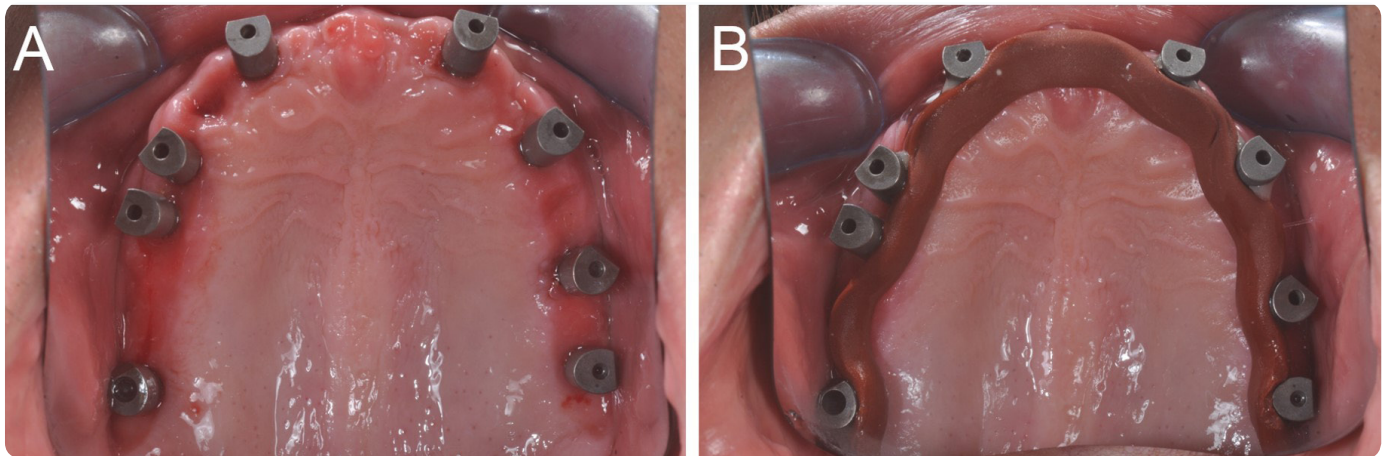


Figure 6: Fully edentulous patient with eight implants in the maxilla: intraoral scan. (A) Occlusal view of the SBs screwed on the eight implants. (B) Before taking the intraoral scan, thermoplastic resin is used to connect the SBs, avoiding any interference with their marker surfaces and heads.

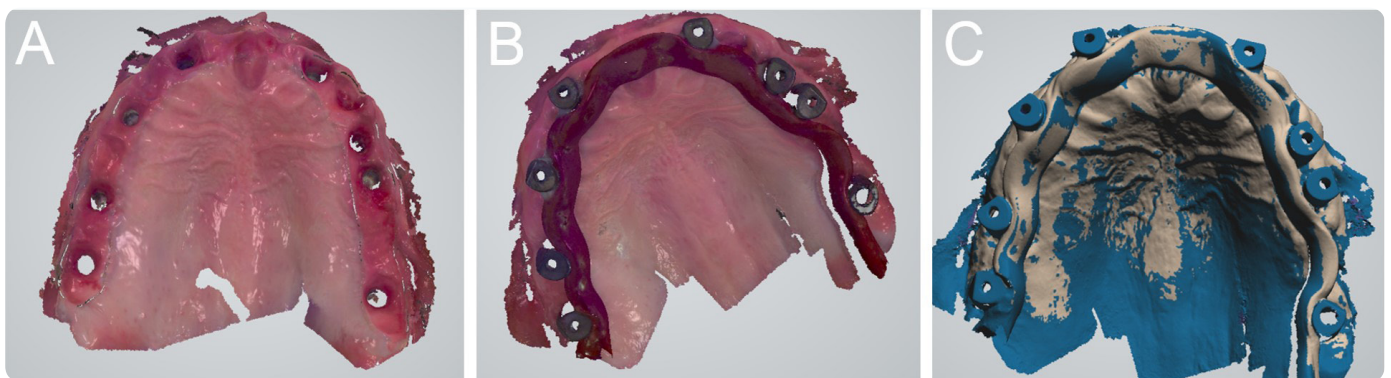


Figure 7: An intraoral scan of a fully edentulous patient with eight implants in the maxilla. (A) Occlusal view of the mucosal collars. (B) Occlusal view of the implant SBs screwed on the eight implants and linked with thermoplastic resin. (C) Occlusal view of the assembly. Thermoplastic resin is used to connect the SBs, avoiding any interference with their marker surfaces and heads.

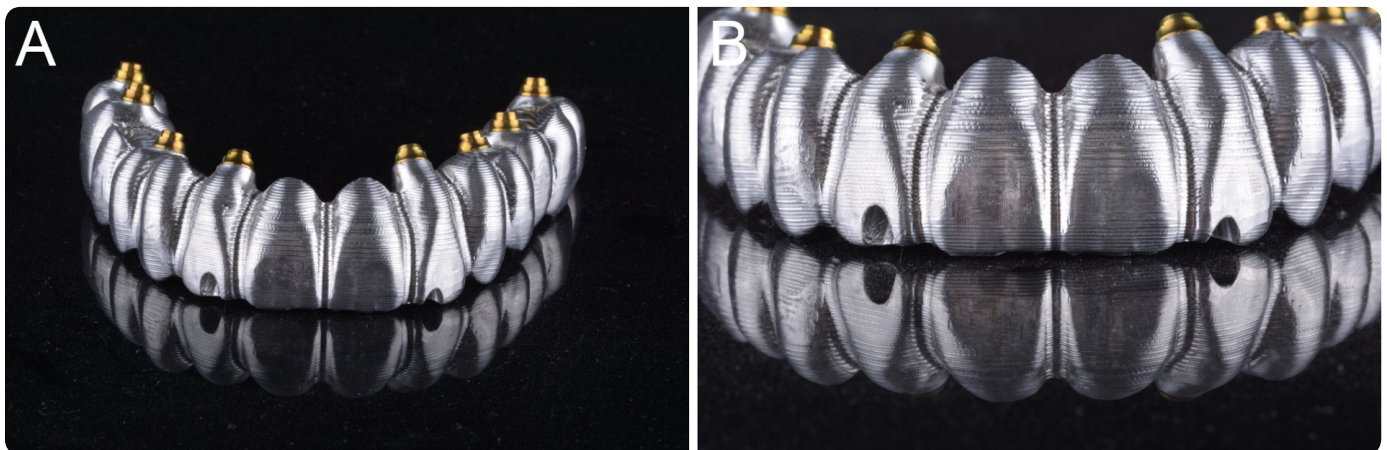


Figure 8: A replica of the final CAD project milled in metal. This replica is useful to verify the passive fit and the marginal adaptation intraorally. (A) The milled replica, frontal view. (B) Details of the milled replica.

operator experience and scanning strategy,³⁰ position, inclination and depth of the implants, design and material of the SB³¹).

At the level of intrinsic error, however, it is now established that one of the most significant difficulties for IOS lies in the correct reading and reproduction of the spaces between the

different SBs.^{23,28} These spaces are, in fact, devoid of physical references, with a “vertical” spatial “jump” between two SBs. It is precisely this distance and the absence of spatial reference points that cause difficulties for the IOS reconstruction software.²⁸ For this reason, some authors have tried to reduce these spaces and distances, introducing replicas or custom devices to facilitate reading by scanners.³²⁻³⁶

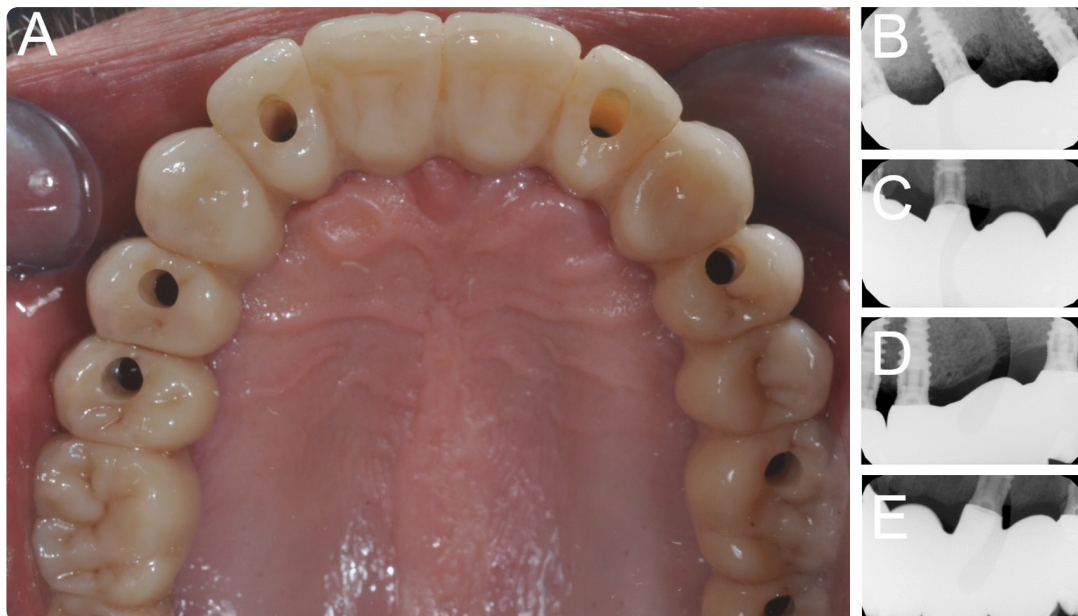

Figure 9: The final fixed FA is screwed onto the implants with excellent adaptation and passive fit. (A) Occlusal view of the prosthesis in position. (B-C-D-E) Intraoral radiographs confirm the absence of gaps and misfits at the level of the connection.

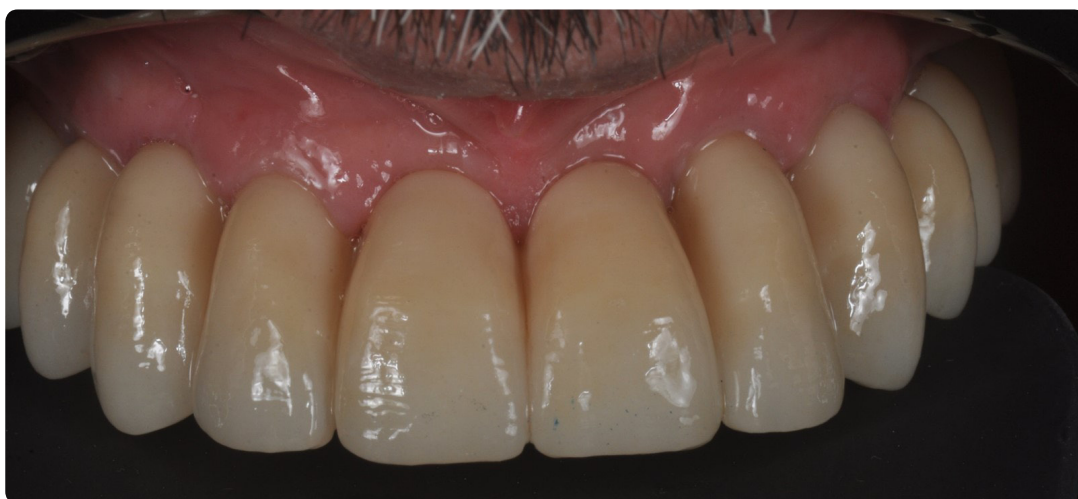

Figure 10: The final fixed FA is delivered to the patient.

In an *in vivo* study, Tallarico *et al.*³² introduced a replica of the patient's total prosthesis, open in the SB area, to facilitate the scanning and reading of the spaces between one scan abutment and the other. This replica allows for accurate capture, through intraoral scanning, of the initial vertical dimension of patient occlusion, very useful data for the dental technician.³² A similar approach has been followed by Mangano *et al.*³³, who resolved 15 cases of completely edentulous patients rehabilitated with an overdenture supported by a polyether-etherketone (PEEK) bar and four implants. This approach is notable because it also allows for the capture of the vertical dimension of occlusion and, potentially, the development of a completely digital prosthesis project. This improvement is due to the physical capture of the pre-existing prosthesis extraorally, which is then virtually superimposed to that which is captured intraorally.³³ This capture allows, due to the inversion of the normals, for

functionalized mucosal bases to be obtained, useful for the digital modelling of the prosthesis.³³ The limit of this approach is, however, that an additional appointment is required to capture the impression for the fabrication of the replica of the pre-existing prosthesis. In addition, a 3D printer is needed to fabricate this replica, which must be "opened" virtually or manually, to allow the SB to be housed without impeding their complete acquisition during the optical impression.^{32,33}

A different approach has been proposed by other authors: the introduction of custom devices of different shapes, also useful for assessing and checking the accuracy of intraoral scanning.³⁴⁻³⁶ In an *in vitro* study, Iturrate *et al.*³⁴ introduced a custom device of known dimensions, manufactured and connected onto a model of an edentulous maxilla with 4 SBs. This model was scanned with different IOSs, with and without the auxiliary device.³⁴ At the end of the study, the presence of the

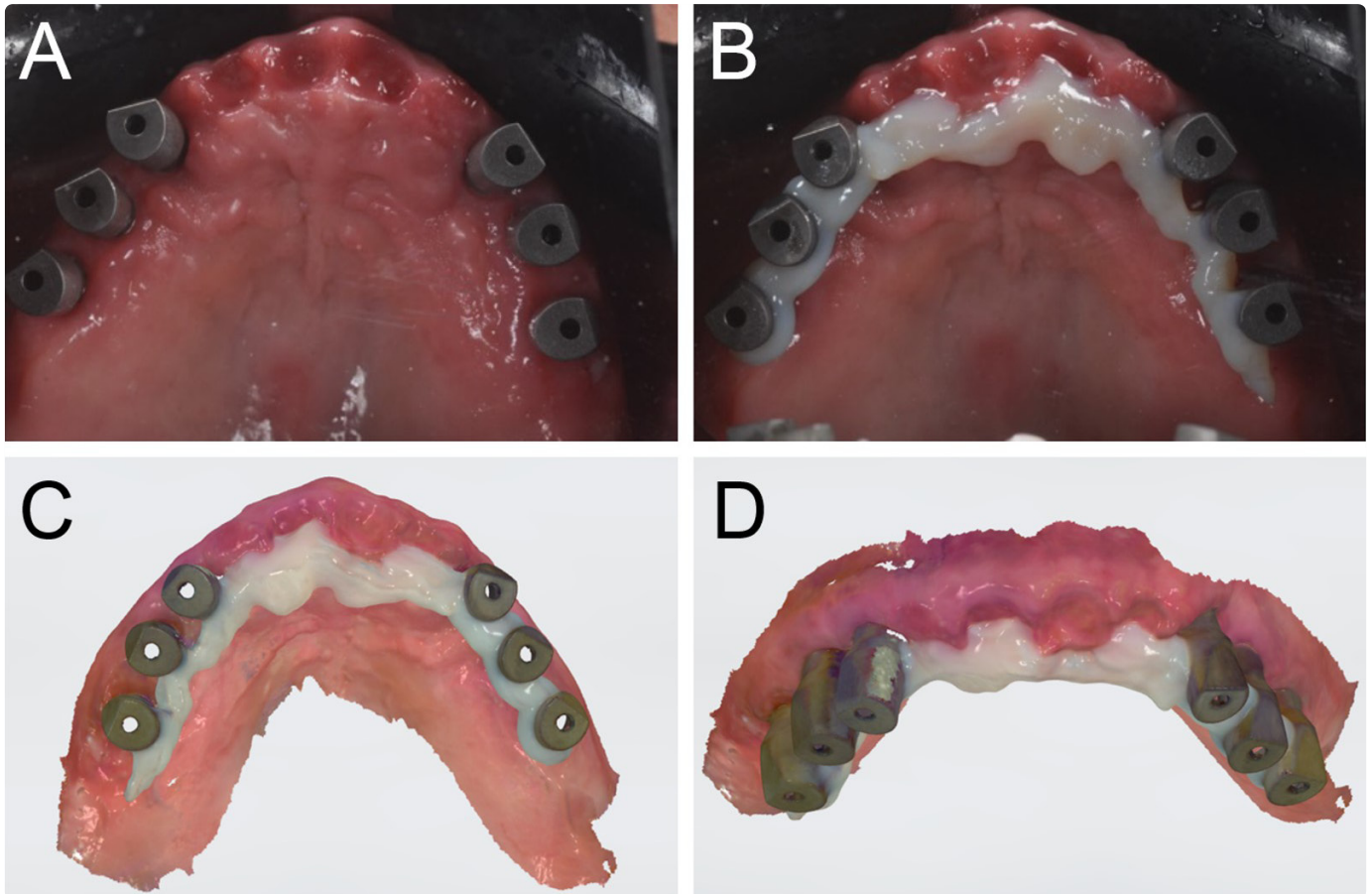


Figure 11: Fully edentulous patient with six implants in the maxilla. (A) The SBs are screwed on the six implants. (B) Prior to taking the intraoral scan, composite resin (that can be used, as a variant of the technique, instead of thermoplastic resin) is used to connect the SBs, avoiding any interference with their marker surfaces and heads. (C) Occlusal view of the scan captured with the SBs linked with composite resin. (D) Frontal view of the SBs linked with composite resin.

auxiliary device proved useful as it served as a spatial reference rich in anatomical landmarks for scanning, and was, therefore, able to improve the accuracy of the optical impression, regardless of the type of IOS used.³⁴ A similar strategy was employed by Gomez-Polo *et al.*,³⁵ who presented a technique for increasing the accuracy of intraoral scanning for FA prostheses and for correcting deviations and distortions that occur during direct intraoral scanning processes. The strategy employed a reference-marked rigid splint with known geometric features capable of providing the scanner with reference points and therefore reducing the deviation and errors given by the “jump” between the different SBs.³⁵ This method was based on sectioning and best-aligning the scanned files to generate a more accurate definitive cast and consequently a better-fitting restoration.³⁵

Finally, the approach proposed by Schmidt *et al.*³⁶ and Mandelli *et al.*³⁷ is different but notable. Schmidt *et al.*³⁶ used a solid index to better assess inter-implant distances *in vitro* and *in vivo*. The authors prepared an *in vitro* model of a partially edentulous maxilla with four implant analogues in the posterior regions; they screwed on the SBs and scanned the model with a reference industrial machine.³⁶ Then, the same model was scanned with an IOS 10 times. The authors then connected the SBs to a custom solid index or CMA, consisting of four hollow

connected cylinders with a parallelepiped of known dimensions positioned on the palate. A minimum quantity of polyether impression material was used for connecting the SBs to the solid index. After the material had hardened, the assembly was unscrewed and sent to the dental laboratory to undergo investigation with a coordinate measuring machine (CMM). The inter-implant distances were assessed. Finally, 10 conventional impressions of the maxilla were taken, plaster models were poured and the same CMM was used to assess the implant distances.³⁶ The authors compared the accuracy of the different methods and found that significantly higher trueness was achieved with the solid index.³⁶ These results were confirmed *in vivo*, in a series of three cases made under the same protocol. The authors concluded that the CMA was proven to reproduce the 3-D inter-implant distances better than conventional or digital impression, with significantly higher accuracy.³⁶

Mandelli *et al.*³⁷ presented the clinical results obtained with a similar hybrid digital–analogue technique, solid index impression protocol (SIIP), which used a solid custom-made index to capture accurate impressions of multiple implants for the fabrication of implant-supported fixed full arches (FAs). Five patients were treated with a FA supported by four implants. Three months after implant placement, impressions were taken for

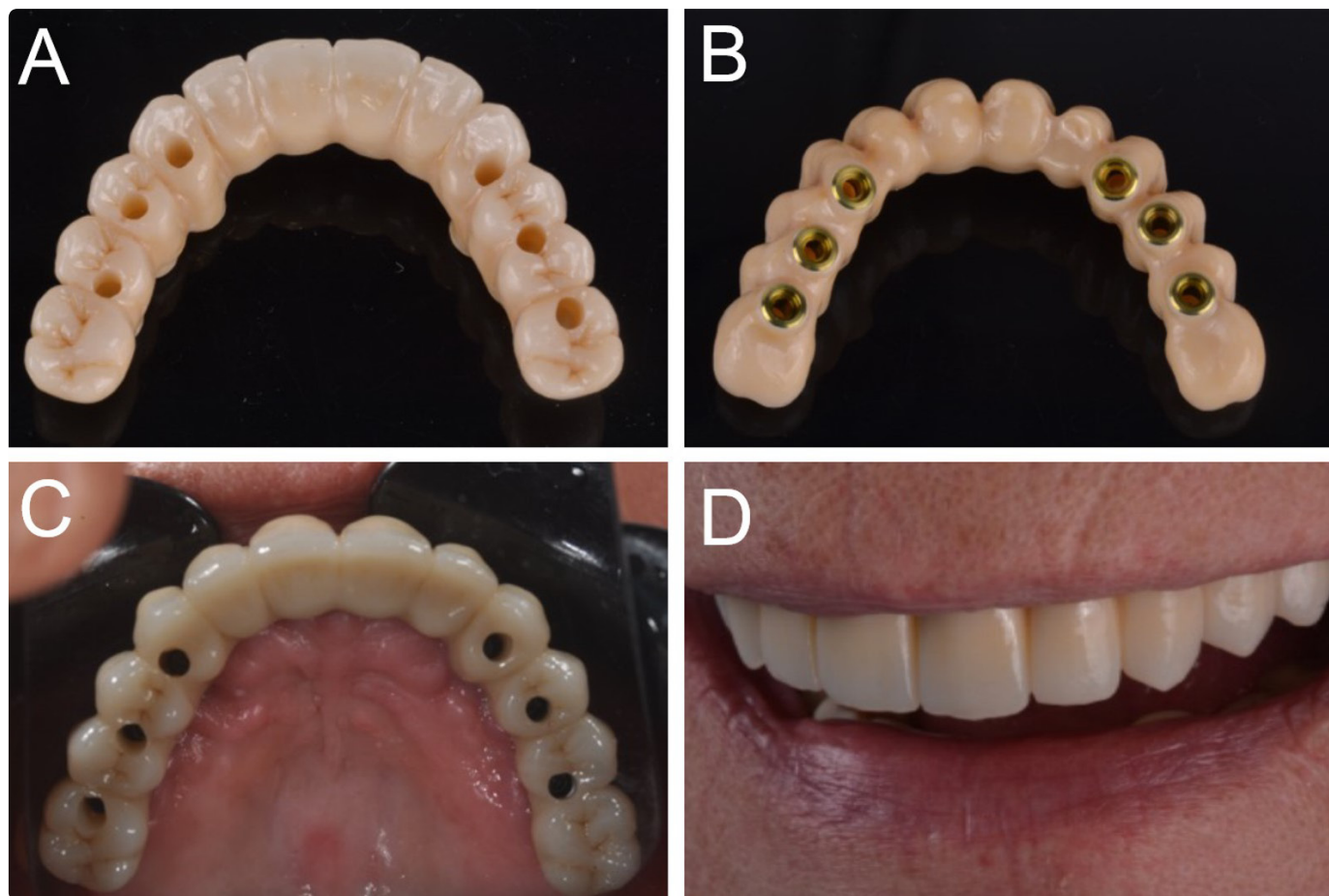


Figure 12: Fully edentulous patient with six implants in the maxilla. (A) The final restoration as fabricated by the laboratory. (B) View of the implant connections. (C) Delivery of the final restoration. (D) Aesthetic integration of the final restoration.

all patients with an IOS (direct digital impression) and with SIIP, using a custom tray consisting of four hollow cylinders connected with a bar.³⁷ This index, linked to the implant transfers, was transferred to the laboratory and used as the basis for fabricating the definitive FAs.³⁷ Excellent clinical precision and passive fit were obtained in all five implant-supported fixed FAs fabricated with SIIP.³⁷ One year after delivery, all fixed FAs were functional without any complications.³⁷ Finally, differences in accuracy were found between SIIP and direct intraoral scanning.³⁷ The authors concluded that SIIP seems to represent a viable option for capturing accurate impressions for the fabrication of clinically precise implant-supported fixed FAs with a hybrid digital-analogue workflow.³⁷ The advantage of the approach presented by Schmidt *et al.*³⁶ and Mandelli *et al.*³⁷ is the ability to register a highly accurate impression, using a solid custom index, and also the possibility of controlling the quality of the direct intraoral scan, also with the aid of CMM. The limit of this approach, however, is given by the need for an extra intraoral scan, preliminary to the preparation of the solid index, which must be modelled and printed in 3D: this requires time and specific skills. Furthermore, the workflow, in this case, is not entirely digital.^{36,37}

Our present retrospective clinical study presents an easier and more direct, entirely digital approach, which consists of the intraoral connection of the implant SBs using thermoplastic

resin. Once modelled and cured, this resin is further fixed to the SBs through flowable composite, and the entire assembly is scanned through direct intraoral scanning with Trios3®, an IOS that several studies have reported being highly accurate.^{19,21,27,38} This approach allowed us to obtain excellent passive fit and marginal adaptation of the implant superstructures at T0 (intraoral try-in of the polyurethane or metal replicas) with only 5/45 prostheses revealing unsatisfactory clinical precision. In these 5 FA cases, however, the clinician proceeded to separate the polyurethane or metal replica into several parts until a passive adaptation was obtained. These portions were then luted intraorally with low-contraction resin, and the assembly was transferred to the technician who re-scanned it with a desktop scanner and modified the CAD project accordingly. It is important to underline the fact that one-piece titanium SBs have been used in this study. This may represent an advantage because one-piece metal SBs are easier to fabricate for the manufacturer (as manufacturing tolerances with PEEK are more difficult to control) and help to minimize the positional errors that may potentially affect two-pieces (titanium-PEEK) SBs, due to tolerances in the assembly.³⁹ It is also important to note how in all these cases, a distance > 30 µm between meshes and libraries of multiple SBs had emerged during the early stages of CAD (best-fit): this may be considered an indicator of error and may highlight the importance of the

congruence between the mesh and the library file of the SBs. In fact, in the absence of perfect congruence between these two files in the early CAD stages, a positional error may arise. This topic needs to be adequately addressed by the scientific literature. At T1, however, all final monolithic zirconia revealed excellent passive fit and adaptation, except one that revealed a minimal friction, and fractured several minutes after being screwed. The authors believe this minimal misfit had caused fracture due to mandibular flexion since it occurred following a patient yawn. At T2, the implant success was high (100%), and no mechanical complications (i.e., complications affecting pre-established components sold by the implant manufacturer) occurred. However, another prosthesis fracture occurred. Finally, a chipping occurred in a distal extension on the right upper first molar; however, this complication was solved simply by polishing the surface of the fractured connector. Therefore, the incidence of prosthetic complications was 6.7%, and the overall 2-year prosthetic success was 93.3%.

The limitations of this study include a relatively brief (up to 2 years) follow-up period after the delivery of the final zirconia restorations; in addition, the retrospective study design is not the most suitable to draw definitive conclusions on the reliability of the present direct intraoral scanning technique. Furthermore, most of the prosthetic restorations were delivered in the maxilla, that offers more stable landmarks for the IOS (such as the palate) to reduce scan inaccuracies, when compared with the mandible (that lacks of references and has the tongue that may disturb the operator during scanning). The design of this study is essentially clinical, the protocol does not allow for proper mathematical quantification of the scanning error. In other words, it is not possible to quantitatively verify the mathematical accuracy of the scans, since the only controls are clinical, with a clinical and radiographic assessment of the marginal closure of the superstructures and their passive fit: this can be considered another limit of this study. Finally, in this clinical study, a highly accurate IOS (Trios3®) has been used by an experienced operator, and the results obtained here cannot be generalized and automatically considered valid also for other scanners. Hence, further long-term prospective clinical studies are essential to confirm the positive outcomes observed.

CONCLUSIONS

At present, the scientific literature does not consider direct intraoral scanning a sufficiently reliable method to capture impressions for the fabrication of long-span implant-supported prosthetic restorations, particularly in the case of FAs. Our present retrospective clinical study presents the clinical results obtained with a novel intraoral scanning technique, named "Continuous Scan Strategy" (CSS), based on the connection of the scan abutments through thermoplastic resin, to eliminate the "jump" between the different SBs and therefore reduce the intrinsic scan error. Over a four-year period, 40 patients were enrolled in our study and restored with 45 long-span implant-supported restorations (10 fixed PPs supported by ≥ 4 implants

and 35 FAs supported by 6–8 implants) fabricated via a full-digital workflow after the capture of an intraoral impression following the CSS technique. At the time of the intraoral try-in of the polyurethane or metal replica of the final prosthesis, 40/45 replicas had a perfect passive fit and adaptation. At the delivery of the final restorations, one prosthesis fractured, and another fracture and a chipping occurred at T2. The implant survival rate amounted to 100%. The prosthetic success was 93.3%, with a low incidence (6.7%) of complications. Therefore, CSS appears to represent a viable option for capturing accurate intraoral digital impressions for the fabrication of precise long-span implant-supported restorations. However, this study is retrospective and has a short follow-up. Most of the prosthetic restorations were delivered in the maxilla, that offers more stable landmarks for the IOS (such as the palate) to reduce scan inaccuracies, when compared with the mandible. Moreover, the design of this study is essentially clinical, since the protocol does not allow for proper mathematical quantification of the scanning error. Finally, only one IOS (Trios3®) has been used in this study, by an experienced operator, and the results obtained here cannot be generalized also to other scanners. Further long-term follow-up studies are needed to confirm these positive results.

ACKNOWLEDGMENTS

The authors are grateful to the master dental technicians Giuseppe Emanuele and Massimiliano Motisi, owners of *Mediterranea Odontoprotesi* (Palermo, Italy), and to the master dental technicians Lorenzo Cattaneo, Alessandro Giglio, Pietro Pendo-la, Barbara Zaina, owners of *D-Lab* (Milan, Italy) for the precise work and the extraordinary human skills that have allowed us to develop innovative and efficient workflows.

MANUFACTURERS' DETAILS

- Nobel Active Internal Connection®, Nobel Biocare, Zurich, Switzerland
- Scan Abutment AQ®, New Ancorvis Srl, Calderara di Reno, BO, Italy
- Trios3®, 3-SHAPE, Copenhagen, Denmark
- DWX-52®, DGSHAPE a Roland Company, Hamamatsu, Japan
- Zeiss 4.5%®, Zeiss, Oberkochen, Germany
- Katana ML®, Kuraray Noritake, Japan, Tokyo
- Variolink Hybrid Abutment®, Ivoclar Vivadent, Schaan, Liechtenstein
- Excel 2003®, Microsoft, Redmond, WA, USA

ABBREVIATIONS

Cone beam computed tomography (CBCT); three-dimensional (3D); computer-assisted- design (CAD); intraoral scanner (IOS); scanbody (SB); single crown (SC); partial prosthesis (PP); full arch (FA); polyether-ether-ketone (PEEK); custom measuring aid (CMA); Continuous Scan Strategy (CSS); standard tessellation language (.STL); standard deviations (SD); confidence intervals (CI); coordinate measuring machine (CMM); solid index impression protocol (SIIP).

REFERENCES

- Medina-Sotomayor, P., Pascual-Moscardó, A., Camps, I. Accuracy of four digital scanners according to scanning strategy in complete-arch impressions. *Plos One*. 2018; **13**: e0202916.
- Mangano, F., Gandolfi, A., Luongo, G., Logozzo, S. Intraoral scanners in dentistry: a review of the current literature. *BMC Oral Health*, 2017; **17**: 149.
- Joós-Kovács, G., Vecsei, B., Körmendi, S., Gyarmathy, V.A., Borbély, J., Hermann, P. Trueness of CAD/CAM digitization with a desktop scanner – an *in vitro* study. *BMC Oral Health*, 2019; **19**: 280.
- Menéndez López-Mateos, M.L., Carreño-Carreño, J., Palma, J.C., Alarcón, J.A., Menéndez López-Mateos, C., Menéndez-Núñez, M. Three-dimensional photographic analysis of the face in European adults from southern Spain with normal occlusion: reference anthropometric measurements. *BMC Oral Health*, 2019; **19**: 196.
- Ayuso-Montero, R., Mariano-Hernandez, Y., Khoury-Ribas, L., Rovira-Lastra, B., Willaert, E., Martinez-Gomis, J. Reliability and Validity of T-scan and 3D Intraoral Scanning for Measuring the Occlusal Contact Area. *J Prosthodont.*, 2020; **29**: 19-25.
- Dong, T., Xia, L., Cai, C., Yuan, L., Ye, N., Fang, B. Accuracy of *in vitro* mandibular volumetric measurements from CBCT of different voxel sizes with different segmentation threshold settings. *BMC Oral Health*, 2019; **19**: 206.
- Mangano, C., Luongo, F., Migliario, M., Mortellaro, C., Mangano, F.G. Combining Intraoral Scans, Cone Beam Computed Tomography and Face Scans: The Virtual Patient. *J Craniofac Surg*. 2018; **29**: 2241-2246.
- Hämmerle, C.H., Cordaro, L., van Assche, N., Benic, G.I., Bornstein, M., Gamper, F., Gotfredsen, K., Harris, D., Hürzeler, M., Jacobs, R., Kapos, T., Kohal, R.J., Patzelt, S.B., Sailer, I., Tahmaseb, A., Vercruyssen, M., Wismeijer, D. Digital technologies to support planning, treatment, and fabrication processes and outcome assessments in implant dentistry. Summary and consensus statements. The 4th EAO consensus conference 2015. *Clin Oral Implants Res.*, 2015; **26**: 97-101.
- Lerner, H., Mouhyi, J., Admakin, O., Mangano, F. Artificial intelligence in fixed implant prosthodontics: a retrospective study of 106 implant-supported monolithic zirconia crowns inserted in the posterior jaws of 90 patients. *BMC Oral Health* 2020; **20**: 80
- Javaid, M. and Haleem, A. Current status and applications of additive manufacturing in dentistry: A literature-based review. *J Oral Biol Craniofac Res.*, 2019; **9**: 179-185.
- Aslan, Y.U., Coskun, E., Ozkan, Y., Dard, M. Clinical Evaluation of Three Types of CAD/CAM Inlay/ Onlay Materials After 1-Year Clinical Follow Up. *Eur J Prosthodont Restor Dent.*, 2019; **27**: 131-140.
- Zarone, F., Di Mauro, M.I., Ausiello, P., Ruggiero, G., Sorrentino, R. Current status on lithium disilicate and zirconia: a narrative review. *BMC Oral Health*, 2019; **19**: 134.
- D'haese, J., Ackhurst, J., Wismeijer, D., De Bruyn, H., Tahmaseb, A. Current state of the art of computer-guided implant surgery. *Periodontol 2000.*, 2017; **73**: 121-133.
- Baan, F., de Waard, O., Bruggink, R., Xi, T., Ongkosuwito, E.M., Maal, T.J.J. Virtual setup in orthodontics: planning and evaluation. *Clin Oral Investig.*, 2020; **24**: 2385-2393.
- Joda, T., Bragger, U., Zitzmann, N.U. CAD/CAM implant crowns in a digital workflow: Five-year follow-up of a prospective clinical trial. *Clin Implant Dent Relat Res.*, 2019; **21**: 169-174.
- Grünheid, T., McCarthy, S.D., Larson, B.E. Clinical use of a direct chair-side oral scanner: an assessment of accuracy, time, and patient acceptance. *Am J Orthod Dentofacial Orthop.*, 2014; **146**: 673-682.
- Gallardo, Y.R., Bohner, L., Tortamano, P., Pigozzo, M.N., Laganá, D.C., Sesma, N. Patient outcomes and procedure working time for digital versus conventional impressions: A systematic review. *J Prosthet Dent.*, 2018; **119**: 214-219.
- Kim, R.J., Benic, G.I., Park, J.M. Trueness of digital intraoral impression in reproducing multiple implant position. *Plos One.*, 2019; **14**: e0222070.
- Mangano, F.G., Hauschild, U., Veronesi, G., Imburgia, M., Mangano, C., Admakin, O. Trueness and precision of 5 intraoral scanners in the impressions of single and multiple implants: a comparative *in vitro* study. *BMC Oral Health*, 2019; **19**: 101.
- Sami, T., Goldstein, G., Vafiadis, D., Absher, T. An *in vitro* 3D evaluation of the accuracy of 4 intraoral optical scanners on a 6-implant model. *J Prosthet Dent.*, 2020 Feb 6. Pii: S0022-3913(19)30693-6.
- Giachetti, L., Sarti, C., Cinelli, F., Russo, D.S. Accuracy of Digital Impressions in Fixed Prosthodontics: A Systematic Review of Clinical Studies. *Int J Prosthodont.*, 2020; **33**: 192-201.
- Hack, G., Liberman, L., Vach, K., Tchorz, J.P., Kohal, R.J., Patzelt, S.B.M. Computerized optical impression making of edentulous jaws – An *in vivo* feasibility study. *J Prosthodont Res.* 2020 Feb 13. Pii: S1883-1958(19)30709-1. Doi: 10.1016/j.jpor.2019.12.003. [Epub ahead of print]
- Keul, C. and Güth, J.F. Accuracy of full-arch digital impressions: an *in vitro* and *in vivo* comparison. *Clin Oral Investig.* 2020; **24**: 735-745.
- Wulfman, C., Naveau, A., Rignon-Bret, C. Digital scanning for complete-arch implant-supported restorations: A systematic review. *J Prosthet Dent.*, 2019 Nov 19. Pii: S0022-3913(19)30426-3. Doi: 10.1016/j.prodent.2019.06.014. [Epub ahead of print]
- Goracci, C., Franchi, L., Vichi, A., Ferrari, M. Accuracy, reliability, and efficiency of intraoral scanners for full-arch impressions: a systematic review of the clinical evidence. *Eur J Orthod.*, 2016; **38**: 422-428.
- Ahlholm, P., Sipilä, K., Vallittu, P., Jakonen, M., Kotiranta, U. Digital Versus Conventional Impressions in Fixed Prosthodontics: A Review. *J Prosthodont.*, 2018; **27**: 35-41.
- Rutkunas, V., Larsson, C., Vult von Steyern, P., Mangano, F., Gedrimiene, A. Clinical and laboratory passive fit assessment of implant-supported zirconia restorations fabricated using conventional and digital workflow. *Clin Implant Dent Relat Res.* 2020; **22**: 237-245.
- Abduo, J. and Elseyoufi, M. Accuracy of Intraoral Scanners: A Systematic Review of Influencing Factors. *Eur J Prosthodont Restor Dent.*, 2018; **26**: 101-121.

29. Revilla-León, M., Jiang, P., Sadeghpour, M., Piedra-Cascón, W., Zandinejad, A., Özcan, M., Krishnamurthy, V.R. Intraoral digital scans-Part 1: Influence of ambient scanning light conditions on the accuracy (trueness and precision) of different intraoral scanners. *J Prosthet Dent.* 2019 Dec 18. Pii: S0022-3913(18)30992-2.
30. Motel, C., Kirchner, E., Adler, W., Wichmann, M., Matta, R.E. Impact of Different Scan Bodies and Scan Strategies on the Accuracy of Digital Implant Impressions Assessed with an Intraoral Scanner: An *In Vitro* Study. *J Prosthodont.* 2020; **29**: 309-314
31. Moslemion, M., Payaminia, L., Jalali, H., Alikhasi, M. Do Type and Shape of Scan Bodies Affect Accuracy and Time of Digital Implant Impressions? *Eur J Prosthodont Restor Dent.* 2020; **28**: 18-27
32. Tallarico, M., Schiappa, D., Schipani, F., Cocchi, F., Annucci, M., Xhanari, E. Improved fully digital workflow to rehabilitate edentulous patient with an implant overdenture in 4 appointments: A case report. *J Oral Science Rehabilitation.* 2017; **3**: 38-46.
33. Mangano, F., Mangano, C., Margiani, B., Admakin, O. Combining Intraoral and Face Scans for the Design and Fabrication of Computer-Assisted Design/Computer-Assisted Manufacturing (CAD/CAM) Polyether-Ether-Ketone (PEEK) Implant-Supported Bars for Maxillary Overdentures. *Scanning.* 2019; **2019**: 4274715.
34. Iturrate, M., Eguiraun, H., Solaberrieta, E. Accuracy of digital impressions for implant- supported complete-arch prosthesis, using an auxiliary geometry part- An *in vitro* study. *Clin Oral Implants Res.* 2019; **30**: 1250-1258.
35. Gómez-Polo, M., Ballesteros, J., Perales-Padilla, P., Perales-Pulido, P., Gómez-Polo, C., Ortega, R. Guided implant scanning: A procedure for improving the accuracy of implant- supported complete-arch fixed dental prostheses. *J Prosthet Dent.* 2019 Nov 21. Pii: S0022-3913(19)30614-6.
36. Schmidt, A., Billig, J.W., Schlenz, M.A., Wöstmann, B. A new 3D-method to assess the inter implant dimensions in patients – A pilot study. *J Clin Exp Dent.* 2020; **12**: e187- e192.
37. Mandelli, F., Zaetta, A., Cucchi, A., Mangano, F. Solid index impression protocol: a hybrid workflow for high accuracy and passive fit of full-arch implant-supported restorations. *Int J Comput Dent* 2020; **23**: 161-181.
38. Roig, E., Garza, L.C., Álvarez-Maldonado, N., Maia, P., Costa, S., Roig, M., Espona, J. *In vitro* comparison of the accuracy of four intraoral scanners and three conventional impression methods for two neighboring implants. *PLoS One.* 2020; **15**: e0228266.
39. Mizumoto, R.M., Yilmaz, B. Intraoral scan bodies in implant dentistry: A systematic review. *J Prosthet Dent.* 2018; **120**: 343-352.